

Post-infantile giant cell hepatitis: Histological and immunohistochemical study

S J Johnson, J Mathew, R N M MacSween, M K Bennett, A D Burt

Abstract

Aim—To determine the composition of the inflammatory infiltrate and to check for the presence of cytomegalovirus (CMV) and Epstein-Barr virus (EBV) in nine cases of post-infantile giant cell hepatitis.

Methods—The clinical, serological, and histological features of the nine cases were reviewed. Immunohistochemistry was used on liver biopsy specimens from six cases to: (i) characterise the lymphocytic infiltrate; (ii) assess the monocyte/macrophage response; (iii) detect "activated" perisinusoidal cells; and (iv) detect CMV and EBV antigens. Electron microscopic examination was carried out in two cases.

Results—Four patients had serological features suggestive of autoimmune chronic active hepatitis; in the other five cases the aetiology was obscure. Two patients presented with neurological symptoms. Hepatitis resolved completely in one patient; two patients showed clinical improvement; and one remained stable. Cirrhosis developed in three patients, one of whom proceeded to liver transplantation, and three patients died. Portal inflammation was present in all cases and lymphocytic piecemeal necrosis in eight cases, but intra-acinar inflammation associated with hepatocyte necrosis was observed in only five cases. The inflammatory infiltrate was composed predominantly of T lymphocytes; an increase in monocyte/macrophage cells was also observed. Mallory bodies, often with associated neutrophilic infiltrate, were present in four cases, and bilirubinostasis was a feature in four cases. "Activated" perisinusoidal cells were present, especially in relation to areas of inflammation, necrosis, and fibrosis. There was severe fibrosis or cirrhosis in five cases. Paramyxoviral nucleocapsids were not seen in the two cases examined ultrastructurally.

Conclusions—Post-infantile giant cell hepatitis should be viewed as a heterogeneous clinical and aetiological entity encompassing cases of hepatitis with extensive giant cell hepatocyte transformation.

infantile liver diseases¹ but are only occasionally found in adults. In adults hepatitis with extensive giant cell change²⁻⁸ has been labelled as either "post-infantile giant cell hepatitis" (PIGCH)^{2,5,7} or "syncytial giant cell hepatitis".⁶ Some investigators have suggested that this pattern of hepatitis is a specific entity, possibly of paramyxoviral aetiology,⁶ which has a particularly poor prognosis.² However, autoimmune disease,^{4,7-9} drugs¹⁰⁻¹³ and a variety of other viral infections^{7,9} have also been implicated as causes of giant cell hepatitis.

Methods

Biopsy material was available from nine patients (table 1). Two patients presented initially with neurological symptoms; abnormal liver function tests were subsequently found on routine investigation. There was no known history of transfusion or intravenous drug misuse in any patient. All patients denied alcohol misuse.

Liver function tests at presentation were abnormal in all cases with raised bilirubin, serum transaminases, and alkaline phosphatase activities. A blood smear from case 6 showed atypical mononuclear cells and two patients had slight eosinophilia. Serum autoantibodies were detected in cases 3, 4, 6, 7, 8, and 9, and immunoglobulin concentrations were raised in cases 3, 4, 5, and 9.

Where results of serological investigations were available there was no evidence of recent infection with hepatitis A, B, or C, cytomegalovirus (CMV), Epstein-Barr virus (EBV), syphilis, or toxoplasmosis. In cases 5, 6, and 9 serology for paramyxoviral infection was negative. Case 5 showed transient rises in titres of IgM and IgG to both CMV and EBV which were considered to be part of a polyclonal anamnestic response rather than evidence of recent specific infection; urine culture for CMV and the Paul Bunnell test were negative. Two patients showed serological evidence of recent influenza B (case 4) and *Mycoplasma pneumoniae* (case 9) infections, but there was no temporal relation with the onset of hepatitis in either case.

Follow up information was available in all cases and repeat histology was available in four of these (cases 2, 5, 6, and 7). Cases 1, 2, and 3 died in hepatic failure with evidence of portal hypertension; of this group, case 2 had shown a transient clinical improvement with steroids a few months before death. Case 7 showed no substantial clinical or biochemical response to either a combination of prednisolone and azathioprine, or interferon. She

Division of Pathology,
University of
Newcastle upon Tyne,
Newcastle upon Tyne,
NE1 4LP

S J Johnson
J Mathew
A D Burt

University
Department of
Pathology, Western
Infirmary, Glasgow
R N M MacSween

Department of
Pathology, Freeman
Hospital, Newcastle
upon Tyne
M K Bennett

Correspondence to:
Dr Sarah J Johnson

Accepted for publication
26 April 1994

(J Clin Pathol 1994;47:1022-1027)

Multinucleate hepatocytes are common in biopsy specimens from some neonatal and

Table 1 Clinical details of the nine patients with post-infantile giant cell hepatitis

Case No	Sex/age	Clinical presentation	Previous medical history	Drugs	Initial liver function tests			Positive auto-antibodies	Positive serology	Outcome
					B	ALT	ALP			
1*	F69	Jaundice, abdominal pain	Nil of note	NK	↑	↑	↑	NK	NK	Died. Hashimoto's thyroiditis found at post mortem examination
2*	F46	Jaundice, nausea and vomiting, pale stools, dark urine, for one month	NK	NK	300	640	↑	None	HAV IgG	Died
3*	F41	Jaundice, nausea and vomiting, pale stools, pruritus, for two weeks	Nil of note	None	468	↑	↑	ASMA	None	Died
4*	M12	Jaundice, nausea and vomiting, for four days	Asthma. Recent viral infection	None	109	219	NK	ANF	Influenza B	Clinical improvement
5	F28	Jaundice, pruritus, malaise, for one month	Behçet's disease with colitis	Prednisolone	45	375	570	None	CMV IgM and IgG; EBV IgM and IgG	Clinical recovery and histological resolution
6	F63	Progressive inability to walk and tingling of upper limbs, for one week; abnormal liver function tests	Asthma	None	12	155	1160	Thyroid microsomal antibody	None	Clinical improvement
7	F34	Tiredness, joint pains, dark urine	1980—mild rheumatoid arthritis. Recent travel to Majorca	Norethisterone mefenamic acid	94	AST 865	363	None	None	Developed cirrhosis, transplanted
8	F76	General malaise for a few months; abnormal liver function tests	Depression	Clomipramine	30	441	2500	Initially anti-thyroid cytoplasmic antibody only. Later: ANF and ASMA	None	Clinical improvement
9	M40	Peripheral neuropathy, tiredness for a few months; abnormal liver function tests	Asthma. Recent travel to Europe and USA	Salbutamol beclomethasone	11	488	296	ANF	<i>Mycoplasma pneumoniae</i>	Clinical improvement

*Detailed clinical information is not available for cases 1–4. NK = not known; B = total bilirubin (μmol/l); ALT = alanine amino transferase (IU/l); AST = aspartate transaminase (μmol/l); ALP = alkaline phosphatase (IU/l); ASMA = anti-smooth muscle antibody; ANF = antinuclear factor; HAV = hepatitis A virus; CMV = cytomegalovirus; EBV = Epstein-Barr virus.

developed cirrhosis with oesophageal varices and hypersplenism necessitating splenectomy, and underwent orthotopic liver transplantation in 1991; to date, there has been no recurrence of giant cell hepatitis in the donor liver. Case 6 showed initial clinical improvement but a repeat biopsy specimen showed increased hepatic fibrosis. Case 4 is clinically stable and has responded to steroids. Cases 8 and 9 were also showing clinical improvement at the time of writing. Complete clinical recovery occurred in case 5 and was associated with histological resolution.

On each liver biopsy or necropsy specimen, the following histochemical stains were performed: haematoxylin and eosin, periodic acid

Schiff (PAS), diastase-PAS, picro-Mallory, van Gieson, Shikata's orcein, Perls's Prussian blue stain, and Gordon and Sweets's reticulin.

Material was available for immunohistochemistry from cases 1, 4, 6, 8, 9, the first biopsy specimen from case 5, and the second biopsy specimen from case 7. An indirect immunoperoxidase procedure was performed using the antibodies shown in table 2. Sections treated with normal rabbit or mouse serum in place of primary antibody were used as negative controls; 3,3'-diaminobenzidine was used as chromogen. Mallory bodies were identified both on haematoxylin and eosin staining and labelling with anti-ubiquitin antibody.¹⁴

Features of chronic hepatitis were scored according to the method described by Scheuer¹⁵ as follows: portal/periportal inflammation: 0 = none or minimal; 1 = portal inflammation; 2 = mild piecemeal necrosis; 3 = moderate piecemeal necrosis; 4 = severe piecemeal necrosis. Acinar inflammation: 0 = none; 1 = inflammation but no necrosis; 2 = focal necrosis or acidophil bodies; 3 = severe focal cell damage; 4 = bridging necrosis. Fibrosis/cirrhosis: 0 = none; 1 =

Table 2 Antibodies used for immunohistochemistry

Antibody	Source	Clone	Dilution
Anti-CMV antigen	Dako UK	CCH2	1/50
Anti-EBV antigen	Dako UK	CS1-4	1/50
Anti-ubiquitin	Dako UK	polyclonal	1/1000
Antibody to B lymphocytes	Dako UK	L26 (1,2,3)	1/400
Antibody to T lymphocytes	Dako UK	UCHL1	1/400
Anti-macrophages/monocytes	Dako UK	KP1	1/50
Anti-α-smooth muscle actin	Sigma UK	IA4	1/500

Table 3 Histological characteristics of nine cases of PIGCH

Case No	Biopsy	(a) Giant cells	(b) Mallory bodies	(b) Neutrophils	(b) Bilirubinostasis	(b) Ductular proliferation	Scheuer scoring for features of chronic hepatitis		
							Portal/periportal inflammation	Acinar inflammation	Fibrosis cirrhosis
1		+++	-	P+	C, H+	++	2	3	3
2	first	++	-	P, A+	C, H++	-	3	3	3
	second	++	++	P, A+	C, H++	-	3	3	4
3		++	-	P+	C++	++	3	4	1
4		+++	-	P+	-	+	3	3	4
5	first	+++	-	-	C+	-	0	3	1
	second	++	-	P+	-	-	2	1	2
	third	+	-	-	-	-	0	0	1
6	first	++	+	P, A+	-	++	2	1	2
	second	++	-	-	-	+	2	1	3
7	first	+++	-	P, A+	C+	-	2	3	3
	second	++	++	P, A+	-	+	3	3	4
8		++	+	P, A++	-	-	2	2	2
9		++	+	-	-	-	1	2	0

(a) + <1/3 of parenchymal area; ++ 1/3-2/3 of parenchymal area; +++ >2/3 of parenchymal area; (b) + infrequent; ++ frequent; - absent; P = portal; A = acinar; C = canalicular; H = cytoplasmic (hepatocellular).

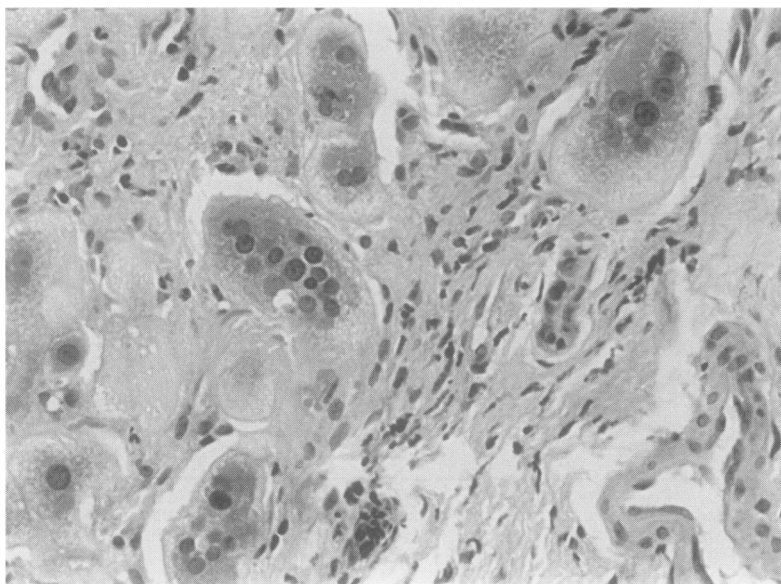


Figure 1 Giant cell transformation of hepatocytes: note multinucleation of many hepatocytes in this field (case 7) (haematoxylin and eosin).

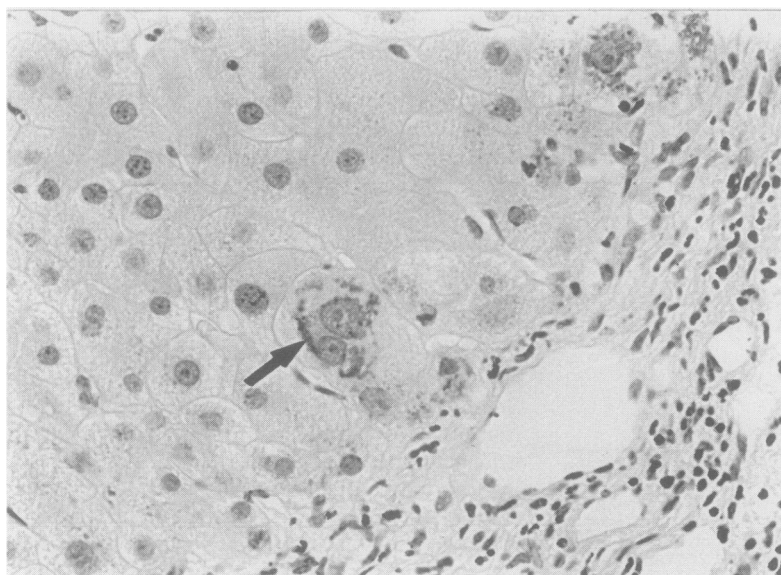


Figure 2 Mallory bodies (arrow) in a binucleate periportal hepatocyte (case 7) (haematoxylin and eosin).

enlarged fibrotic portal tracts; 2 = periportal or portal-portal septa; 3 = fibrosis with architectural distortion; 4 = cirrhosis.

Results

The histological findings in our nine cases are summarised in table 3. All cases showed extensive giant cell transformation of hepatocytes; in most cases the giant cell change affected more than two thirds of the parenchyma (fig 1). Giant cell transformation was most pronounced in periportal and periseptal zones, although in four cases this change was pan-acinar. The giant cells seemed to be limited to liver cell plates and occasionally contained up to 15 centrally located nuclei. Rare single mitotic figures could be found within multinucleate cells. In many cases degenerative cytoplasmic changes were seen involving hepatocytes and giant cells, particularly in periportal areas. Mallory bodies, often within giant cells, were prominent in haematoxylin and eosin stained sections of cases 2 and 7 (fig 2), but could also occasionally be found in ubiquitin labelled sections of cases 6, 8, and 9. Canalicular and cytoplasmic bilirubinostasis, also involving giant cells, was present in four cases (fig 3); some of these showed mild ductular proliferation, although the bile ducts were normal in all cases. Steatosis was not a major feature in any of the biopsy specimens.

An inflammatory infiltrate made up predominantly of mature lymphocytes was present within portal tracts in all cases. Immunohistochemistry showed that this infiltrate was composed almost exclusively of UCHL1 positive T lymphocytes. Occasional neutrophils, eosinophils, and L26 positive B lymphocytes were also seen in portal tracts. In eight cases mild to moderate lymphocytic piecemeal necrosis was observed. Five cases showed a prominent intra-acinar lymphocytic inflammatory infiltrate associated with focal or bridging hepatocyte necrosis. In two cases numerous neutrophils were observed within the acinus; these were often seen around giant cells containing Mallory bodies (fig 4).

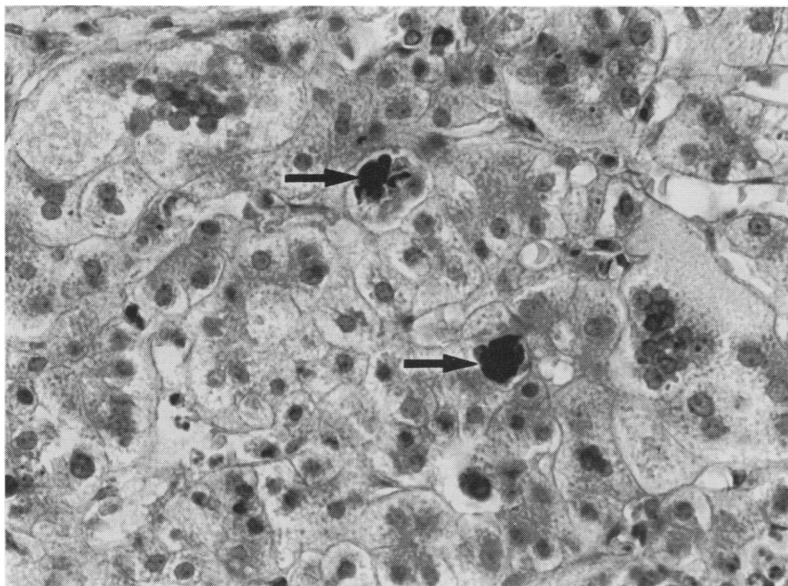


Figure 3 Canalicular bilirubinostasis in a field which also contains multinucleate hepatocytes (arrows = bile plugs) (case 2) (haematoxylin and eosin).

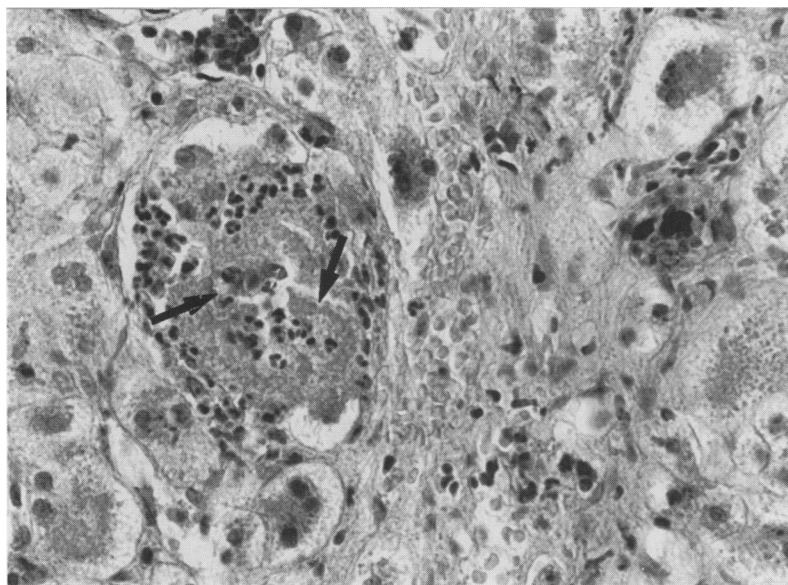


Figure 4 Neutrophils surrounding Mallory bodies (arrows) within a multinucleate hepatocyte (case 2) (haematoxylin and eosin).

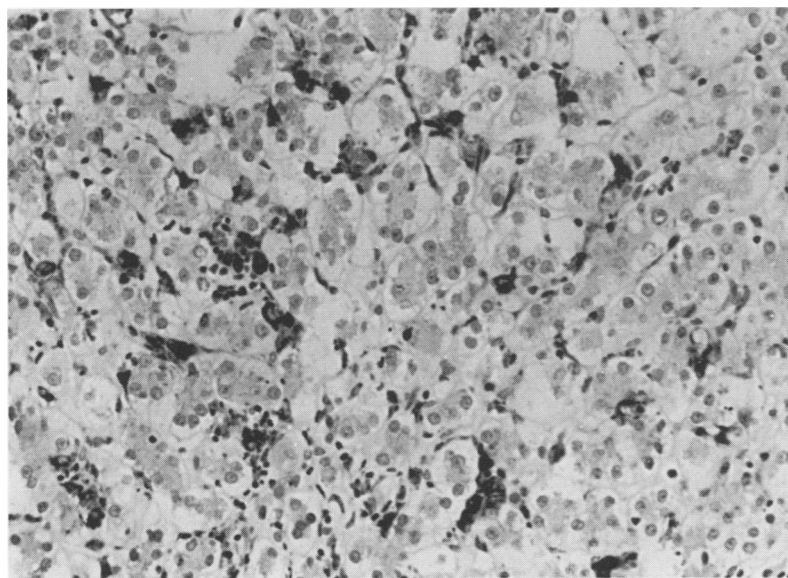


Figure 5 Immunohistochemical labelling with the antibody KP1 showing increased numbers of monocytes and macrophages associated with intra-acinar lymphocytic

Increased numbers of KP1 positive monocytes/macrophages were seen in four cases, particularly in areas of parenchymal necrosis; this increase was most striking in case 1 and the first biopsy specimen from case 5 (fig 5).

Sections labelled with anti- α -smooth muscle actin (α -SMA) antibody showed an increase in "activated" perisinusoidal cell numbers; these cells were found predominantly in areas of intra-acinar inflammation and around foci of piecemeal necrosis and ductular proliferation (fig 6). All cases showed some degree of periportal fibrosis; severe fibrosis was present in cases 1, 2, 6, and 7, and cirrhosis in case 4; progression to cirrhosis was evident in the second biopsy specimens from cases 2 and 7. Perivenular and periportal pericellular fibrosis was present in the initial biopsy specimens from cases 5 and 7. In case 5 follow up biopsy specimens showed resolution of the inflammatory infiltrate and hepatocyte giant cell change, although there was minimal residual periportal fibrosis.

Immunohistochemistry for CMV and EBV antigens was negative in all cases. No viral nucleocapsids were identified in the two cases examined ultrastructurally.

Discussion

The patients described in this study formed a heterogeneous group with respect to their clinical and histological findings, but had in common an unusual histological pattern of hepatitis in which there was extensive giant cell change of hepatocytes that involved at least one third of the parenchymal area.

Giant hepatocytes are characteristically found in several neonatal and infantile liver diseases such as extrahepatic biliary atresia, paucity of intrahepatic bile ducts, some chromosomal and metabolic disorders, and various viral infections.^{1 16 17} By contrast, giant cells are rarely found in adult liver disease. In adults multinucleate hepatocytes have been seen after treatment with drugs such as methotrexate,^{10 13} clometacin,¹¹ and 6-mercaptopurine,¹² and occasional giant cells may be found in some cases of autoimmune chronic active hepatitis and hepatitis C.¹⁸ The combination of hepatitis and extensive giant cell change in adult liver has been referred to as "post-infantile giant cell hepatitis"^{2 5 7} or "syncytial giant cell hepatitis".⁶

Giant cell transformation is a characteristic cytopathic effect of many viruses, especially the paramyxoviruses,¹⁹ and this has led several authors to suggest that PIGCH may be an infective, possibly viral, condition. Phillips *et al*⁶ described a series of patients with "syncytial giant cell hepatitis" in whom ultrastructural examination of the liver biopsy specimens showed cytoplasmic particles resembling paramyxovirus nucleocapsids. Injection of liver homogenate from the index case into two chimpanzees produced a raised paramyxoviral antibody titre without hepatitis in one chimpanzee but no response in the second. These authors therefore suggested that a paramyxoviral infection should be considered in all cases of syncytial giant cell hepatitis.

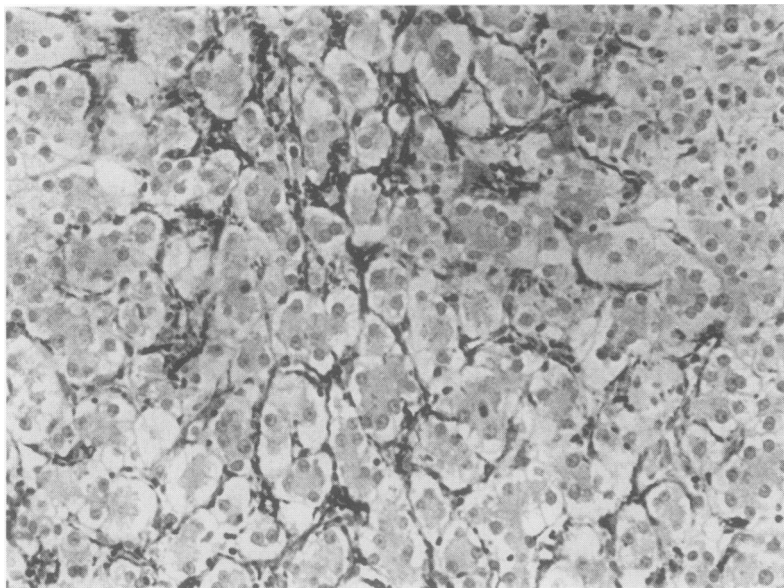


Figure 6 Immunohistochemical labelling with anti- α -SMA antibody showing numerous "activated" perisinusoidal cells in association with intra-acinar inflammation (first biopsy specimen, case 5).

proposed for cases of PIGCH, presuming a common paramyxoviral aetiology.²⁰ This assumption has since been challenged and some cases of PIGCH have been attributed to other viral infections, including hepatitis A, B and C, and EBV.^{7 9 21 22}

Cases 6 and 9 initially presented with neurological symptoms, and abnormal liver function tests were found incidentally on routine screening. In case 9 investigations suggested a mixed axonomic sensorimotor neuropathy but no cause was found; the neurological symptoms partially resolved in parallel with the biochemical improvement in the hepatitis. In case 6 the neurological diagnosis was of a dorsal root ganglionopathy; there was a slight initial improvement in neurological symptoms, but this did not continue and a repeat liver biopsy specimen showed that inflammation and fibrosis had persisted. To our knowledge this is the first documented association of neurological features and giant cell hepatitis.

Serological evidence of recent infection in our patients was found in cases 4 and 9. Raised influenza B antibody titres were seen in case 4 at presentation and in case 9 increased *Mycoplasma pneumoniae* antibody titres were observed during follow up. In both cases liver disease was present before the time of infection and the infections were therefore considered to be incidental rather than contributing to the hepatic processes. Case 5 showed transient rises in titres to CMV and EBV as part of a hypergammaglobulinaemia considered, on clinical grounds, to be a non-specific polyclonal response. No serological evidence of an infective process was found in the other patients.

Features of autoimmunity have been described in some cases of PIGCH.⁷⁻⁹ In our series there was evidence consistent with autoimmune chronic active hepatitis in cases 3, 4, 8, and 9. These patients had anti-smooth

muscle antibody or antinuclear factor. In three cases (3, 4, and 9) this was associated with hypergammaglobulinaemia (immunoglobulin concentrations in case 8 were not known). Histological features of chronic active hepatitis, including portal inflammation with piecemeal necrosis and portal fibrosis, were seen in liver biopsy specimens from these cases. Interestingly, thyroid autoantibodies were positive in cases 6 and 8, and Hashimoto's thyroiditis was noted in case 1 at post mortem examination. Steroid responsiveness was noted in cases 4, 5, and 8, and transiently in case 2.

Portal lymphocytic infiltration was present in all our cases. In addition, lymphocytic piecemeal necrosis was observed in eight cases and a prominent intra-acinar lymphocytic inflammatory infiltrate in five cases. These lymphocytes were mostly T cell in origin. In four cases increased numbers of KP1 positive monocytes/macrophages were also seen, especially in areas of parenchymal necrosis. An increase in the number of α -SMA positive "activated" perisinusoidal cells was also noted, especially in areas of inflammation, necrosis, and fibrosis. Similar alterations in monocyte/macrophage and perisinusoidal cells have been described in other types of chronic liver injury in man,²³⁻²⁵ and our findings are also entirely consistent with the proposed role of these cells in the response to liver injury and the development of hepatic fibrosis.

Mallory bodies were present in four cases, frequently within the giant cells. The presence of numerous Mallory bodies in case 2 was probably related to prolonged cholestasis; the cholestasis was confirmed by the finding of copper associated protein in periportal areas using the orcein stain. Neutrophils were a prominent component of the inflammatory infiltrate in five of our cases; this feature can be explained by the fact that Mallory bodies are chemotactic for neutrophils. Mallory bodies with associated neutrophils are characteristically seen in alcoholic hepatitis and non-alcoholic steatohepatitis (NASH); in our cases clinically relevant steatosis was absent and there was no history of alcohol misuse or any risk factor for NASH.

The reason for the development of multinucleated hepatocytes in PIGCH is unclear but these cells may result either from nuclear division without cytoplasmic division or from union of mononuclear hepatocytes. There is ultrastructural evidence supporting both nuclear division^{3 26} and cell fusion,⁹ and both mechanisms may in fact be involved, either alone or in combination. In infants multinucleation of hepatocytes is considered to be a relatively non-specific response of ontologically less mature hepatocytes to a variety of insults, especially viral infections.¹⁷ In adults giant cell change of hepatocytes probably represents an unusual and idiosyncratic regenerative response to a wide variety of hepatic stimuli, although in some cases a cytopathic effect, possibly virally induced, may also be a factor.

In our opinion the term "post-infantile giant cell hepatitis" should be used for cases of acute and chronic hepatitis in adults with extensive hepatocyte multinucleation. These cases are heterogeneous in terms of their clinical, serological, and histological features. A histological diagnosis is therefore descriptive and does not establish the aetiology in an individual case.

We thank the following for permission to include their patients in this series: Dr R Holden, Monklands Hospital, Lanarkshire; Professor DG Young and Dr KM Goel, Royal Hospital for Sick Children, University of Glasgow; Dr JG Freeman and Dr CS Holgate, Derbyshire City Hospital and Derbyshire Royal Infirmary, Derby; Dr Somasundram and Dr D Henderson, Friarage Hospital, Northallerton; Dr D Hemming, Hexham General Hospital, Hexham, Northumberland; Professor OFW James and Dr MF Bassendine, Freeman Hospital, Newcastle upon Tyne; Dr CO Record, Royal Victoria Infirmary, Newcastle upon Tyne; and Dr P Hudson, Newcastle General Hospital, Newcastle upon Tyne.

We also thank Mrs K Reach for assistance with the immunohistochemistry, Mrs E Tweedy for secretarial assistance, and Mr S Brabazon for the photography.

- 1 Montgomery CK, Ruebner BH. Neonatal hepatocellular giant cell transformation: a review. *Perspect Pediatr Pathol* 1976;3:85-101.
- 2 Thaler H. Post-infantile giant cell hepatitis. *Liver* 1982;2:393-403.
- 3 Richey J, Rogers S, Van Thiel DH, Lester R. Giant multinucleated hepatocytes in an adult with chronic active hepatitis. *Gastroenterology* 1977;73:570-4.
- 4 Thijs JC, Bosma A, Henzen-Logmans SC, Meuwissen SGM. Postinfantile giant cell hepatitis in a patient with multiple autoimmune features. *Am J Gastroenterol* 1985;80:294-7.
- 5 Kumar A, Minuk GY. Postinfantile giant cell hepatitis in association with hyper eosinophilia. *Gastroenterology* 1991;101:1417-19.
- 6 Phillips MJ, Blendis LM, Poucell S, Patterson J, Petric M, Roberts E, et al. Syncytial giant-cell hepatitis: sporadic hepatitis with distinctive pathological features, a severe clinical course, and paramyxoviral features. *N Engl J Med* 1991;324:455-60.
- 7 Lau JYN, Koukoulis G, Mieli-Vergani G, Portmann BC, Williams R. Syncytial giant-cell hepatitis—a specific disease entity? *J Hepatol* 1992;15:216-9.
- 8 Devaney K, Goodman ZD, Ishak KG. Postinfantile giant-cell transformation in hepatitis. *Hepatology* 1992;16:327-33.
- 9 Dienes HP, Protzer U, Gerken G, Bianchi L, Schirmacher P, Klinge O. Pathogenesis and clinical relevance of post-infantile giant cell hepatitis (PIGCH). *Hepatology* 1993;18:175A.
- 10 Dubin HV, Harrell ER. Liver disease associated with methotrexate treatment of psoriatic patients. *Arch Dermatol* 1970;102:498-503.
- 11 Pessayre D, Degos F, Feldmann G, Degott C, Bernuau J, Benhamou J-P. Chronic active hepatitis and giant multinucleated hepatocytes in adults treated with clometacin. *Digestion* 1981;22:66-72.
- 12 McIlvanie SK, MacCarthy JD. Hepatitis in association with prolonged 6-mercaptopurine therapy. *Blood* 1959;14:80-90.
- 13 Coe RO, Bull FE. Cirrhosis associated with methotrexate treatment of psoriasis. *JAMA* 1968;206:1515-20.
- 14 Timiakos DG, Harrison D, Burt AD. Detection of Mallory bodies in human liver biopsies by immunolocalisation of ubiquitin: comparison with other histochemical and immunohistochemical methods. *Hepatology* 1992;16:601.
- 15 Scheuer PJ. Classification of chronic viral hepatitis: a need for reassessment. *J Hepatol* 1991;13:372-4.
- 16 Witzleben CL, Marshall GS, Wenner W, Piccoli DA, Barbour SD. HIV as a cause of giant cell hepatitis. *Hum Pathol* 1988;19:603-5.
- 17 Aterman K. Neonatal hepatitis and its relation to viral hepatitis of mother—a review of the problem. *Am J Dis Child* 1963;105:395-416.
- 18 Bach N, Thung SN, Schnaffner F. The histological features of chronic hepatitis C and autoimmune chronic hepatitis: a comparative analysis. *Hepatology* 1992;15:572-7.
- 19 Enders JF, McCarthy K, Mitus A, Cheatham WJ. Isolation of measles virus at autopsy in cases of giant-cell pneumonia without rash. *N Engl J Med* 1959;261:875-81.
- 20 Anonymous. Hepatitis G? [Editorial.] *Lancet* 1991;337:1070.
- 21 Koff RS. Acute and chronic giant cell hepatitis: a paramyxovirus infection? *Gastroenterology* 1991;101:863-4.
- 22 Yunis E, Agostini R. Syncytial giant cell hepatitis. *N Engl J Med* 1992;327:130-1.
- 23 Mathew J, Burt AD. Cellular mechanisms of fibrogenesis in genetic haemochromatosis. In: Knook DL, Wisse E, eds. *Cells of the hepatic sinusoid*. Vol. 4. Rijswijk, Netherlands: Kupffer Cell Foundation, 1993;274-6.
- 24 Mathew J, Hines J, Toole K, Johnson SJ, James OFW, Burt AD. Quantitative analysis of macrophages and perisinusoidal cells in primary biliary cirrhosis. *Histopathology* 1994;25:65-70.
- 25 Schmitt-Gräff A, Krüger S, Bocharf F, Gabbiani G, Denk H. Modulation of alpha smooth muscle actin and desmin expression in perisinusoidal cells of normal and diseased human livers. *Am J Pathol* 1991;138:1233-42.
- 26 Elsner B. Ultrastructural studies in giant cell transformation of the liver. *Medicina* 1973;33:248-54.