

A RARE PRESENILE DEMENTIA ASSOCIATED WITH CORTICAL BLINDNESS (HEIDENHAIN'S SYNDROME)

BY

A. MEYER, DENIS LEIGH, and C. E. BAGG

From the Department of Neuropathology, Institute of Psychiatry, London, and St. Ebba's Hospital, Epsom

In 1929 Heidenhain reported three cases of what he called a peculiar form of presenile disease. In his first case the patient (Eckert), a man aged 55, after an attack of influenza, began to suffer from headaches, sleeplessness, and fleeting limb pains. His vision deteriorated rapidly and he became demented. Other signs of the disorder included dysarthria, ataxia, athetotic movements, and a rigidity of all four limbs without signs of pyramidal disorder. He became blind, but the discs and fundi showed no abnormality. He died four months after the onset of his symptoms. The cerebrospinal fluid had been normal throughout the illness, the Wassermann reaction in both blood and spinal fluid being negative. In his family, one brother had died from a cerebral disorder following pneumonia, but no further details were known.

At necropsy there was severe atheroma of the coronary arteries and brown atrophy of the heart. The brain weighed 1,470 g., the basal arteries were atheromatous, and the leptomeninges were thickened over the frontal convexities and around the Sylvian fissures. There was more than the usual amount of cerebrospinal fluid in the subarachnoid spaces, but there was no conspicuous convolitional atrophy.

The histological investigation of the brain showed changes in the cerebral cortex which were most marked in the occipital lobe, less severe in the parietal cortex, the posterior insula, and the first temporal convolution, and practically absent in the precentral and frontal regions. The Betz cells were normal. The changes in the occipital lobe (including the calcarine region) consisted of shrinkage and pigment atrophy, particularly of the small nerve cells in layers 4, 2, 6 (in that order), a disturbed cytoarchitecture and marked proliferation of protoplasmic and fibrous astrocytes. Some nerve cells were swollen, others gave an appearance resembling Nissl's severe cell change. There was no demyelination. In Bielschowsky preparations senile plaques

and neurofibrillary tangles were absent. The blood vessels were healthy and there was no inflammation. The white matter was normal except for a small amount of subcortical glial proliferation. Within the striate body the large nerve cells were unaffected while the small cells showed some non-specific degeneration. The nerve cells of the globus pallidus, the grey centres in the mid-brain, pons, medulla, and cerebellum were normal.

In his second case (Bleder), a man of 53 developed a rapidly progressive dementia with echolalia and perseveration, deterioration of vision with photophobia, vertigo, intention tremor, grasp reflex, athetosis of the upper limbs, and in the later stages severe generalized rigidity without signs of any pyramidal tract lesion. Blood and cerebrospinal fluid were normal. He became blind and died four months after the onset of the disease from terminal septicaemia and cardiac failure. The discs and fundi were normal throughout his illness. In the family history one brother had committed suicide in the course of an affective mental disorder, and the patient's daughter was reputed to have died from epidemic encephalitis.

Necropsy showed a brown atrophy of the heart, old healed pulmonary tuberculosis, and severe ulceration of the skin covering the anterior surface of both knees. The brain weighed 1,290 g. No macroscopic change was seen.

Histological investigation revealed changes similar to those found in the previous case, but of greater severity. The occipital lobe, including the calcarine region, was again the most severely affected portion of the brain. All cortical layers were involved, particularly the fourth layer. A finely meshed status spongiosus was present, chiefly affecting the upper layers of the occipital cortex. The glial reaction was similar to that in the first case. The parietal region, and in contrast to Case 1, the precentral and frontal regions were also involved. The temporal lobe was less affected, the cornu Ammonis being quite normal.

There was no appreciable change in the blood vessels, nor was there any conspicuous demyelination of the cerebral cortex and white matter. The small nerve cells of the striate body were more severely affected than in Case 1, and there was here a marked proliferation of fibre-producing astrocytes. The globus pallidus and all other diencephalic, mesencephalic, and lower centres were normal.

His third case (Jacob B.) was a man of 54 who had suffered five years previously from pains in the arms and legs and some subjective sense of weakness. At the age of 54 he developed a sensory loss in the left hand, athetosis of the left upper limb and hyper-tonicity of both upper and lower limbs, particularly on the left side. The deep reflexes were increased, particularly on the left. There was no visual disturbance. He became rapidly demented during the last few months of his illness, developed epileptic convulsions, and died six years after the onset of his symptoms from terminal septicaemia following a crop of boils.

Necropsy showed brown atrophy of the heart, early sclerosis of the aorta, and brown atrophy of the liver. The brain weighed 1,270 g. There was no arteriosclerosis of the large basal arteries, and no macroscopic abnormalities of the brain itself.

The histological changes were very similar to those of Case 2 except that they included the whole of the cerebral cortex, as well as the calcarine region, and a finely meshed status spongiosus was much more frequently found in all cortical regions. Again the internal granular layer was most severely affected, but nerve cell changes, astrocytic proliferation, and status spongiosus were found in all layers, obscuring the cytoarchitecture.

The nerve cell changes were similar to those described in the first two cases, but swelling resembling to some extent primary irritation was more frequent. In the deeper layers of the cortex, and in the subcortical white matter, gemistocytic astrocytes were frequently found. Demyelination was surprisingly inconspicuous and confined to the areas of spongioid degeneration. The blood vessels were normal; there was no appreciable inflammation, and no senile plaques or neurofibrillary tangles. In the striate body the small nerve cells were chiefly affected but the large nerve cells occasionally showed changes reminiscent of retrograde degeneration.

These three cases have been regarded by Heidenhain and many other subsequent writers as closely related to the Creutzfeld-Jakob syndrome. However, no similar changes have since been reported in the literature, although the number of published cases of the Creutzfeld-Jakob syndrome now totals 31. For this reason the following case, one of seven

examples of the Creutzfeld-Jakob syndrome investigated in this laboratory, appears to warrant publication.

Case Report

G. H., a married man aged 38, was admitted to St. Ebba's Hospital on January 29, 1949. About October, 1948, he became forgetful, experienced difficulty in concentrating, and found he could not cope with his work. He became irritable, suffered from headaches, and his vision began to fail. There was no family history of nervous or mental disorder. The patient was stable, married, with two children, and had worked for 20 years at the General Post Office as a sorter. There was no history of previous illness, except that he had sustained severe burns of the legs following the explosion of an incendiary bomb during the war.

On examination he was confused, disorientated, and suffering from a memory defect. There was no abnormality in the cranial nerves. All tendon reflexes were exaggerated but the plantar responses were flexor. A radiograph of the skull was normal. The cerebrospinal fluid showed normal pressure, cytology, and chemistry. The Wassermann reaction was negative in both blood and C.S.F. and the blood urea was 44 mg. per 100 ml. In February, 1949, it was noted that the discs were pale but not atrophic, and that the tendon reflexes were increased on the left side. There was a "gross ataxia". He was extremely difficult to examine owing to a rapidly developing dementia, but it was thought that he might have a right homonymous hemianopia. His condition deteriorated rapidly and he died six months after the onset of symptoms.

Necropsy.—A necropsy was performed 24 hours after death. The body was that of an emaciated man with a bed sore over the right buttock. There was no evidence of disease in any system other than the nervous system. The brain weighed 1,200 g. The meninges were normal in appearance as were the blood vessels of the brain. There was a conspicuous widening of the sulci over the convexity of both frontal lobes. Atrophy of the convolutions was also seen posteriorly in the post-central gyrus, dorsal parietal lobule and most marked in both occipital lobes, particularly in the calcarine region. No other macroscopic abnormality was detected.

Histological investigation of the brain showed that the changes were predominantly cortical. All cortical regions were affected, but the most severe change was seen bilaterally in the occipital lobes, particularly in the calcarine regions and their vicinity. Here the convolutions were much reduced in size (Fig. 1). The texture was loosened giving rise in many places to a finely meshed status spongiosus situated particularly, but not exclusively, in the upper layers (Fig. 2). This spongy state appeared to be derived from enlarged perivascular and pericellular spaces. In both the spongioid tissue and the areas of more solid atrophy the cytoarchitecture was grossly disturbed. Most nerve cells had disappeared, the remaining ones showing severe shrinkage and—with fat stains—pigment atrophy. There was an enormous

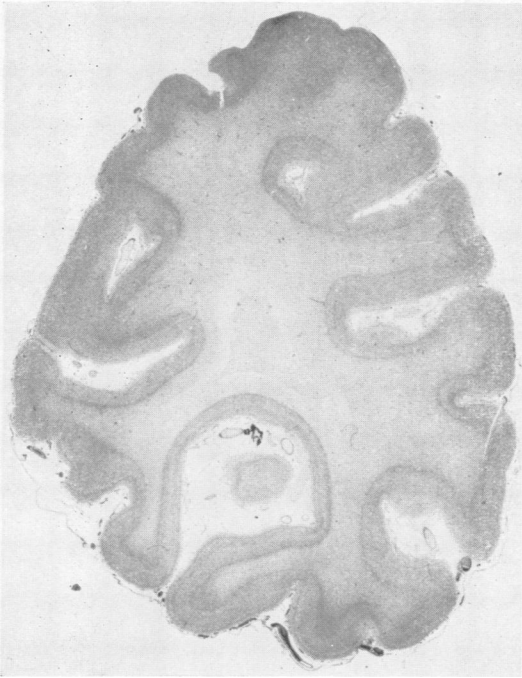


FIG. 1.—Occipital lobe, Nissl stain, showing atrophy particularly marked on the mesial side, including the calcarine region. $\times 2.4$.

proliferation of microglia, oligodendroglia, and astrocytes, many of the latter of the gemistocytic type (Fig. 3). Compound granular corpuscles were only rarely encountered. The neuroglial proliferation was well demonstrated with Holzer and Hortege's silver carbonate stains (Figs. 4 and 5).

In view of the severity of the lesion in the occipital lobe it is surprising that the stripe of Gennari in the calcarine region was still recognizable in myelin preparations, although staining somewhat paler than is usual. There was considerable demyelination in the occipital cortex, corresponding in severity to that of the other changes. In those parts most severely affected most of the radial and horizontal fibres had either completely disappeared or only remained as fragments. A similar degree of damage to the axis cylinders was noticed in Bielschowsky preparations. With the Herxheimer method fine, brilliantly staining granules would be seen in the remaining nerve cells, microglial and adventitial histocytes, but the amount

was not very large and it must be assumed that most of the lipoidal break-down products had been already removed. There was only slight demyelination in the occipital white matter.

The lesions in other areas of the cerebral cortex were less severe. They were of similar degree in the frontal, central (Fig. 6), and temporal convolutions. In Nissl-stained sections the architecture appeared disordered. With higher magnification a diffuse reduction of nerve cells of moderate degree was noticed together with a proliferation of astrocytes and of microglial cells. The Betz cells were not greatly reduced in number, but they appeared shrunken and often contained an excess of lipofuscin. The proliferation of the fibrous glia was, however, moderate in comparison with that seen and illustrated in the occipital lobe. Heidenhain and Bielschowsky preparations revealed a general reduction of fibres in the cortex, but of far less severity than that encountered in the occipital region.

Senile plaques and Alzheimer's neurofibril change were not found. Inflammatory changes were absent, and the iron reaction was negative.

In van Gieson-stained sections the blood vessels throughout showed an adventitial fibrosis, but nowhere was there an appreciable degeneration of the endothelial layer, the internal elastic lamina, or the muscular coat.

No significant change was found in the cerebral white matter except for a slight demyelination in the occipital lobe (mentioned above) and frequent distension of perivascular spaces with terminal oedema around fibrosed blood vessels. The basal ganglia, the brain-

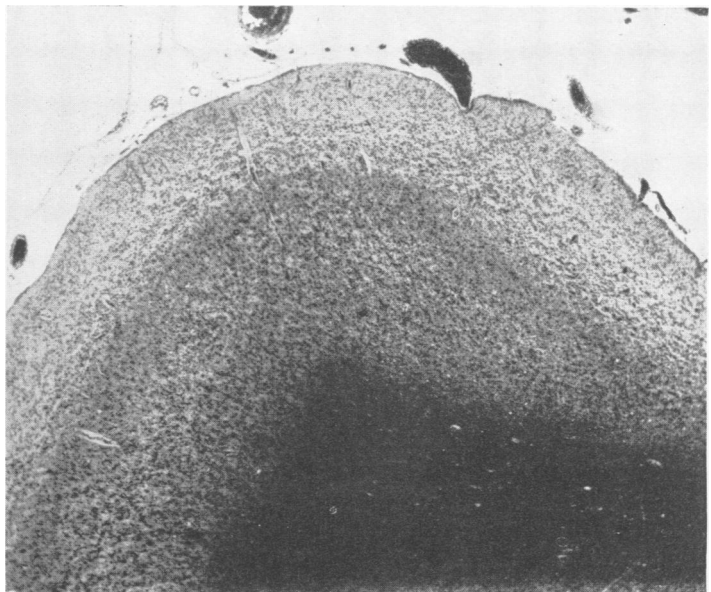


FIG. 2.—Occipital lobe, P.A.H. stain, showing finely meshed status spongiosus particularly in the upper layers. $\times 26$.

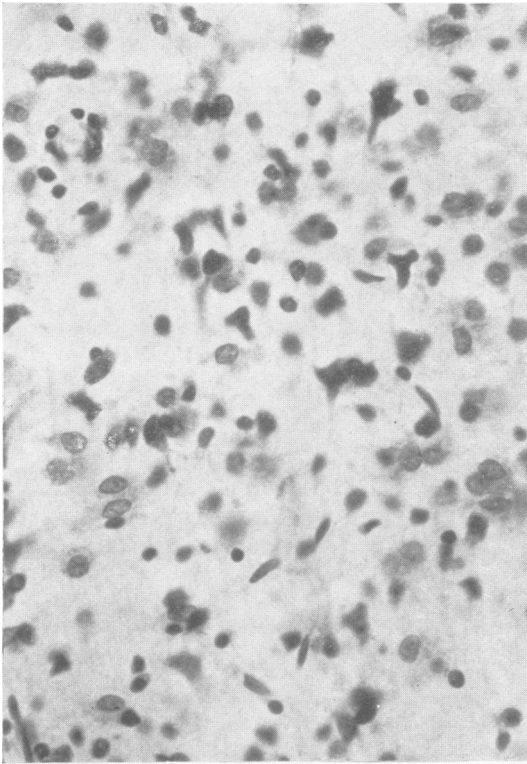


FIG. 3.—Occipital lobe (calcarine region), Nissl stain. Note almost complete disturbance of architecture, severe loss of nerve cells, shrinkage of remaining nerve cells, heavy macroglial (partly gemistocytic) and microglial proliferation. $\times 500$.

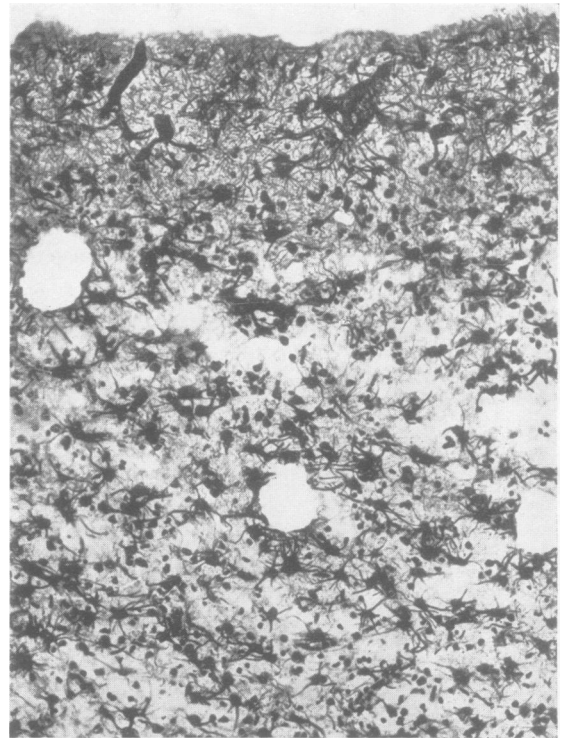


FIG. 5.—Occipital lobe (calcarine region), silver carbonate stain for astrocytes: heavy astrocytic proliferation throughout the upper layers of the cortex. There was less heavy astrocytic proliferation in the deeper layers. $\times 150$.

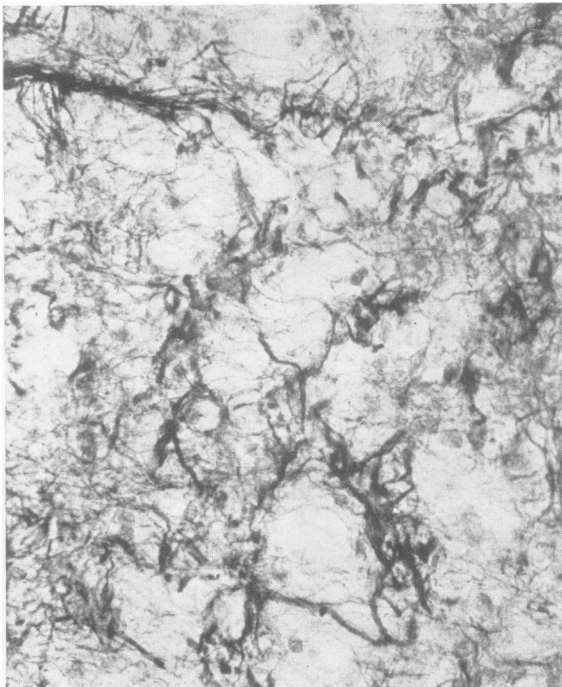


FIG. 4.—Occipital lobe, calcarine region, Holzer stain. Note the holes of the spongiose state surrounded by glial fibres. $\times 390$.

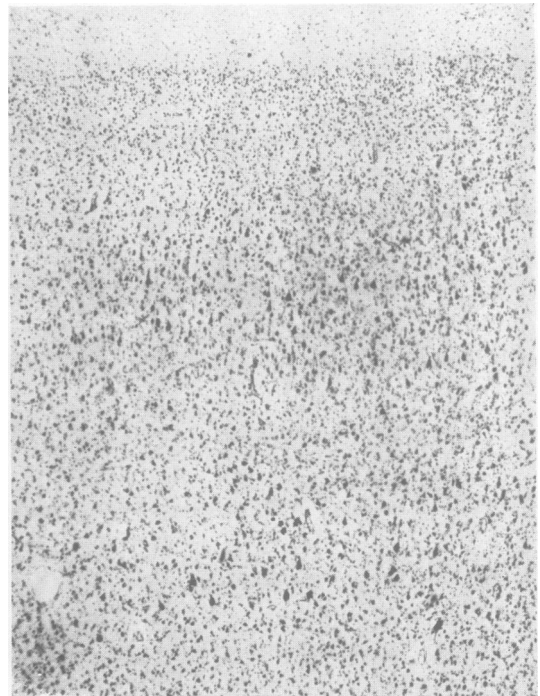

FIG. 6.—Precentral region, Nissl stain, showing disturbance of cyto-architecture through loss of nerve cells in the upper layers and glial proliferation. The Betz cells are shrunken. $\times 35$.

stem, cerebellum, and spinal cord did not show appreciable pathological change.

Discussion

The similarity of our case to Heidenhain's three patients, particularly his patients Eckert and Bleder, needs no further emphasis, for in all three (Eckert, Bleder, our case) a rapidly fatal illness was characterized by blindness and progressive dementia. Although minor differences were present, for instance the absence of athetotic movements in our patient, and the absence of a status spongiosus in the case of Eckert, nevertheless, the general pattern is strikingly similar. In Heidenhain's third case (Jacob B.) the clinical course was much longer and the emphasis on the occipital lobe was less, and did not result in a cortical blindness.

As regards differential diagnosis, gross vascular disease such as arteriosclerosis, aneurysm, or atrophy due to thrombosis of the posterior cerebral artery, could be excluded both in Heidenhain's cases and in our own. Alzheimer's presenile disease is excluded by the absence of senile plaques and of neurofibrillary tangles. The diagnosis of Pick's lobar atrophy is controverted, apart from differences of histological detail, by the localization of the atrophy in the occipital lobes which has never been described in this disease (von Bagh, 1941; Peters, 1951). Lissauer's form of general paresis and hepato-lenticular degeneration, in both of which a status spongiosus is found, were excluded by the absence of the characteristic inflammatory change in the one, and of Alzheimer's glial cells in the other.

As has been mentioned, Heidenhain considered his cases to be closely related to the Creutzfeld-Jakob syndrome and this view has been accepted by most subsequent writers. It is not our wish to discuss here the aetiological problems of the Creutzfeld-Jakob syndrome; this will be done when our material is published in full. Generally speaking the aetiology is still obscure despite the various suggestions which have been put forward. It is even questionable whether the syndrome is more than a convenient dumping ground for otherwise unclassifiable dementias with interesting cross relations to certain systemic degenerations (McMenemey, 1941). If this is the case, the syndrome will sooner or later be reshaped. However, a satisfactory regrouping can only be based upon a larger number of cases than is at present available. It is possible at this stage to distinguish several sub-groups from the point of view of

clinical diagnosis. There is first a group with a tendency for degeneration to occur in certain motor centres, at cortical, sub-cortical, bulbar, and spinal levels, clinically presenting as a combination of dementia and amyotrophy, with or without the admixture of extra-pyramidal symptoms. These are the cases for which Wilson (1940) has suggested the term cortico-striato-spinal degeneration. Cases with this symptomatology represent about one-third of the total published material, as well as of our personal material.

The remainder of the published cases of the Creutzfeld-Jakob syndrome consist of conditions in which widespread involvement of the cerebral cortex, often combined with lesions of the basal ganglia, lead to clinical manifestations of which dementia, and pyramidal and extra-pyramidal signs predominate. In most of these cases a clinical diagnosis during life will prove to be impossible since other presenile conditions cannot be satisfactorily excluded.

The group formed by Heidenhain's Cases 1 and 2 and our present case, however, is an exception. With their rapid clinical course, the emphasis of the cortical changes on the occipital lobe, instead of in the motor cortex and with no prominent affection of the basal ganglia, they form a rather distinct group, progressive dementia and blindness being the presenting clinical signs. The rarity of this condition will most likely preclude an accurate clinical diagnosis.

Summary

A case is described which was characterized clinically by a rapid course, cortical blindness, and dementia. Pathologically there was a diffuse cortical degeneration with particular emphasis on the occipital cortex, in which there was a spongioid state.

The condition closely resembles that previously described by Heidenhain, which has been classified as belonging to the Creutzfeld-Jakob syndrome.

In order to distinguish Heidenhain's and our cases from other varieties of the Creutzfeld-Jakob group, the name "Heidenhain's syndrome" is suggested.

REFERENCES

- Bagh, K. von (1941). *Arch. Psychiat. Nervenkr.*, 114, 68.
 Heidenhain, A. (1929). *Z. ges. Neurol. Psychiat.*, 118, 49.
 McMenemey, W. H. (1941). *J. Neurol. Psychiat.*, 4, 48.
 Peters, G. (1951). *Spezielle Pathologie der Krankheiten des zentralen und peripheren Nervensystems*. Thieme, Stuttgart.
 Wilson, S. A. Kinnier (1940). *Neurology*. Arnold, London.