

# Three-dimensional evaluation of tooth movement in Class II malocclusions treated without extraction by orthodontic mini-implant anchorage

Dler Ali<sup>a</sup>  
Hnd Mohammed<sup>b</sup>  
Seung-Hwan Koo<sup>a</sup>  
Kyung-Hwa Kang<sup>a</sup>  
Sang-Cheol Kim<sup>a</sup>

<sup>a</sup>Department of Orthodontics, School of Dentistry, Wonkwang University, Iksan, Korea

<sup>b</sup>Department of Prosthodontics, School of Dentistry, Wonkwang University, Iksan, Korea

**Objective:** The aim of this study was to analyze tooth movement and arch width changes in maxillary dentition following nonextraction treatment with orthodontic mini-implant (OMI) anchorage in Class II division 1 malocclusions. **Methods:** Seventeen adult patients diagnosed with Angle's Class II division 1 malocclusion were treated by nonextraction with OMIs as anchorage for distalization of whole maxillary dentition. Three-dimensional virtual maxillary models were superimposed with the best-fit method at the pretreatment and post-treatment stages. Linear, angular, and arch width variables were measured using Rapidform 2006 software, and analyzed by the paired *t*-test. **Results:** All maxillary teeth showed statistically significant movement posteriorly ( $p < 0.05$ ). There were no significant changes in the vertical position of the maxillary teeth, except that the second molars were extruded (0.86 mm,  $p < 0.01$ ). The maxillary first and second molars were rotated distal-in ( $4.5^\circ$ ,  $p < 0.001$ ;  $3.0^\circ$ ,  $p < 0.05$ , respectively). The intersecond molar width increased slightly (0.1 mm,  $p > 0.05$ ) and the intercanine, interfirst premolar, intersecond premolar, and interfirst molar widths increased significantly (2.2 mm,  $p < 0.01$ ; 2.2 mm,  $p < 0.05$ ; 1.9 mm,  $p < 0.01$ ; 2.0 mm,  $p < 0.01$ ; respectively). **Conclusions:** Nonextraction treatment with OMI anchorage for Class II division 1 malocclusions could retract the whole maxillary dentition to achieve a Class I canine and molar relationship without a change in the vertical position of the teeth; however, the second molars were significantly extruded. Simultaneously, the maxillary arch was shown to be expanded with distal-in rotation of the molars.  
[Korean J Orthod 2016;46(5):280-289]

**Key words:** Tooth movement, Class II division 1 malocclusion, Nonextraction treatment, Mini-implant anchorage

Received October 15, 2015; Revised December 23, 2015; Accepted January 27, 2016.

**Corresponding author:** Sang-Cheol Kim.

Professor, Department of Orthodontics, School of Dentistry, Wonkwang University, 460 Iksandae-ro, Iksan 54538, Korea.

Tel +82-63-859-2961 e-mail sangkim@wku.ac.kr

\*This work was supported by Wonkwang University in 2014.

The authors report no commercial, proprietary, or financial interest in the products or companies described in this article.

© 2016 The Korean Association of Orthodontists.

This is an Open Access article distributed under the terms of the Creative Commons Attribution Non-Commercial License (<http://creativecommons.org/licenses/by-nc/4.0>) which permits unrestricted non-commercial use, distribution, and reproduction in any medium, provided the original work is properly cited.

## INTRODUCTION

During the past decade, nonextraction treatment has become increasingly popular for correction of Class II malocclusions.<sup>1</sup> Nonextraction treatment of these cases frequently requires posterior movement of the maxillary dentition in order to achieve a Class I molar and canine relationship. For a number of years, headgear has been a conventional treatment to distalize the molars or the entire maxillary dentition for Class II malocclusions; however, it depends on patient compliance and is not esthetically acceptable, which can compromise the results.<sup>2,3</sup> Therefore, several intraoral appliances have been proposed as alternatives to the compliance-dependent headgear for distalizing the maxillary molars in Class II patients without the need for cooperation on the part of the patient; these include pendulum,<sup>4</sup> push-coil,<sup>5</sup> magnetic,<sup>6</sup> superelastic nickel-titanium wire,<sup>7</sup> distal jet,<sup>8</sup> and molar slider<sup>9</sup> appliances. All these techniques effectively distalize the maxillary molars, but may cause loss of anchorage characterized by mesial movement of the premolars and protrusion of the maxillary incisors.<sup>10,11</sup>

Orthodontic mini-implants (OMIs), known as temporary anchorage devices, were introduced in clinical orthodontics to prevent loss of anchorage and could have specific advantages for nonextraction treatment by providing absolute anchorage.<sup>12-14</sup> Their ability to retract the whole dentition can minimize any adverse reciprocal movement and maximize the efficiency of treatment.<sup>1,15</sup>

Superimposition of data before and after orthodontic treatment is an important analytical tool in both clinical and scientific research. Superimposition of serial cephalometric radiographs has been the method most widely used to evaluate tooth movement. However, there are some limitations to this technique, with drawbacks that include difficulty in evaluation of three-dimensional (3D) tooth movement and identification of some landmarks.<sup>16</sup>

Use of 3D digital models has been increasing in orthodontics because of the development of 3D digital laser scanners and software that can transform scanned data into images.<sup>17-19</sup> Analysis of 3D virtual models by superimposition of data before and after treatment can offer more comprehensive information on orthodontic tooth movement compared with conventional two-dimensional cephalometric analysis.<sup>20-22</sup>

A few studies have evaluated orthodontic tooth movement by 3D superimposition of before and after virtual models. Cho et al.<sup>22</sup> investigated the 3D changes in maxillary dentition in Class I bialveolar protrusion treated by extraction of the four first premolars. Moreover, Park et al.<sup>23</sup> compared the effects of conventional anchorage versus OMI anchorage on 3D tooth movement and arch-dimension changes in patients with Class II division 1

malocclusions with extraction of the maxillary first and mandibular second premolars. However, there have been no reports on 3D analysis of tooth movement or arch dimensional changes in nonextraction treatment of Class II division 1 malocclusions.

The purpose of this study was to evaluate 3D tooth movement (anteroposterior, vertical, rotation of molars) and change in arch width in the maxillary dentition of patients with Class II division 1 malocclusions undergoing nonextraction treatment with OMIs using 3D superimposition of before and after virtual maxillary models.

## MATERIALS AND METHODS

### Sample selection

The study sample consisted of 17 Korean adults (six males, 11 females; average age at pretreatment  $26.04 \pm 10.8$  years) with Class II division 1 malocclusion who visited the Department of Orthodontics, Wonkwang University Dental Hospital. The study was approved by the institutional review board at the Dental Hospital of Wonkwang University (WKDIRB201508-02).

Patterns of orthodontic tooth movement can vary according to the degree of the malocclusion and the treatment procedure used, so the following inclusion criteria were applied.

- 1) A minimum age for treatment of 17 years in male patients and 14 years in female patients to minimize the residual growth effect.
- 2) All erupted third molars were extracted at the start of or during treatment in patients with full permanent dentition.
- 3) All cases had Angle's Class II division 1 malocclusion, Class II canine and molar relationships, crowding in the maxillary arch ( $2.84 \pm 2.79$  mm), not less than 5 mm in overjet, and a tapered or ovoid symmetric dental arch form.
- 4) MBT brackets (0.022 inches [in]; 3M Unitek, Monrovia, CA, USA) and 0.016 × 0.022-in stainless steel wires were used with no curve of Spee given to working wire.
- 5) OMIs were used for distalization of the maxillary dentition in patients receiving orthodontic treatment without extraction.

OMIs (6 mm in length, 1.6 mm in diameter; Dual Top<sup>®</sup> Anchor System, Jeil Med. Co., Seoul, Korea) were inserted at the buccal attached gingiva between the maxillary second premolar and first molar on both sides. Distalizing forces of approximately 200 g were applied from the OMIs to the posted hooks between the maxillary canines and lateral incisors by using elastic chains or nickel-titanium closing coil springs. The average retraction period was  $8.2 \pm 2.0$  months. At the end of treatment, all cases were considered to be well treated clinically, i.e., displaying a

Class I canine and molar relationship, normal overjet and overbite, and well-aligned and interdigitated arches.

**Superimposition of maxillary dental models**

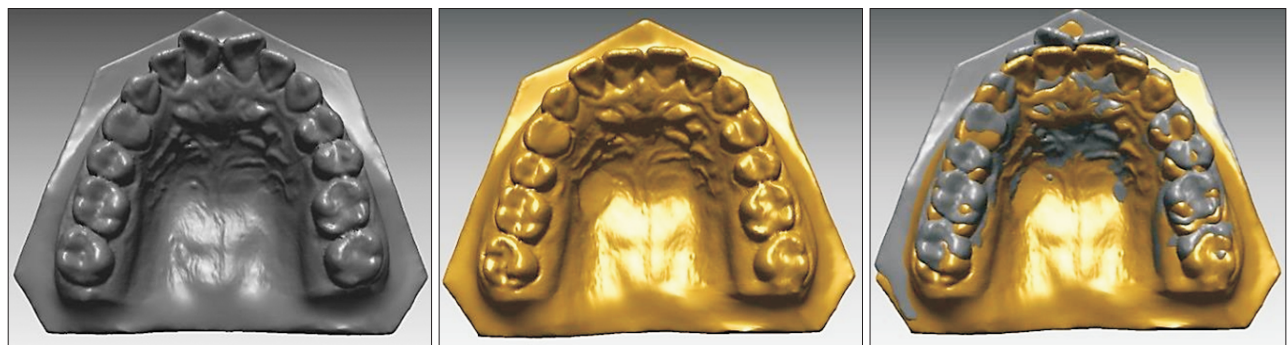Three-dimensional virtual maxillary models were acquired at pretreatment (T0) and post-treatment (T1) using a 3D laser scanning system and 3Txx software (Orapix Co., Ltd., Seoul, Korea). The 3D laser scanner constructed 3D virtual models from maxillary dental casts with an accuracy of  $\pm 0.02$  mm/10 mm and a resolution of  $1,024 \times 768$  pixels. The digital files for the virtual models were then transformed into a specific file type for further measurement using Rapidform 2006 software (INUS Technology, Seoul, Korea).

The T0 and T1 3D virtual models were superimposed using the palatal rugae and the midline raphe as reference. It has been shown previously that the medial palatal rugae, in particular the third medial rugae, can be used as a reference landmark for assessment of tooth movement.<sup>24-26</sup> The zone of the palate along the

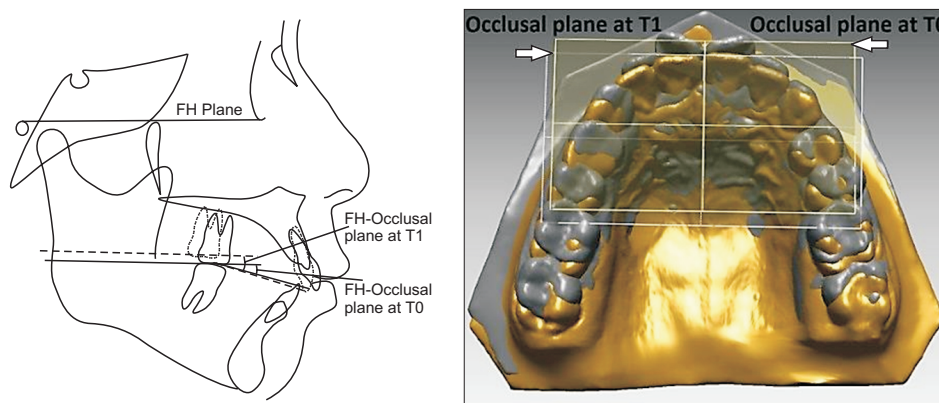
midline raphe has also been used because it significantly enhances the reliability of 3D superimposition.<sup>19,22,23</sup>

This procedure, designated as 3D surface-to-surface matching (best-fit method, Figure 1), was performed using Rapidform 2006 software.

To reduce errors of superimposition, the occlusal planes of the 3D virtual models (established using the midpoint between the maxillary right and left central incisor edges and the mesiobuccal cusp tip of the maxillary right and left first molars) were compared with those on the lateral cephalograms. After superimposition of the 3D virtual models, the angular difference in the occlusal plane was measured between T0 and T1. The amount of change in the angle between the Frankfort horizontal plane and the maxillary occlusal plane between T0 and T1 was then measured on the lateral cephalograms (Figure 2). If the angular difference between the 3D virtual models and the lateral cephalograms was more than 5°, superimposition of the 3D models was repeated to correct the error.<sup>19</sup>



**Figure 1.** Superimposition of three-dimensional pretreatment and post-treatment virtual maxillary models.



**Figure 2.** Confirmation of the accuracy of superimposition of the three-dimensional (3D) virtual maxillary models. The angle between the Frankfort horizontal (FH) plane and the maxillary occlusal plane in the lateral cephalogram was measured pretreatment (T0) and post-treatment (T1) to verify a change in the occlusal plane of the 3D virtual maxillary models between T0 and T1. If the angular difference between the 3D virtual models and lateral cephalograms was greater than 5°, superimposition of the 3D models was repeated to correct the error.

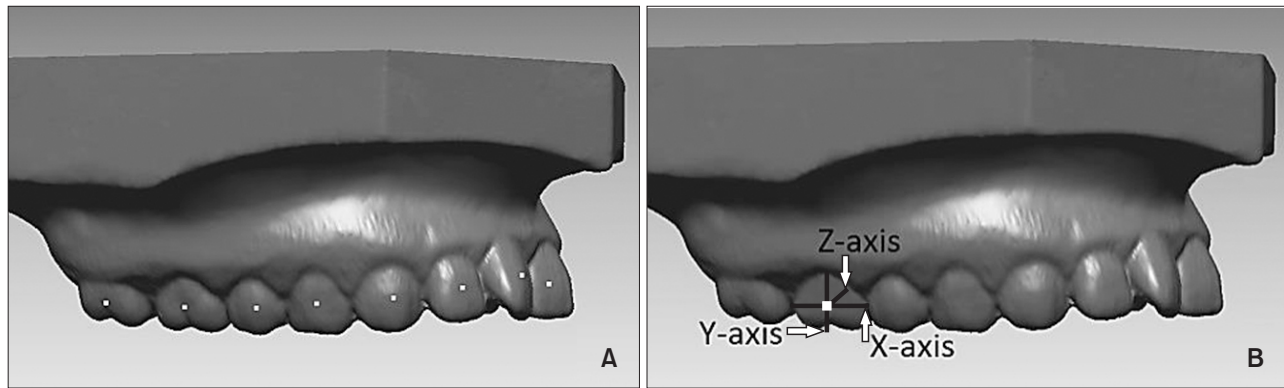
**Landmarks and reference planes for measurements**

The facial axis (FA) point<sup>27</sup> is easily recognized and does not change during orthodontic treatment, unlike the incisal edge or cusp tip.<sup>22</sup> Therefore, the FA points of the 3D virtual maxillary models were used as appropriate reference points to measure tooth movement. A 3D coordinate system was established at the FA point of an individual tooth to measure the angular variables (Figure 3). The three reference planes (horizontal, coronal, and midsagittal planes of the 3D virtual maxillary models) were used to locate the point of origin and to measure

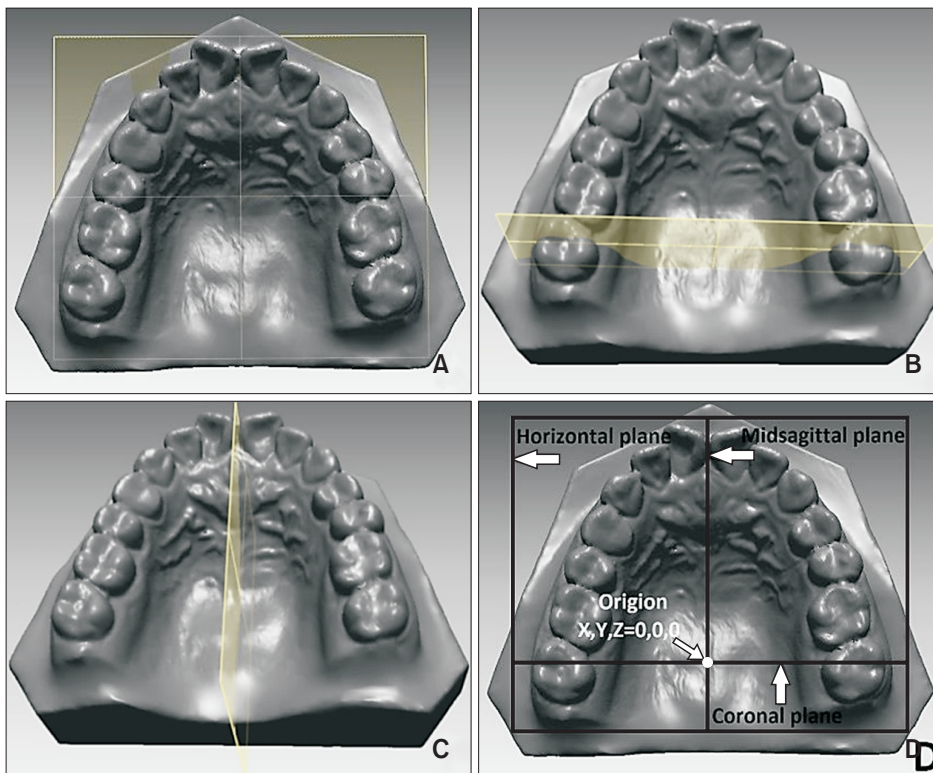
the linear and angular variables shown in Figure 4.

**Measurements**

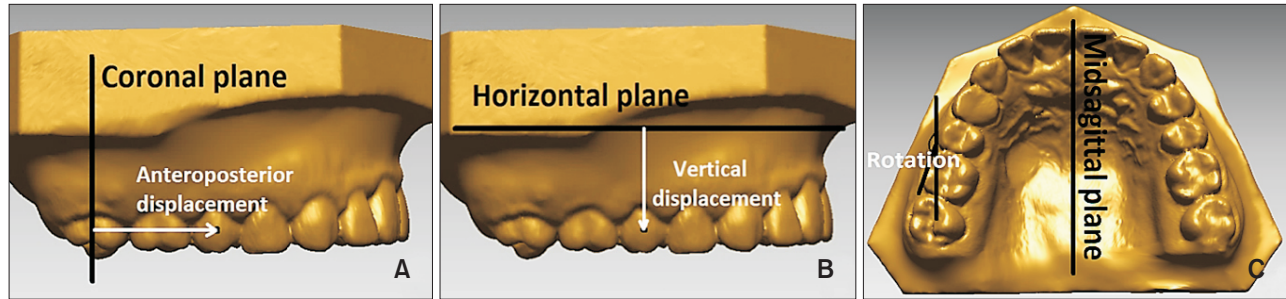
The definitions of linear variables (anteroposterior and vertical displacement of the maxillary dentition), angular variables (rotation of maxillary molars), and arch width variables are described in Figures 5 and 6. These three variables were measured at T0 and T1 using Rapidform 2006 software with the same reference landmarks and reference planes.




**Figure 3.** A, Facial axis (FA) points. B, Definition of the coordinate system established at the FA point; the X-axis is the horizontal one, the Y-axis is the vertical one, and the Z-axis is a sagittal axis perpendicular to the X-axis and Y-axis.



**Figure 4.** Definition of reference planes. A, The horizontal plane was set to the uppermost region in the midpalatal area, and was parallel to the occlusal plane. B, The coronal plane was set to be perpendicular to the horizontal plane connecting the facial axis points of the upper right and left second molars at the pretreatment (T0) stage. C, The midsagittal plane was set to be perpendicular to the horizontal and coronal planes passing through a midpoint between the maxillary right and left central incisor edges. D, The point of origin was set at the intersection of the horizontal, coronal, and midsagittal planes.



**Figure 5.** Definitions of linear and angular variables. **A**, Anteroposterior displacement (mm): distance between the facial axis (FA) point and the coronal plane. For the difference between pretreatment (T0) and post-treatment (T1), i.e., T0–T1, positive means posterior movement and negative means anterior movement. **B**, Vertical displacement (mm): distance between the FA point and the horizontal plane. For T0–T1, positive means intrusion and negative means extrusion. **C**, Molar rotation (°): the angle made with the x-axis of an individual molar tooth and the midsagittal plane on the occlusal plane. For T0–T1, positive means mesial-in rotation and negative means distal-in rotation.



**Figure 6.** Definitions of arch width variables. Intercanine width (ICW), distance between the cusp tip of right and left maxillary canines; interfirst premolar width (IP1W), distance between the cusp tip of right and left maxillary first premolars; intersecond premolar width (IP2W), distance between the cusp tip of right and left maxillary second premolars; interfirst molar width (IM1W), distance between the mesiobuccal cusp tip of right and left maxillary first molars; intersecond molar width (IM2W), distance between the mesiobuccal cusp tip of right and left maxillary second molars.

**Statistical analysis**

There was no statistically significant difference in individual tooth movement between the right and left sides at T0 and T1 (Table 1); therefore, the mean values for both sides of each tooth were used. To evaluate the reliability of the measurements, the reference landmarks were digitized twice and all samples were measured on two occasions 3 months apart by one examiner (DA).

Intraclass correlation coefficients for the linear, angular, and arch width variables showed excellent results (Tables 2 and 3), and the first measurements were used. The Shapiro-Wilk test concluded that the calculated measurements were normally distributed; a paired *t*-test was used for the statistical analysis (IBM SPSS Statistics version 21.0; IBM Co., Armonk, NY, USA).

**RESULTS**

Descriptive data containing the means and standard deviations for T0, T1, and treatment-related changes (T0–T1) as measured from the virtual models are summarized in Tables 4 and 5.

**Changes in anteroposterior tooth movement**

There were statistically significant changes in the anteroposterior position of the maxillary dentition between T0 and T1. All maxillary teeth moved posteriorly; anterior teeth U1, U2, and U3 were distalized (1.78, 0.98, and 1.39 mm, respectively; *p* < 0.01) and posterior teeth U4, U5, U6, and U7 were moved backward (1.15, 1.40, 2.04, and 2.44 mm, respectively; *p* < 0.001; Table 4).

**Changes in vertical tooth movement**

Comparing T0 and T1, there were no statistically significant differences in the vertical changes of the maxillary teeth except that the maxillary second molars (U7) were extruded (–0.86 mm, *p* < 0.01). The maxillary anterior teeth U1, U2, and U3 were extruded (–0.17, –0.05, and –0.13 mm, respectively), but the maxillary posterior teeth U4, U5, and U6 were intruded (0.21, 0.27, and 0.11 mm, respectively; Table 4). A positive value denotes intrusion and a negative value denotes extrusion.

**Table 1.** Comparison of displacement and rotation values between the right and left sides

| Variable                          | T0            |               |                 | T1           |              |                 |
|-----------------------------------|---------------|---------------|-----------------|--------------|--------------|-----------------|
|                                   | Right side    | Left side     | <i>p</i> -value | Right side   | Left side    | <i>p</i> -value |
| Anteroposterior displacement (mm) |               |               |                 |              |              |                 |
| U1                                | 42.14 ± 2.81  | 41.81 ± 2.37  | 0.291           | 40.02 ± 2.18 | 40.37 ± 2.49 | 0.187           |
| U2                                | 37.87 ± 2.16  | 38.09 ± 2.35  | 0.212           | 36.85 ± 2.27 | 37.13 ± 2.18 | 0.165           |
| U3                                | 33.16 ± 2.27  | 33.33 ± 2.26  | 0.376           | 31.67 ± 2.25 | 32.03 ± 2.15 | 0.245           |
| U4                                | 25.45 ± 2.00  | 25.63 ± 2.31  | 0.214           | 24.25 ± 2.31 | 24.54 ± 2.10 | 0.438           |
| U5                                | 18.48 ± 1.60  | 18.81 ± 1.60  | 0.134           | 17.07 ± 2.07 | 17.42 ± 2.22 | 0.349           |
| U6                                | 10.11 ± 1.14  | 10.33 ± 1.81  | 0.427           | 8.01 ± 1.86  | 8.34 ± 1.92  | 0.437           |
| U7                                | 0.00 ± 0.00   | 0.00 ± 0.00   | NA              | -2.56 ± 1.46 | -2.32 ± 1.88 | 0.606           |
| Vertical displacement (mm)        |               |               |                 |              |              |                 |
| U1                                | 12.57 ± 1.69  | 13.05 ± 2.48  | 0.219           | 12.93 ± 2.12 | 13.03 ± 2.14 | 0.195           |
| U2                                | 13.56 ± 1.91  | 13.45 ± 2.06  | 0.608           | 13.56 ± 2.17 | 13.56 ± 2.13 | 0.998           |
| U3                                | 13.74 ± 2.05  | 13.61 ± 2.23  | 0.579           | 13.82 ± 2.06 | 13.77 ± 1.99 | 0.741           |
| U4                                | 14.95 ± 2.13  | 14.99 ± 2.09  | 0.857           | 14.82 ± 2.26 | 14.70 ± 2.01 | 0.667           |
| U5                                | 15.72 ± 2.25  | 15.80 ± 2.15  | 0.664           | 15.47 ± 2.32 | 15.51 ± 2.10 | 0.834           |
| U6                                | 15.27 ± 2.33  | 15.30 ± 2.19  | 0.836           | 15.19 ± 2.37 | 15.17 ± 2.03 | 0.916           |
| U7                                | 13.58 ± 2.60  | 13.44 ± 2.33  | 0.610           | 14.52 ± 2.53 | 14.22 ± 1.98 | 0.445           |
| Rotation (°)                      |               |               |                 |              |              |                 |
| U6                                | 164.17 ± 6.95 | 167.02 ± 6.48 | 0.142           | 169.0 ± 5.40 | 171.37 ± 5.3 | 0.115           |
| U7                                | 168.58 ± 7.45 | 171.30 ± 4.58 | 0.280           | 172.2 ± 5.43 | 174.0 ± 5.07 | 0.393           |

Values are presented as the mean ± standard deviation.

T0, Pretreatment; T1, post-treatment; U1, maxillary central incisor; U2, maxillary lateral incisor; U3, maxillary canine; U4, maxillary first premolar; U5, maxillary second premolar; U6, maxillary first molar; U7, maxillary second molar; NA, not available.

The paired *t*-test was performed to assess the difference between measurements on the right and left side.

### Changes in molar rotation

The maxillary molars showed statistically significant distal-in rotation between T0 and T1. The maxillary first molar (U6) and maxillary second molar (U7) were rotated distal-in ( $-4.59^\circ$ ,  $p < 0.01$  and  $-3.08^\circ$ ,  $p < 0.05$ , respectively [Table 4]; a negative value denotes distal-in rotation).

### Changes in arch width

The intercanine width (ICW) and interfirst premolar width (IP1W) increased significantly and by a similar amount ( $-2.22$  mm,  $p < 0.01$ , and  $-2.25$  mm,  $p < 0.05$ , respectively) between T0 and T1. The intersecond premolar width (IP2W) and interfirst molar width (IM1W) also increased ( $-1.93$  and  $-2.02$  mm,  $p < 0.01$ ) between T0 and T1. The intersecond molar width (IM2W) was increased ( $-0.11$  mm) but not significantly so (Table 5). A negative value denotes an increase in arch width.

## DISCUSSION

In the present study, significant changes were observed between T0 and T1 with regard to the amount of backward movement of all maxillary dentition, that is, all maxillary teeth were distalized. The average amount of distalization in U1, U2, and U3 was 1.78, 0.98, and 1.39 mm, respectively, and in U4, U5, U6, and U7 was 1.15, 1.40, 2.04, and 2.40 mm, respectively (Table 4). These findings are comparable with those of Park et al.,<sup>1</sup> who reported that U1, U4, U6, and U7 was distalized by 0.85, 1.20, 1.64, and 1.50 mm, respectively, following group distal tooth movement using OMI anchorage. Moreover, these results are consistent with those of Oh et al.,<sup>28</sup> who reported that U1, U4, U6, and U7 was distalized by 2.64, 1.42, 1.51, and 1.95 mm, respectively, after nonextraction treatment of Class II malocclusions with OMI sliding mechanics. The difference in the amount of distalization of the maxillary teeth can be partly explained by the different amount of distalization needed and/or the different methods used to

**Table 2.** Intraclass correlation coefficients for the linear and angular variables used to assess intraexaminer reliability

| Variable                            | Right side | p-value | Left side | p-value |
|-------------------------------------|------------|---------|-----------|---------|
| <b>Anteroposterior displacement</b> |            |         |           |         |
| U1                                  | 0.999      | < 0.001 | 0.995     | < 0.001 |
| U2                                  | 0.999      | < 0.001 | 0.999     | < 0.001 |
| U3                                  | 0.995      | < 0.001 | 0.995     | < 0.001 |
| U4                                  | 0.998      | < 0.001 | 0.972     | < 0.001 |
| U5                                  | 0.998      | < 0.001 | 0.991     | < 0.001 |
| U6                                  | 0.993      | < 0.001 | 0.992     | < 0.001 |
| U7                                  | 0.847      | < 0.001 | 0.912     | < 0.001 |
| <b>Vertical displacement</b>        |            |         |           |         |
| U1                                  | 0.996      | < 0.001 | 0.996     | < 0.001 |
| U2                                  | 0.992      | < 0.001 | 0.995     | < 0.001 |
| U3                                  | 0.993      | < 0.001 | 0.995     | < 0.001 |
| U4                                  | 0.997      | < 0.001 | 0.996     | < 0.001 |
| U5                                  | 0.996      | < 0.001 | 0.997     | < 0.001 |
| U6                                  | 0.998      | < 0.001 | 0.998     | < 0.001 |
| U7                                  | 0.998      | < 0.001 | 0.992     | < 0.001 |
| <b>Rotation</b>                     |            |         |           |         |
| U6                                  | 0.982      | < 0.001 | 0.993     | < 0.001 |
| U7                                  | 0.935      | < 0.001 | 0.954     | < 0.001 |

U1, Maxillary central incisor; U2, maxillary lateral incisor; U3, maxillary canine; U4, maxillary first premolar; U5, maxillary second premolar; U6, maxillary first molar; U7, maxillary second molar.

The landmarks were digitized twice and the variables were measured on two occasions 3 months apart by one examiner (DA). Intraclass correlation coefficients for the variables were computed to assess intraexaminer reliability. Intraexaminer reliability was obtained by a one-way random effects model. Intraclass correlation coefficients were significantly different from 0.

measure; two-dimensional and 3D. In addition, in the cephalometric radiograph, the projection of bilateral teeth on the midsagittal plane is inclined to cause tracing errors because of the difficulty in identifying bilateral teeth. Consequently, tooth movements on each side are seldom investigated by cephalometric analysis. Likewise, cephalometric assessment alone cannot provide a comprehensive description of orthodontic tooth movement.<sup>29</sup>

On the other hand, the process of maxillary teeth distalization with OMI anchorage is completely different from the conventional distalization technique previously reported.<sup>7-12</sup> A two-stage method was frequently used to distalize the maxillary teeth during nonextraction treatment of Class II patients with intraoral distalizing

**Table 3.** Intraclass correlation coefficients for arch width variables used to assess intraexaminer reliability

| Variable | Intraexaminer reliability | p-value |
|----------|---------------------------|---------|
| ICW      | 0.978                     | < 0.001 |
| IP1W     | 0.994                     | < 0.001 |
| IP2W     | 0.997                     | < 0.001 |
| IM1W     | 0.996                     | < 0.001 |
| IM2W     | 0.998                     | < 0.001 |

ICW, Inter canine width (distance between the cusp tip of the right and left canines); IP1W, interfirst premolar width (distance between the cusp tip of the right and left first premolars); IP2W, intersecond premolar width (distance between the cusp tip of the right and left second premolars); IM1W, interfirst molar width (distance between the mesiobuccal cusp tip of right and left first molars); IM2W, intersecond molar width (distance between the mesiobuccal cusp tip of the right and left second molars).

The variables were measured on two occasions 3 months apart by one examiner (DA). Intraexaminer reliability was obtained by a one-way random effects model. Intraclass correlation coefficients were significantly different from 0.

appliances. In the first stage, the maxillary molars moved distally, but loss of anchorage often occurred during molar distalization, which is characterized by mesial movement of the premolars and flaring of the anterior teeth. Later, in the second stage, the premolars and the anterior teeth were retracted against the molars that were distalized in the first stage. However, OMIs are able to retract the whole maxillary dentition en masse without separation into two stages and eliminate round tripping of the premolars and the anterior segments.

Regarding the vertical displacement of maxillary dentition, Park et al.<sup>1</sup> demonstrated that all maxillary teeth intrude during distal movement of the maxillary dentition in nonextraction cases, albeit not in a statistically significant manner. In our study, although there was no statistically significant change in vertical displacement, U1, U2, and U3 were extruded by 0.17, 0.05, and 0.13 mm, respectively, and U4, U5, and U6 were intruded by 0.21, 0.27, and 0.11 mm (Table 4). The maxillary second molars were significantly extruded (0.86 mm,  $p < 0.01$ , Table 4). These results are similar to those of Yamada et al.,<sup>30</sup> who reported that the anterior teeth were extruded by 0.2 mm and the posterior teeth were intruded by 0.6 mm after use of inter-radicular OMI for distal movement of maxillary teeth without extraction. The differences in the amount of vertical displacement seemed to be partially due to the vertical position of the OMIs, which determine the vertical vector through the head of the OMI to the arch wire, and/or the level of the hooks attached to the arch wire. When force was applied to the lower-level hooks, initial displacement

**Table 4.** Changes in linear and angular variables between T0 and T1

| Variable             | T0            | T1            | T0-T1        | p-value |
|----------------------|---------------|---------------|--------------|---------|
| Anteroposterior (mm) |               |               |              |         |
| U1                   | 41.97 ± 2.56  | 40.19 ± 2.31  | 1.78 ± 1.21  | < 0.001 |
| U2                   | 37.98 ± 2.23  | 36.99 ± 2.20  | 0.98 ± 1.49  | < 0.01  |
| U3                   | 33.24 ± 2.23  | 31.58 ± 2.18  | 1.39 ± 0.9   | < 0.001 |
| U4                   | 25.54 ± 1.99  | 24.39 ± 2.18  | 1.15 ± 1.14  | < 0.001 |
| U5                   | 18.64 ± 1.75  | 17.24 ± 2.1   | 1.40 ± 1.24  | < 0.001 |
| U6                   | 10.22 ± 1.15  | 8.17 ± 1.87   | 2.04 ± 1.41  | < 0.001 |
| U7                   | 0.00 ± 0.00   | -2.44 ± 1.65  | 2.44 ± 1.65  | < 0.001 |
| Vertical (mm)        |               |               |              |         |
| U1                   | 12.81 ± 2.10  | 12.98 ± 2.10  | -0.17 ± 1.67 | 0.564   |
| U2                   | 13.50 ± 1.96  | 13.56 ± 2.12  | -0.05 ± 1.42 | 0.824   |
| U3                   | 13.67 ± 2.11  | 13.80 ± 1.99  | -0.13 ± 1.05 | 0.490   |
| U4                   | 14.97 ± 2.08  | 14.76 ± 2.11  | 0.21 ± 1.01  | 0.224   |
| U5                   | 15.76 ± 2.17  | 15.49 ± 2.18  | 0.27 ± 1.17  | 0.190   |
| U6                   | 15.29 ± 2.23  | 15.18 ± 2.17  | 0.11 ± 1.39  | 0.662   |
| U7                   | 13.51 ± 2.43  | 14.37 ± 2.24  | -0.86 ± 1.75 | < 0.01  |
| Rotation (°)         |               |               |              |         |
| U6                   | 165.60 ± 6.77 | 170.19 ± 5.40 | -4.59 ± 7.97 | < 0.01  |
| U7                   | 169.94 ± 6.24 | 173.01 ± 5.17 | -3.08 ± 6.64 | < 0.05  |

Values are presented as the mean ± standard deviation.

T0, Pretreatment; T1, post-treatment; U1, maxillary central incisor; U2, maxillary lateral incisor; U3, maxillary canine; U4, maxillary first premolar; U5, maxillary second premolar; U6, maxillary first molar; U7, maxillary second molar.

T0-T1 means the amount of change between pretreatment and post-treatment. Anteroposterior displacement: posterior movement (+), anterior movement (-). Vertical displacement: intrusion (+), extrusion (-). Rotation: mesial-in rotation (+), distal-in rotation (-).

The paired *t*-test was performed to this analysis.

**Table 5.** Changes in arch width variables between T0 and T1

| Variable | T0           | T1           | T0-T1        | p-value |
|----------|--------------|--------------|--------------|---------|
| ICW      | 33.84 ± 2.88 | 36.09 ± 1.80 | -2.22 ± 2.77 | < 0.01  |
| IP1W     | 41.77 ± 3.67 | 44.03 ± 2.19 | -2.25 ± 3.37 | < 0.05  |
| IP2W     | 48.49 ± 3.13 | 50.42 ± 2.64 | -1.93 ± 2.40 | < 0.01  |
| IM1W     | 53.92 ± 4.14 | 55.94 ± 3.07 | -2.02 ± 3.70 | < 0.01  |
| IM2W     | 61.68 ± 3.70 | 61.79 ± 4.32 | -0.11 ± 2.56 | 0.872   |

Values are presented as the mean ± standard deviation.

T0, Pretreatment; T1, post-treatment; ICW, intercanine width; IP1W, interfirst premolar width; IP2W, intersecond premolar width; IM1W, interfirst molar width; IM2W, intersecond molar width.

T0-T1 means the amount of change between pretreatment and post-treatment.

The paired *t*-test was performed to this analysis.

of the anterior segment led to lingual inclination and downward displacement of the incisal edges, as well as intrusion of the posterior segment, including the premolars and molars, which resulted in steepening of the occlusal plane.<sup>31</sup>

In addition, the maxillary second molars were significantly extruded, and this is consistent with previous studies<sup>10,32</sup> reporting extrusion of the maxillary second molars after distalization of the posterior teeth despite the vertical force vector and clockwise moment applied



to the arch wire. To prevent this, the maxillary second molar tubes should have been bonded more occlusally.

In the present study, in addition to anteroposterior and vertical movement, the maxillary molars showed significant rotation in the occlusal view. U6 and U7 were rotated distal-in about 4.5° and 3.0°, respectively (Table 4). This finding was in agreement with that of Park et al.<sup>15</sup> and Gelgör et al.,<sup>10</sup> who reported distopalatal rotation of the maxillary molars during distalization. Indeed, most subjects with a Class II malocclusion show mesial rotation of the maxillary first molars around the palatal root.<sup>33</sup> Therefore; this molar rotation improves the occlusal dental relationship and creates additional space.

In contrast, Park et al.<sup>23</sup> described that U6 and U7 rotated mesial-in by about 0.7° and 0.5°, respectively, following en masse retraction of the anterior teeth. The difference seemed to be due to the different treatment methods used. Park et al.<sup>23</sup> used OMI anchorage for closure of the extraction space by en masse retraction of the anterior teeth in the treatment of Class II division 1 malocclusion. However, in our study, OMI anchorage was used to retract whole maxillary dentition without extraction.

In terms of changes in arch width, there were large increases in the ICW, IP1W, IP2W, and IM1W of 2.22, 2.25, 1.93, and 2.02 mm, respectively ( $p < 0.05$ , Table 5). The IM2W increased by 0.11 mm, but this change was not statistically significant. The increase in arch width could be explained by the point of application of force to the maxillary dentition during distalization and the expansive effects of the arch wires. The amount of increase in the maxillary interpremolar and intermolar width appears similar to that reported by Oh et al.,<sup>28</sup> who described a 2.14 mm and 1.25 mm increase in maxillary interpremolar and intermolar width, respectively, in nonextraction treatment of class II malocclusion with OMI anchorage.

However, the results in this study were significantly higher than those published by Yamada et al.,<sup>30</sup> who observed increases of 0.4, 1.5, and 0.9 mm in ICW, IP1W, and IM1W, respectively, after using inter-radicular OMIs for distal movement of the maxillary molars without extraction. The reason for this difference seems to relate to the position of the arch wire hooks, because in the present study, these were placed between the maxillary lateral incisors and the canines whereas Yamada et al.<sup>27</sup> placed them between the maxillary canines and the first premolars. Since distal force was applied to the canines, there might be a tendency for arch expansion in the canine and premolars. Placement of arch wire hooks between the maxillary canines and the first premolars not only reduces soft tissue impingement but also prevents unwanted expansion resulting from transverse

forces between the hooks and OMIs. In our study, the amount of increase in the arch width may help to expand the constricted maxillary arch slightly in Class II division 1 malocclusions.

The limitation of this study was that tipping of the teeth after distalization was not measured. Although 3D superimposition with virtual model technology can be used to evaluate the change in maxillary dentition in Class II division 1 malocclusions, further studies are needed to explain simultaneous tooth movement in both maxillary and mandibular dentition according to the different types of malocclusion and the different treatment procedures used.

## CONCLUSION

Using OMI anchorage for treatment of Class II division 1 malocclusions without extraction, whole maxillary dentition could be retracted to achieve a class I canine and molar relationship without a significant change in the vertical position of the teeth, but the second molars were significantly extruded. Simultaneously, in the occlusal view, the maxillary arch was shown to be expanded with distal-in rotation of the molars.

## REFERENCES

1. Park HS, Lee SK, Kwon OW. Group distal movement of teeth using microscrew implant anchorage. *Angle Orthod* 2005;75:602-9.
2. Egolf RJ, BeGole EA, Upshaw HS. Factors associated with orthodontic patient compliance with intraoral elastic and headgear wear. *Am J Orthod Dentofacial Orthop* 1990;97:336-48.
3. Keles A, Sayinsu K. A new approach in maxillary molar distalization: intraoral bodily molar distalizer. *Am J Orthod Dentofacial Orthop* 2000;117:39-48.
4. Hilgers JJ. The pendulum appliance for Class II non-compliance therapy. *J Clin Orthod* 1992;26:706-14.
5. Gianelly AA, Bednar J, Dietz VS. Japanese NiTi coils used to move molars distally. *Am J Orthod Dentofacial Orthop* 1991;99:564-6.
6. Gianelly AA, Vaitas AS, Thomas WM. The use of magnets to move molars distally. *Am J Orthod Dentofacial Orthop* 1989;96:161-7.
7. Locatelli R, Bednar J, Dietz VS, Gianelly AA. Molar distalization with superelastic NiTi wire. *J Clin Orthod* 1992;26:277-9.
8. Carano A, Testa M. The distal jet for upper molar distalization. *J Clin Orthod* 1996;30:374-80.
9. Keles A. Maxillary unilateral molar distalization with sliding mechanics: a preliminary investigation. *Eur J Orthod* 2001;23:507-15.
10. Gelgör IE, Büyükyılmaz T, Karaman AI, Dolanmaz

- D, Kalayci A. Intraosseous screw-supported upper molar distalization. *Angle Orthod* 2004;74:838-50.
11. Grec RH, Janson G, Branco NC, Moura-Grec PG, Patel MP, Castanha Henriques JF. Intraoral distalizer effects with conventional and skeletal anchorage: a meta-analysis. *Am J Orthod Dentofacial Orthop* 2013;143:602-15.
  12. Mah SJ, Kim JE, Ahn EJ, Nam JH, Kim JY, Kang YG. Analysis of midpalatal miniscrew-assisted maxillary molar distalization patterns with simultaneous use of fixed appliances: A preliminary study. *Korean J Orthod* 2016;46:55-61.
  13. Miresmaeili A, Sajedi A, Moghimbeigi A, Farhadian N. Three-dimensional analysis of the distal movement of maxillary 1st molars in patients fitted with mini-implant-aided trans-palatal arches. *Korean J Orthod* 2015;45:236-44.
  14. Caprioglio A, Cafagna A, Fontana M, Cozzani M. Comparative evaluation of molar distalization therapy using pendulum and distal screw appliances. *Korean J Orthod* 2015;45:171-9.
  15. Park HS, Kwon TG, Sung JH. Nonextraction treatment with microscrew implants. *Angle Orthod* 2004;74:539-49.
  16. Trpkova B, Major P, Prasad N, Nebbe B. Cephalometric landmarks identification and reproducibility: a meta analysis. *Am J Orthod Dentofacial Orthop* 1997;112:165-70.
  17. Hatcher DC, Aboudara CL. Diagnosis goes digital. *Am J Orthod Dentofacial Orthop* 2004;125:512-5.
  18. Moles R. The SureSmile system in orthodontic practice. *J Clin Orthod* 2009;43:161-74.
  19. Joffe L. OrthoCAD: digital models for a digital era. *J Orthod* 2004;31:344-7.
  20. Cha BK, Lee JY, Jost-Brinkmann PG, Yoshida N. Analysis of tooth movement in extraction cases using three-dimensional reverse engineering technology. *Eur J Orthod* 2007;29:325-31.
  21. Thiruvenkatachari B, Al-Abdallah M, Akram NC, Sandler J, O'Brien K. Measuring 3-dimensional tooth movement with a 3-dimensional surface laser scanner. *Am J Orthod Dentofacial Orthop* 2009;135:480-5.
  22. Cho MY, Choi JH, Lee SP, Baek SH. Three-dimensional analysis of the tooth movement and arch dimension changes in Class I malocclusions treated with first premolar extractions: a guideline for virtual treatment planning. *Am J Orthod Dentofacial Orthop* 2010;138:747-57.
  23. Park HM, Kim BH, Yang IH, Baek SH. Preliminary three-dimensional analysis of tooth movement and arch dimension change of the maxillary dentition in Class II division 1 malocclusion treated with first premolar extraction: conventional anchorage vs. mini-implant anchorage. *Korean J Orthod* 2012;42:280-90.
  24. Hoggan BR, Sadowsky C. The use of palatal rugae for the assessment of anteroposterior tooth movements. *Am J Orthod Dentofacial Orthop* 2001;119:482-8.
  25. Choi DS, Jeong YM, Jang I, Jost-Brinkmann PG, Cha BK. Accuracy and reliability of palatal superimposition of three-dimensional digital models. *Angle Orthod* 2010;80:497-503.
  26. Chen G, Chen S, Zhang XY, Jiang RP, Liu Y, Shi FH, et al. Stable region for maxillary dental cast superimposition in adults, studied with the aid of stable miniscrews. *Orthod Craniofac Res* 2011;14:70-9.
  27. Andrews LF. The six keys to normal occlusion. *Am J Orthod* 1972;62:296-309.
  28. Oh YH, Park HS, Kwon TG. Treatment effects of microimplant-aided sliding mechanics on distal retraction of posterior teeth. *Am J Orthod Dentofacial Orthop* 2011;139:470-81.
  29. Lai EH, Yao CC, Chang JZ, Chen I, Chen YJ. Three-dimensional dental model analysis of treatment outcomes for protrusive maxillary dentition: comparison of headgear, miniscrew, and miniplate skeletal anchorage. *Am J Orthod Dentofacial Orthop* 2008;134:636-45.
  30. Yamada K, Kuroda S, Deguchi T, Takano-Yamamoto T, Yamashiro T. Distal movement of maxillary molars using miniscrew anchorage in the buccal interradicular region. *Angle Orthod* 2009;79:78-84.
  31. Sung EH, Kim SJ, Chun YS, Park YC, Yu HS, Lee KJ. Distalization pattern of whole maxillary dentition according to force application points. *Korean J Orthod* 2015;45:20-8.
  32. Jeon JM, Yu HS, Baik HS, Lee JS. En-masse distalization with miniscrew anchorage in Class II nonextraction treatment. *J Clin Orthod* 2006;40:472-6.
  33. Giuntini V, Baccetti T, Defraia E, Cozza P, Franchi L. Mesial rotation of upper first molars in Class II division 1 malocclusion in the mixed dentition: a controlled blind study. *Prog Orthod* 2011;12:107-13.