

# Diagnostic methods for assessing maxillary skeletal and dental transverse deficiencies: A systematic review

Dena Sawchuk<sup>a</sup>  
Kris Currie<sup>a</sup>  
Manuel Lagravere Vich<sup>a</sup>  
Juan Martin Palomo<sup>b</sup>  
Carlos Flores-Mir<sup>a</sup>

<sup>a</sup>Department of Dentistry, School of Dentistry, University of Alberta, Edmonton, AB, Canada

<sup>b</sup>Department of Orthodontics, Case Western University, Cleveland, OH, USA

**Objective:** To evaluate the accuracy and reliability of the diagnostic tools available for assessing maxillary transverse deficiencies. **Methods:** An electronic search of three databases was performed from their date of establishment to April 2015, with manual searching of reference lists of relevant articles. Articles were considered for inclusion if they reported the accuracy or reliability of a diagnostic method or evaluation technique for maxillary transverse dimensions in mixed or permanent dentitions. Risk of bias was assessed in the included articles, using the Quality Assessment of Diagnostic Accuracy Studies tool-2. **Results:** Nine articles were selected. The studies were heterogeneous, with moderate to low methodological quality, and all had a high risk of bias. Four suggested that the use of arch width prediction indices with dental cast measurements is unreliable for use in diagnosis. Frontal cephalograms derived from cone-beam computed tomography (CBCT) images were reportedly more reliable for assessing intermaxillary transverse discrepancies than posteroanterior cephalograms. Two studies proposed new three-dimensional transverse analyses with CBCT images that were reportedly reliable, but have not been validated for clinical sensitivity or specificity. No studies reported sensitivity, specificity, positive or negative predictive values or likelihood ratios, or ROC curves of the methods for the diagnosis of transverse deficiencies. **Conclusions:** Current evidence does not enable solid conclusions to be drawn, owing to a lack of reliable high quality diagnostic studies evaluating maxillary transverse deficiencies. CBCT images are reportedly more reliable for diagnosis, but further validation is required to confirm CBCT's accuracy and diagnostic superiority. [Korean J Orthod 2016;46(5):331-342]

**Key words:** Maxillary transverse deficiency, Diagnosis, Cone-beam computed tomography, Systematic review

Received December 14, 2015; Revised February 29, 2016; Accepted March 15, 2016.

**Corresponding author:** Carlos Flores-Mir.

Professor and Orthodontic Graduate Program Director, ECHA 5-528, Department of Dentistry, University of Alberta, 11405 - 87 Ave NW, Edmonton, AB, Canada.

Tel +1-780-492-7409 e-mail carlosflores@ualberta.ca

The authors report no commercial, proprietary, or financial interest in the products or companies described in this article.

© 2016 The Korean Association of Orthodontists.

This is an Open Access article distributed under the terms of the Creative Commons Attribution Non-Commercial License (<http://creativecommons.org/licenses/by-nc/4.0>) which permits unrestricted non-commercial use, distribution, and reproduction in any medium, provided the original work is properly cited.

## INTRODUCTION

The assessment of facial growth as well as the development of dental occlusion is part of the process of diagnosing orthodontic abnormalities that if prevented or treated would provide measurable benefits to patients.<sup>1</sup> Orthodontists have acknowledged that maxillary transverse deficiencies are a significant component of many malocclusions.<sup>2</sup>

The treatment of transverse deficiencies is aimed at reducing potential periodontal problems, and improving dental and skeletal stability as well as smile esthetics.<sup>2</sup> Lateral expansion of the bony halves of the maxilla at the mid-palatal suture was reported as early as the mid-19th century as a method to overcome transverse maxillary deficiencies.<sup>3</sup> Current treatment methods to address skeletal maxillary constriction include the application of orthopedic forces with slow or rapid maxillary expansion protocols in children and adolescents, and surgical mid-palatal splitting in adults.<sup>4-6</sup> After the completion of the adolescent growth spurt, as the mid-palatal suture progressively becomes more fused, heavier forces across the suture are required to produce meaningful maxillary skeletal expansion.<sup>6</sup> Therefore, it is vital to assess the craniofacial skeleton in the transverse dimension as early as possible and accurately diagnose the need for transverse maxillary expansion, to improve the efficiency and effectiveness of treatment. This has driven the continued evolution and development of diagnostic tools for evaluating the maxillary transverse dimension.

Diagnosis of maxillary transverse deficiencies can be difficult, and often includes the use of more than one of the following methods: clinical evaluation, dental cast analysis, occlusograms and/or craniofacial radiography.<sup>7</sup> Posteroanterior cephalograms (PACs) have previously been considered the most readily available and reliable way to evaluate transverse skeletal discrepancies.<sup>8</sup> Nevertheless, it is known that conventional two-dimensional (2D) imaging of skeletal structures has technical limitations that affect the accuracy of landmark placement, which along with practitioner inexperience in identifying PAC landmarks has resulted in significant landmark identification errors.<sup>9-11</sup>

To further complicate the situation, a universal gold standard has not been identified in the literature for diagnosing maxillary transverse deficiencies; however, it has been suggested that a sufficiently accurate diagnosis involves both clinical and radiographic evaluations, and PAC is currently considered the best modality for evaluating transverse skeletal dimensions.<sup>8</sup> Most commonly, clinicians use a method that relies on a combination of clinical and dental cast assessments that evaluates the presence of crossbites, degree of crowding,

arch width measurements, perceived buccolingual inclination of teeth, and the shape and height of the palatal vault.<sup>6,8</sup>

With three-dimensional (3D) imaging emerging as a feasible diagnostic modality for clinical use in orthodontics, improvements in the utilization of cone-beam computed tomography (CBCT) images to diagnose maxillary transverse deficiencies may be useful. As 3D images are not affected by the technical limitations associated with 2D PAC, the use of this technology has thus far demonstrated significantly less variability and more reproducibility of transverse measurements on CBCT-constructed PAC images, compared to conventional 2D PAC.<sup>12,13</sup> The ability to make localized and specific transversal radiographic cuts of CBCT images to assess areas of clinical interest is also of significant potential in the diagnosis of the craniofacial transverse dimension.

As the availability of CBCT imaging in clinical practice increases, it would be beneficial to determine whether CBCT imaging improves the diagnosis of transverse maxillary deficiencies, or whether it just improves landmark location precision. Clinically meaningful accuracy and reliability should be confirmed before the more widespread use of CBCT and its associated ionizing radiation is advocated. The objective of this review was to evaluate the accuracy and reliability of the available diagnostic tools used to assess maxillary transverse deficiencies.

## MATERIALS AND METHODS

Reporting of this review was based on the Preferred Reporting Items for Systematic Reviews and Meta-Analyses (PRISMA).<sup>14</sup>

### Protocol and registration

Protocol registration was not available.

### Eligibility criteria

The clinical question was generated using the PICOS format<sup>15</sup>;

*Population:* Orthodontic patients with mixed or permanent dentitions with all permanent first molars present.

*Intervention:* 3D diagnostic analysis.

*Comparison:* Combination of clinical assessments, plaster models, and/or PAC as a proxy for a gold standard, as there is no universally accepted gold standard.

*Outcomes:* Accuracy and reliability of 3D diagnostic analysis.

*Study design:* Diagnostic, observational, and interventional studies were considered. With regard to the latter, only data pertinent to the systematic review question

were collected.

Only studies that reported the accuracy, validity, and/or reliability of a diagnostic method or evaluation technique for maxillary transverse dimensions in humans with mixed or permanent dentitions and all first permanent molars present were included in the analysis. Studies that included primary dentition, only evaluated vertical and/or anteroposterior maxillary deficiencies, or included syndromic patients and cleft lip and/or palate patients were excluded.

### Information sources

A systematic search of the three electronic databases MEDLINE (OvidSP), PubMed, and EMBASE (OvidSP) from the date of their establishment to the second week of April 2015 was conducted to identify relevant studies, with the aid of a health sciences librarian.

### Search strategy

The search was conducted irrespective of language using key words, combinations of key words with truncations, and Medical Subject Headings (MeSH). The search strategy was designed for MEDLINE as shown in Appendix 1, and was adapted to facilitate searching of the other databases. Reference lists of retrieved articles were manually searched to identify additional potentially relevant articles. A limited search of the “grey-literature” was conducted via Google searching (analyzing the first 100 hits) and searching relevant textbooks using key words.

### Study selection

In the initial stage of article selection, titles and abstracts were reviewed by two reviewers (DS and KC) to remove all articles that appeared to be unrelated to the topic or breached the exclusion criteria. At this stage, any articles that evaluated maxillary transverse dimensions were included. Results between reviewers were compared to identify discrepancies. Where they existed, they were resolved by a third party (ML). Where the abstract of an identified article did not contain sufficient information (or was unavailable), the full text of that article was obtained for review. For those abstracts that were deemed potentially useful, full text articles were then reviewed in the final selection stage. Inclusion and exclusion criteria were applied again in duplicate (by DS and KC) as some of the information provided in the abstracts may have been misleading. Reference lists of full text articles that were included in the review were also manually searched to identify any additional articles.

### Data collection process

Two independent reviewers (DS and KC) assessed and obtained data from each of the selected articles. The

data collected were compared and a third party (ML) resolved any discrepancies identified.

### Data items

Data that were obtained from the final studies selected included sample size, mean age, type of diagnostic tool (including machine) used, degree of maxillary transverse dimensional deficiency, diagnostic accuracy, accuracy and reliability of each tool, and analysis or assessment method used (Table 1).

### Risk of bias in individual studies

Two reviewers (DS and KC) used the Quality Assessment of Diagnostic Accuracy Studies tool-2 (QUADAS-2) to evaluate risk of bias.<sup>16</sup> The reviewers assessed the risk of bias of each study independently and discrepancies were resolved by a third reviewer (ML).

### Summary measures

The accuracy and reliability of each method were considered, as were the sensitivity and specificity of each diagnostic technique used to assess maxillary transverse dimensions. In addition, positive predictive value (PPV), negative predictive value (NPV), positive likelihood ratio (LR+), negative likelihood ratio (LR-), and ROC curves were considered, where available.

## RESULTS

### Study selection

A flow chart of the article selection process at each stage of the review is presented in Figure 1. A total of 21 full text articles were retrieved and reviewed, of which 12 were subsequently excluded due to reasons outlined in Appendix 2. Nine articles were found to meet the selection criteria and were included for qualitative analysis.

### Study characteristics

A summary of the key study characteristics and results of the selected articles is presented in Table 1. The articles were all in English, they were published between 1995 and 2014, and the sample sizes of the studies ranged from 10–241. Only 2 studies<sup>17,18</sup> assessed the validity of the tools they used to diagnose maxillary transverse discrepancies. Five assessed the accuracy of each tool or analysis technique used to measure or predict arch widths,<sup>19–23</sup> while only 2 evaluated the reliability of a proposed transverse analysis or assessment technique.<sup>24,25</sup> No studies reported the sensitivity, specificity, PPV, NPV, LR+, LR-, or ROC curves of the methods used to diagnose transverse deficiencies.

### Risk of bias within studies

The risk of bias was assessed in each article using the

Table 1. Summary of the study characteristics reported in the included articles

Authors/ year	Sample size and sex	Mean ages (yr)	Description of maxillary dimensions or degree of malocclusion	Diagnostic tool/analysis used (including machine)	Results	Accuracy/validity or reliability of diagnostic tool/method
Cheung et al. (2013) <sup>17</sup>	-28 undocumented human skulls - Not identified by sex	- Skulls not identified by age - All have permanent dentitions	- Lack of gross asymmetry - Reproducible and stable occlusions	- Measurement of bilateral jugale and antegonial landmarks for transverse intermaxillary analysis - Comparison made between direct craniometric skull (bone skulls, BS) measurements, CBCT direct volumetric measurements (Sirona Galileo Cone Beam Imaging System) and PACs	- With 95% confidence interval, no statistically significant difference between measurement types - CBCT values compared to skulls had smallest mean difference and highest ICC (0.964) without overestimation - PACs had larger mean differences and tended to overestimate results - Ratio of J-/Ag-Ag correlation coefficients were 0.87 for CBCT-BS, 0.81 for PAC-BS, 0.80 for PA-CBCT	- All three methods shown to be reliable with mean error less than 0.5 mm between repeated measurements - J-/Ag-Ag ratio used as indicator of transverse discrepancy to assess diagnostic validity of CBCT and PA - Compared to BS ratios, PAC measurements incorrectly valued 5 skulls (18%), CBCT incorrectly valued 2 skulls (8.3%) - CBCT more accurately identified intermaxillary discrepancies
Daidjan et al. (1995) <sup>19</sup>	- 40 M, 40 F Australian Aborigines - 30 M, 30 F Indonesians - 30 M, 30 F white Australians - Total = 200	- 14.2 M, 14.7 F - 23.9 M, 22.0 F - 17.9 M, 18.0 F	- Normal occlusions and minimal dental irregularity selected for - Angle Class I molar, overbite < 4 mm, overjet < 3 mm, full permanent dentition from second molar to second molar, no missing teeth, no supernumeraries, no crossbite, minimal rotations, no orthodontic treatment, minimal attrition - Subjects selected that do not have transverse discrepancies	- Pont's index using digital caliper measurements of dental cast mesiodistal crown widths of maxillary permanent incisors and arch widths to an accuracy of 0.1 mm Pont's formulas: P width = SI × 100/80 M width = SI × 100/64 P = premolar transverse distance M = molar transverse distance SI = sum of mesiodistal widths of four maxillary incisors	- Correlation coefficients between observed arch widths and those predicted by Pont's index ranged from 0.12–0.56, the highest for male Indonesians - Only 1–32% of variation in observed arch widths could be explained by variation in predicted arch widths - Australian Aborigines: 20.6% of arch widths were within ± 1 mm of Pont's prediction - White subjects: 30.8% of arch widths within ± 1 mm of Pont's prediction - Indonesians: 17.5% of arch widths within ± 1 mm of Pont's prediction	- Pont's prediction generally underestimated actual arch widths in various populations, only 17.5–30.8% of arch widths were within ± 1 mm of Pont's prediction, this demonstrates Pont's index did not accurately predict dental arch widths and is unreliable for use in diagnosis and treatment planning.
Lee et al. (2014) <sup>20</sup>	- 20 M, 20 F - Total 40	- 27.2 M - 26.4 F	- Normal occlusions with Angle's Class I canine and molars - Excluded skeletal dysplasia, asymmetric arches, moderate-severe crowding, missing teeth, previous prosthodontic or orthodontic treatment	- Maxilla and mandible basal bone width differences compared between CBCT images and PACs with measurements at 3 sites (1st premolar, 2nd premolar and 1st molar) at 5 different bone levels - CBCT (CB MercurRay): Axial and coronal slices standardized prior to measurements - PACs (OrthoCeph OC100): - The differences between maxillary and mandibular bone widths were calculated and compared between CBCT and PACs	- Maxillomandibular width of molar area at three levels on CBCT showed statistically significant correlation with PACs (0.4–0.49 correlation coefficient <i>p</i> < 0.05) - Maxillomandibular widths at 1st and 2nd premolars did not show any significant correlation between CBCT and PACs (0.03–0.34, <i>p</i> < 0.05)	- Intraexaminer error <i>p</i> < 0.5 and ICC mean of 0.88 indicated good reliability of measurements - Study suggests assessment of skeletal transverse discrepancies using PACs with jugale and antegonial points has limitations and may be less accurate than CBCT images

Table 1. Continued

Authors/ year	Sample size and sex	Mean ages (yr)	Description of maxillary dimensions or degree of malocclusion	Diagnostic tool/analysis used (including machine)	Results	Accuracy/validity or reliability of diagnostic tool/method
Miner et al. (2012) <sup>24</sup>	- Total 241, no sex differentiation	- 13 for M and F	- Mixed and permanent dentitions with first permanent molars. Angle Class I molars and canines - Crowding, overbite and overjet < 4 mm - 21 unilateral posterior crossbite - 33 bilateral posterior crossbite - 79 control, normal transverse dimension - 61 superior convergent - 47 inferior convergent	- CBCT scans from i-CAT scanner - images oriented using specified reference planes for 2D consistency - CBCT transverse analysis was developed in the coronal plane using 2 linear measurements (maxillary and mandibular skeletal arch width) and 4 angular dental measurements (maxillary and mandibular molar angulations) - Mean values derived from the non-crossbite group	- Linear skeletal measurements significantly different between control and bilateral crossbite groups, molar angulations not significantly different - Bilateral and unilateral crossbite groups have significantly narrower maxillary widths than controls, but wider mandibles - Unilateral crossbite group have more upright teeth on non-crossbite side - Non-crossbite groups with dental compensations (superior convergent, inferior convergent) had significantly different skeletal and dental measurements from controls	- High intraexaminer and interexaminer reliability (mean 0.95)
Nimkarn et al. (1995) <sup>21</sup>	- 20 M, 20 F - Total 40	- Not specified	- All permanent teeth present first molar-first molar - Degree of malocclusion not specified	- Measurements taken with digital calipers from study models to use with Pont's Index, Schwarz's Analysis and McNamara rule of thumb - A more objective crowding index was proposed and validity was evaluated	- Crowding index correlated highly with objective measures of crowding (correlation of 0.88-0.96) - Pont's index overestimated intermolar width and interpremolar width by 2.5-4.7 mm - Schwarz's analysis overestimated interpremolar width by 2.5-4.3 mm - McNamara's rule of thumb overestimated intermolar widths by 2.7-3.7 mm	- Crowding index is a valid and more reproducible measure of dental crowding/need for expansion than objective assessments - The indices advocate an overexpanded arch, therefore treatment plans should not be based on such simplistic mathematical concepts that are not clinically valid
Podesser et al. (2004) <sup>25</sup>	- 3 M, 7 F - Total 10	- 26	- Subjects chosen irrespective of occlusion and facial morphology	- CT scans obtained with high-resolution bone algorithm (Tomoscan 7000R) with standardized frontal plane orientation - Quantitative evaluation of linear and angular parameters based on two slices, molar slice and canine slices, digitized points used for cephalometric analysis - Method evaluated nose, maxillary bones and dental arches including molar and canine inclinations	- Correlation between first and second digitized readings very high $r = 0.96-0.99$ , no significant difference - Intra-observer error had no statistically significant differences $r = 0.89-0.99$ - Inter-observer error with the exception of one measurement had no significant statistical differences but had more variation than intra-observer error, $r = 0.43-0.98$ - Variation between observers was small compared with biologic variation subject to subject	- Study suggested measurements were reproducible and reliable when performed by the same person

Table 1. Continued

Authors/ year	Sample size and sex	Mean ages (yr)	Description of maxillary dimensions or degree of malocclusion	Diagnostic tool/analysis used (including machine)	Results	Accuracy/validity or reliability of diagnostic tool/method
Rastegar- Lari et al. (2012) <sup>22</sup>	- 69 M, 74 F - Total 143	- 13.3 M, 13.2 F	- Ideal Class I occlusion. Class I posterior intercuspation, no transverse discrepancy, no lateral shift, no midline deviation, overjet less than 3.5 mm	- Dental model measurements made with digital caliper for arch width predictions according to the indexes of Pont, Schwarz & Gratzinger, Howe - Lateral and PACs taken and reference points identified including interzygomatic width, interjugal width, maxillomandibular discrepancy (intergonion width minus interjugal width) - Multivariate regression including vertical and transverse cephalometric parameters along with dental measurements to predict arch width	- Correlation of Pont's index with measured distances $R = 0.37-0.42$ , were generally larger than measured distances, only 27-37% of predictions were within 1.0 mm of actual distances - Correlation of Schwarz and Gratzinger index with measured distances $R = 0.35-0.44$ , only 26.5-42.1% of predictions were within 1.0 mm of actual measurements - Howe's stated averages of maxillary widths were within 1.0 mm of only 28% of subjects actual measurements - Linear regression showed $R^2 = 0.32-0.44$	- Pont's index, Schwarz & Gratzinger index and rule of thumb of Howe provided poor estimates of maxillary arch width and were inaccurate at width predictions - Most accurate prediction was combination of summed width of maxillary incisors and maxillary/interjugal width with the multivariate linear regression
Tai et al. (2014) <sup>18</sup>	- 12 M, 19 F - Total 31	- 12-18	- Full complement of permanent teeth - Patients randomly selected from private orthodontic practice, individual malocclusions not described	- CBCT (Sirona Galileos) and PAC images gathered - Images processed and landmarks identified on CBCT and PAC to measure transverse widths of maxilla, mandible and dentition - Skeletal transverse dimensions investigated with the following points: zygomaxillary, jugale and antegonial landmarks - Dental dimensions recorded at the position of canines and molars	- CBCT ICC = 0.90-1.00 - PAC ICC = 0.90-0.98 - CBCT and PAC measurements showed a statistically significant difference for majority of measurements - Multiple linear regression of maxillary width, U6 to predict I-J; PAC $R^2 = 47%$ , CBCT $R^2 = 73%$ - CBCT using additional predictors for maxillary width unique to CBCT $R^2 = 80%$ - ICC of intermaxillary width ratios of PAC and CBCT was 0.7 - CBCT identified 5/31 subject with intermaxillary width ratios below 77% - PAC identified 11/31 subject with intermaxillary width ratios below 77% (4/11 of these were identified below 77% with CBCT)	- High intraexaminer reliability reported for both CBCT and PAC measurements - CBCT measurements had more explanatory power for I-J and Ag-Ag ratios when compared to the same predictors used for PAC and additional variables measured only by CBCT - Provided more information to predict I-J - Enhanced accuracy of CBCT for diagnosis of maxillary deficiencies demonstrated - PAC had 5/31 false positives in identifying intermaxillary transverse discrepancy, questioning accuracy of PAC in intermaxillary transverse diagnosis
Thu et al. (2005) <sup>23</sup>	- 28 M, 57 F - Total 85	- 23.9 M, 23.2 F	- "Subjects with maxillary dental arch irregularities and missing teeth were excluded" - Did not specify inclusion criteria for the malocclusions beyond the above statement	- Head measurements taken - Maxillary dental cast measurements taken (mesiodistal distance of four maxillary incisors and premolar & molar arch widths for Pont's and Korkhaus Index's)	- Predicted dental arch measurements from Pont's index's were significantly greater than dental cast measurements, and for Korkhaus significantly lower than cast measurements ( $p < 0.01$ ) - Weak correlation coefficients (0.26-0.48) - Observed arch measurements on dental casts were not in proportion with measured incisor widths from the indices	- Does not support the accuracy of Pont's index and Korkhaus index

M, Male; F, female; BS, bone skulls; PAC, posteroanterior cephalograms; CBCT, cone-beam computed tomography; 2D, two-dimensional; ICC, intraclass correlation coefficient.

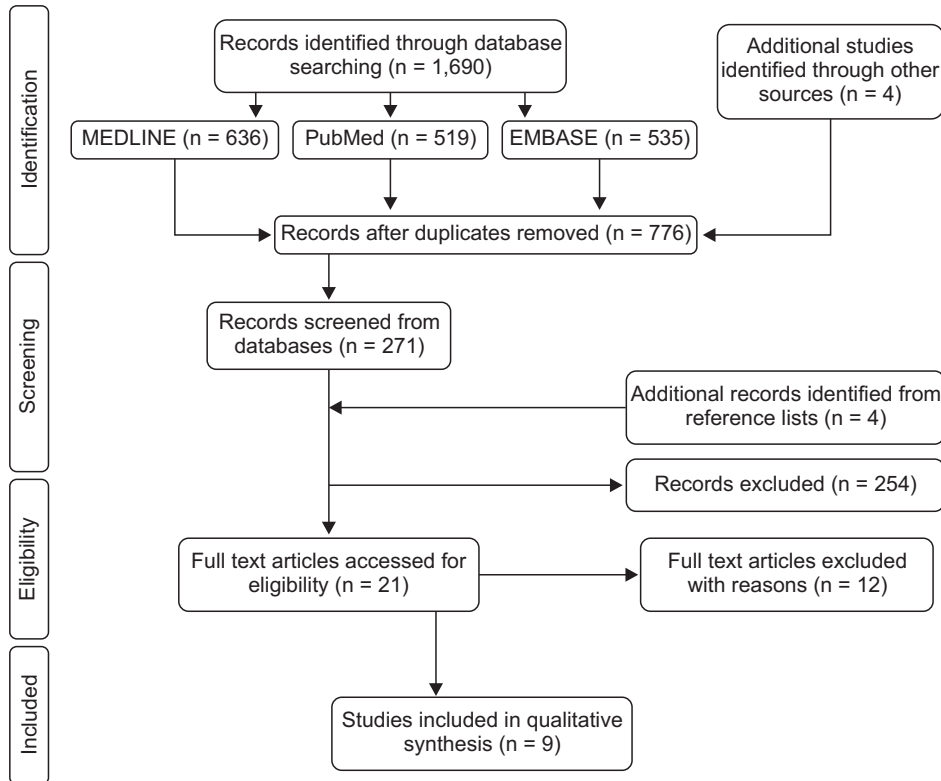


Figure 1. Flow diagram of the article selection process.

Table 2. The QUADAS-2 methodological scores of selected articles

Article	1	2	3	4	5	6	7	8	9	10	11	12	13	14	Total	% of total
Cheung et al. (2013) <sup>17</sup>	N	Y	Y	Y	Y	Y	Y	Y	Y	N	N	N	U	Y	8.5	61
Dalidjan et al. (1995) <sup>19</sup>	N	Y	N	U	Y	Y	Y	Y	Y	N	N	Y	N	N	7.5	53
Lee et al. (2014) <sup>20</sup>	N	Y	N	Y	Y	Y	Y	Y	N	N	N	Y	N	N	7	50
Miner et al. (2012) <sup>24</sup>	Y	Y	N	N	N	N	N	Y	N	N	N	Y	U	N	4.5	32
Nimkarn et al. (1995) <sup>21</sup>	Y	N	Y	U	Y	Y	N	Y	Y	N	N	Y	N	N	7.5	53
Podesser et al. (2004) <sup>25</sup>	N	Y	N	N	N	N	Y	Y	N	Y	N	N	N	N	4	29
Rastegar-Lari et al. (2012) <sup>22</sup>	N	Y	N	N	N	N	N	Y	N	Y	N	Y	N	N	4	29
Tai et al. (2014) <sup>18</sup>	Y	Y	N	Y	Y	Y	Y	Y	Y	N	N	Y	N	N	9	64
Thu et al. (2005) <sup>23</sup>	Y	N	Y	Y	Y	Y	N	Y	Y	N	N	N	N	N	7	50

1–14, Methodologic criteria in Table 2.

Y, Yes; fulfilled QUADAS methodologic criteria (1 point).

N, No; did not fulfill QUADAS methodologic criteria (0 point).

U, Unclear; did not provide sufficient information to evaluate (0.5 point).

QUADAS-2, the Quality Assessment of Diagnostic Accuracy Studies tool-2.

QUADAS tool (Table 2). The studies were heterogeneous, with moderate to low methodological quality, and all were deemed to have a high risk of bias. Six articles were of moderate quality, fulfilling 50–64% of the QUADAS criteria, and 3 were of low quality, fulfilling 29–32% of the QUADAS criteria. Common weaknesses included inconsistent reference standards attributed to the lack of a true gold standard (all studies), inadequate sample sizes,<sup>17,18,25</sup> no blinding (all studies), use of a spectrum of patients not representative of the population that would receive the assessment in practice,<sup>17,19,20,22,25</sup> and failure to validate the accuracy of the diagnostic method used to identify maxillary transverse deficiencies.<sup>19–25</sup>

### Results of individual studies

Table 1 provides a summary of the individual articles included in the current review. The studies that evaluated stone dental casts with calipers and applied various indices to predict arch width demonstrated that Pont's Index, Schwarz & Gratzinger analysis, McNamara's rule of thumb, Korkhaus' index and Howe's Index were inaccurate for predicting arch widths, and unreliable for use in diagnosis when compared to actual arch width measurements.<sup>19,21,23</sup> The crowding index<sup>21</sup> and multivariate linear regression<sup>21</sup>, which combined dental cast measurements and PAC landmarks,<sup>22</sup> were shown to be more accurate tools for predicting arch width dimensions than the other dental cast indices.

The studies<sup>17,18,20</sup> that compared transverse landmark identification and analysis of CBCT images to PAC, including one that compared both imaging techniques to dry skull measurements,<sup>17</sup> concluded that CBCT images more accurately and reliably assessed intermaxillary transverse discrepancies. Two studies<sup>24,25</sup> proposed new 3D transverse analyses with CBCT images using skeletal and dental linear and angular measurements. These demonstrated that the methods were reliable and reproducible, but did not compare them to other existing diagnostic tools to assess their accuracy in identifying transverse discrepancies.

### Analysis of results

A meta-analysis was not possible due to the heterogeneity of the diagnostic tools assessed and the variability in study designs.

## DISCUSSION

### Summary of the evidence

Accurate diagnosis of maxillary transverse deficiencies is critical for long-term periodontal stability, as an undiagnosed discrepancy may result in adverse periodontal effects and gingival recession.<sup>26</sup> In the current systematic review, the literature was analyzed to evaluate the

accuracy and reliability of the diagnostic tools used to assess maxillary transverse deficiencies in mixed and permanent dentitions. The results demonstrated that there is a lack of strong evidence and high quality diagnostic studies available that have evaluated the sensitivity and specificity of such diagnostic tools. This may be partly due to the absence of scientific literature providing evidence that supports the identification of a true gold standard diagnostic tool for evaluating skeletal transverse deficiencies. The 9 studies selected in this review were of a low to moderate standard with regard to evidence, yet they were the best studies available to address the research question; although none of them reported sensitivity or specificity.

Clinical evaluation of skeletal transverse discrepancies was not addressed in any of the studies included in the current review, although it is one of the most widely used methods for the evaluation of transverse deficiencies.<sup>27</sup> As mentioned above in the Introduction section, chair-side assessment evaluates the presence of crossbites, degree of crowding, arch widths measured at the mucogingival junction and dental crowns, perceived buccolingual inclination of posterior teeth, and the shape and height of the palatal vault.<sup>6,8</sup> One of the problems with clinical assessment is that it is based on dental crowns, without consideration of the buccolingual inclination of roots, which may camouflage the true skeletal transverse deficiency.<sup>27</sup> There may be minimal soft tissue changes associated with a maxillary transverse deficiency including paranasal hollowing, a narrow nasal base, deepened nasolabial folds, and zygomatic hypoplasia. Therefore, anteroposterior and vertical maxillary hypoplasias are much easier to clinically diagnose due to observable soft tissue changes.<sup>8</sup> Where anteroposterior and vertical maxillary dysplasias exist, they can clinically mask a transverse deficiency rendering clinical evaluation alone inadequate for the diagnosis of transverse skeletal discrepancies.<sup>28,29</sup>

Historically, orthodontics has attempted to develop arch width predictions and average measurements using dental casts to assess the transverse dimension, but few of these proposed associations are clinically useful or accurate for individualized arch width predictions.<sup>30</sup> Pont's index<sup>31</sup> was proposed in 1909, to predict maxillary arch widths from the sum of the mesiodistal widths of the four maxillary incisors. Four of the articles ultimately analyzed in this review suggested that Pont's Index poorly estimates maxillary arch widths, explaining less than 32% of arch width variations, and consistently over or underestimates actual widths; resulting in low correlations between observed and predicted maxillary measurements.<sup>19,21,23</sup> In Schwarz & Gratzinger's analysis,<sup>32</sup> they modified Pont's index by analyzing ideal maxillary interpremolar and intermolar widths corrected for facial



type, but this was shown to generally overestimate interpremolar width in 2 of the studies included in the current review.<sup>21,22</sup> Rastegar-Lari et al.<sup>22</sup> also found that Korkhaus' Index underestimated arch widths in their study population. Howe et al.<sup>33</sup> proposed a simple rule of thumb for arch width prediction by determining an average maxillary intermolar width of 37.4 mm for males and 36.2 mm for females. Two articles<sup>21,22</sup> included in the current review found that McNamara's simple rule of thumb overestimated intermolar distances and inaccurately predicted maxillary arch widths.

In summary, these indices were developed to help determine how much expansion is needed to resolve crowding, but even the limited evidence identified and perused in this review strongly suggested that such methods are inaccurate, biased, and not clinically valid for diagnosis and treatment planning in the transverse dimension.<sup>22,30</sup> Dental cast measurements that are compared with averages or used with mathematical indices lead to errors, simply due to individual variation and possible selection bias of the patient population used to initially develop such tools. It is also pertinent to note that none of these methods consider the skeletal component of maxillary constrictions, questioning the usefulness of such indices and suggesting that study models are not an appropriate basis for skeletal diagnosis in the transverse dimension.<sup>26</sup> An objective "Crowding Index" proposed by Nimkarn et al.<sup>21</sup> was found to be a more valid and reproducible tool compared to previously developed indices, but this has not been further evaluated by other studies.

Multivariate linear regressions have been proposed by Alvaran et al.<sup>30</sup> and Rastegar-Lari et al.<sup>22</sup> that include cephalometric parameters, facial height, and width measurements to enhance the reliability of index predictions, providing better estimates. However, Alvaran et al.<sup>30</sup> did not meet the inclusion criteria for this review because primary dentitions were also included in their sample and their removal from the data they provided was not possible. Rastegar-Lari et al.<sup>22</sup> provided poor quality diagnostic evidence, and neither study validated or reported the accuracy of the methods they reported.

Accurate diagnosis and treatment objectives should be based on both clinical and radiographic evaluations of transverse deficiencies, especially when surgical expansion may be required.<sup>8</sup> In the 1990s, PACs were considered the most readily available and reliable radiographs for evaluating transverse skeletal dysplasias.<sup>8,31</sup> Using Ricketts Rocky Mountain Analysis,<sup>34</sup> norms, and landmarks, Betts et al.<sup>8</sup> developed a PAC analysis method that calculates the maxillomandibular width differential. This differential indicates that a transverse discrepancy greater than Ricketts norm of 19.6 mm requires skeletal expansion, and that a surgical

approach may need to be considered in adults.<sup>8,26</sup> However, clinicians do not routinely use PACs due to limitations related to landmark identification errors, superimposition, magnification distortion, and head rotation affecting horizontal relationships,<sup>11,35,36</sup> resulting in possible miscalculation of the maxillomandibular width and an inaccurate diagnosis.<sup>27</sup> As a result, CBCT images are now being investigated for possible diagnostic superiority over 2D imaging because they have demonstrated high accuracy in quantitative and qualitative analyses, as they are better able to represent the 3D nature of the craniofacial skeleton.<sup>37</sup>

Three of the articles included in the current review compared transverse landmark identification and analysis of CBCT images to conventional PACs,<sup>17,18,20</sup> with one of these using direct dry bone skull measurements as a reference standard to compare both imaging modalities.<sup>17</sup> Cheung et al.<sup>17</sup> assessed the validity of a transverse intermaxillary analysis—the J-J/Ag-Ag ratio—on dry skulls, to identify potential errors associated with the use of PAC compared to CBCT. It was demonstrated that CBCT landmark identification was better correlated with bone skulls, and more reliable than PAC for the assessment of the intermaxillary transverse discrepancy, with CBCT incorrectly diagnosing fewer skulls (8%) than PAC (18%). Another article reported that there was no significant correlation between maxillomandibular width and CBCT images or PACs, except in the first molar area, suggesting that the assessment of transverse discrepancies using PACs may result in inaccuracies due to its 2D spatial limitations.<sup>20</sup> Tai et al.<sup>18</sup> also demonstrated a significant difference between specific landmarks identified on CBCT images compared to PACs, with CBCT better identifying patients with an intermaxillary width discrepancy. Interestingly, this article did not suggest a gold standard for the purpose of comparison. Therefore, the superiority of CBCT was a false premise in that article.<sup>19</sup> At best, they were able to demonstrate that the two methods investigated yielded different results. The superiority of one method over another with regard to precision cannot be demonstrated without a gold standard. Cheung et al.<sup>17</sup> used a dry skull as a gold standard, therefore, they were able to make a reasonable claim of superiority. However, their problem lay in the questionable clinical representation of real-life conditions when soft tissues are not depicted. These articles<sup>17,18,20</sup> had moderate methodological quality scores, suggesting there was less potential risk of bias compared to some of the other studies<sup>22,24,25</sup> included in the current review. However, the currently available evidence is not strong enough to draw reliable conclusions from, and further validation is required to confirm the diagnostic superiority of CBCT imaging.

The clinical use of CBCT in orthodontics has recently

grown from 0% to 50%,<sup>38</sup> which is not surprising as numerous studies have shown that 3D measurements closely approximate anatomic measurements,<sup>37,39</sup> supporting the accuracy of CBCT scans. CBCT demonstrates superior results over conventional 2D imaging, but its potential role in diagnosing intermaxillary transverse discrepancies is inconclusive.<sup>17</sup> Additional standardization of structure identification, measurement processes, and image orientation is needed to enhance the quality of CBCT data.<sup>18</sup> The article by Miner et al.<sup>24</sup> included in this current review aimed to develop a transverse CBCT analysis method incorporating valid skeletal and dental landmarks to analyze jaw width and first molar inclination. The reliability of this newly proposed method was confirmed, but the sample size was not large enough to investigate the clinical validity of the results or to examine sensitivity and specificity.<sup>24</sup> Podesser et al.<sup>25</sup> suggested another method to quantify the transverse dimension with computed tomography scans, involving the assessment of nasal and maxillary bones, dental arches, and molar and canine inclinations, and demonstrated a reasonably reliable 3D method to evaluate the transverse maxillary dimension. However, diagnostic accuracy was not reported in that study. Both 3D transverse analysis methods were found to be reliable and reproducible, but diagnostic validity, sensitivity, and specificity are also required to support clinical superiority over currently used diagnostic techniques. This is a clear and important limitation to our current understanding of this area. It is also critical to note that both of the proposed 3D analyses by Podesser et al.<sup>25</sup> and Miner et al.<sup>24</sup> used 3D scans, but confined analysis to specific 2D slices for evaluation, underutilizing the full 3D potential of the data and potentially introducing error due to inconsistencies in 3D image orientation.

#### Limitations of the review

At the systematic methodological review level, no reportable limitations exist as the widely accepted PRISMA guidelines were followed, and two reviewers independently selected articles and collected data to reduce selection bias. The fact that a meta-analysis was not possible is not a systematic review limitation, but rather a reflection of the limited available evidence identified.

At the study level, the most notable limitation of this review was the lack of quality diagnostic studies available for orthodontic craniofacial assessment. Of the articles retrieved, all demonstrated limited to poor evidence and a high risk of bias with regard to the reporting of diagnostic tools. None of the articles included addressed the sensitivity or specificity of the diagnostic methods used to assess clinical applicability, and 7 of them failed to validate the accuracy of

the diagnostic method for identifying transverse discrepancies.<sup>19-25</sup> Blinding was not performed in any of the studies included, and 5 evaluated a spectrum of patients with ideal class I malocclusions, which is not representative of the population that would receive the relevant assessments in practice.<sup>17,19,20,22,25</sup> One of the most notable weaknesses that impacted methodological QUADAS scores in the majority of the studies included in the current review was the use of an inconsistent reference standard. This is likely due to the lack of scientific evidence indicating a true gold standard that correctly identifies maxillary transverse deficiencies.

The establishment of a gold standard requires identification of the most accurate available method, that (optimally) always positively identifies the presence of a disease; or in this case a malocclusion.<sup>40</sup> The difficulty of evaluating the sensitivity and specificity of a diagnostic method with regard to the identification of maxillary deficiencies is at least partly due to the continuous nature of dental and skeletal measurements, and the lack of clearly defined or agreed upon thresholds identifying patients as “normal” or “abnormal”.<sup>41</sup> Given the extensive variation in the normal population, it is difficult to clearly differentiate between normal and abnormal patients with a high degree of accuracy, which would be required to develop a gold standard method.

In orthodontics, defining dental and skeletal proportions that produce functionally stable and esthetic results can be quite subjective, leading to a lack of consensus among clinicians. As shown by Streit,<sup>42</sup> when provided with intraoral and extraoral photographs, study models, frontal radiographs, and CBCT images for evaluation, there was only 55.6% agreement among experienced orthodontic clinicians when assigning patients to “transverse deficient” or “not transverse deficient” categories. The fact that expert clinicians are evidently unable to come to a consensus when identifying an “ideal” population questions the applicability of the concept of normative radiographic data. The subjective nature of orthodontic diagnoses when evaluating malocclusions, which exist on a continuum, is an inherent limitation to developing a gold standard diagnostic method in this context. This is not a problem unique to the transverse dimension; it also pertains to anteroposterior and vertical orthodontic diagnosis.

## CONCLUSION

The evidence available to-date did not allow definitive conclusions to be drawn with regard to the initial research questions, due to a lack of diagnostic studies with a low risk of bias that have evaluated maxillary transverse deficiencies. Nevertheless, some pertinent

clinical conclusions could be drawn.

It seems likely that clinical evaluation alone is inadequate for diagnosing transverse skeletal discrepancies. An objective assessment method would be more useful to clinicians.

Arch width prediction indices and average measurements derived from dental casts are not clinically applicable to the general population, and do not take the skeletal component of transverse deficiencies into account.

CBCT images appear to be more reliable than PACs, and offer an unobstructed view for the assessment of transversal intermaxillary discrepancies; though notably, further validation is required to confirm the diagnostic superiority of CBCT.

## REFERENCES

- Mitchell L, Carter NE, Doubleday B. An introduction to orthodontics. 2nd ed. New York, NY: Oxford University Press; 2001.
- Graber LW, Vanarsdall RL, Vig KWL. Orthodontics: Current principles and techniques. Philadelphia, PA: Elsevier Mosby; 2012.
- Timms DJ. The dawn of rapid maxillary expansion. *Angle Orthod* 1999;69:247-50.
- Bishara SE, Staley RN. Maxillary expansion: clinical implications. *Am J Orthod Dentofacial Orthop* 1987;91:3-14.
- Lagravere MO, Major PW, Flores-Mir C. Long-term skeletal changes with rapid maxillary expansion: a systematic review. *Angle Orthod* 2005;75:1046-52.
- Proffit WR, Sarver DM, Fields HW. Contemporary orthodontics. St. Louis, Mo: Mosby Elsevier; 2007.
- Suri L, Taneja P. Surgically assisted rapid palatal expansion: a literature review. *Am J Orthod Dentofacial Orthop* 2008;133:290-302.
- Betts NJ, Vanarsdall RL, Barber HD, Higgins-Barber K, Fonseca RJ. Diagnosis and treatment of transverse maxillary deficiency. *Int J Adult Orthodon Orthognath Surg* 1995;10:75-96.
- Malkoc S, Sari Z, Usumez S, Koyuturk AE. The effect of head rotation on cephalometric radiographs. *Eur J Orthod* 2005;27:315-21.
- Leonardi R, Annunziata A, Caltabiano M. Landmark identification error in posteroanterior cephalometric radiography. A systematic review. *Angle Orthod* 2008;78:761-5.
- Major PW, Johnson DE, Hesse KL, Glover KE. Landmark identification error in posterior anterior cephalometrics. *Angle Orthod* 1994;64:447-54.
- Nur M, Kayipmaz S, Bayram M, Celikoglu M, Kilkis D, Sezgin OS. Conventional frontal radiographs compared with frontal radiographs obtained from cone beam computed tomography. *Angle Orthod* 2012;82:579-84.
- Palomo JM, Valiathan M, Hans MGJ. 3D orthodontic diagnosis and treatment planning. In: Kapila SD, ed. *Cone beam computed tomography in orthodontics : Indications, insights, and innovations*. Ames, IA: John Wiley & Sons Inc.; 2014. p. 221.
- Moher D, Liberati A, Tetzlaff J, Altman DG; PRISMA Group. Preferred reporting items for systematic reviews and meta-analyses: the PRISMA Statement. *Open Med* 2009;3:e123-30.
- O'Connor D, Green S, Higgins JPT. Part 2: General methods for Cochrane reviews. Chapter 5: Defining the review question and developing criteria for including studies. In: Higgins JPT, Green S, eds. *Cochrane handbook for systematic reviews of interventions*, ver. 5.1.0. The Cochrane Collaboration; 2011. Available from: [http://handbook.cochrane.org/chapter\\_5/5\\_defining\\_the\\_review\\_question\\_and\\_developing\\_criteria\\_for.htm](http://handbook.cochrane.org/chapter_5/5_defining_the_review_question_and_developing_criteria_for.htm)
- Whiting P, Rutjes AW, Reitsma JB, Bossuyt PM, Kleijnen J. The development of QUADAS: a tool for the quality assessment of studies of diagnostic accuracy included in systematic reviews. *BMC Med Res Methodol* 2003;3:25.
- Cheung G, Goonewardene MS, Islam SM, Murray K, Koong B. The validity of transverse intermaxillary analysis by traditional PA cephalometry compared with cone-beam computed tomography. *Aust Orthod J* 2013;29:86-95.
- Tai B, Goonewardene MS, Murray K, Koong B, Islam SM. The reliability of using postero-anterior cephalometry and cone-beam CT to determine transverse dimensions in clinical practice. *Aust Orthod J* 2014;30:132-42.
- Dalidjan M, Sampson W, Townsend G. Prediction of dental arch development: an assessment of Pont's Index in three human populations. *Am J Orthod Dentofacial Orthop* 1995;107:465-75.
- Lee KM, Hwang HS, Cho JH. Comparison of transverse analysis between posteroanterior cephalogram and cone-beam computed tomography. *Angle Orthod* 2014;84:715-9.
- Nimkarn Y, Miles PG, O'Reilly MT, Weyant RJ. The validity of maxillary expansion indices. *Angle Orthod* 1995;65:321-6.
- Rastegar-Lari T, Al-Azemi R, Thalib L, Årtun J. Dental arch dimensions of adolescent Kuwaitis with untreated ideal occlusion: variation and validity of proposed expansion indexes. *Am J Orthod Dentofacial Orthop* 2012;142:635-44.
- Thu KM, Winn T, Abdullah N, Jayasinghe JA, Chandima GL. The maxillary arch and its relationship to cephalometric landmarks of selected malay ethnic

- group. *Malays J Med Sci* 2005;12:29-38.
24. Miner RM, Al Qabandi S, Rigali PH, Will LA. Cone-beam computed tomography transverse analysis. Part I: Normative data. *Am J Orthod Dentofacial Orthop* 2012;142:300-7.
  25. Podesser B, Williams S, Bantleon HP, Imhof H. Quantitation of transverse maxillary dimensions using computed tomography: a methodological and reproducibility study. *Eur J Orthod* 2004;26:209-15.
  26. Vanarsdall RL Jr. Transverse dimension and long-term stability. *Semin Orthod* 1999;5:171-80.
  27. de Oliveira MA Jr, Pereira MD, Hino CT, Campaner AB, Scanavini MA, Ferreira LM. Prediction of transverse maxillary dimension using orthodontic models. *J Craniofac Surg* 2008;19:1465-71.
  28. Betts NJ, Lisenby WC. Normal adult transverse jaw values obtained using standardized posteroanterior cephalometrics. *J Dent Res* 1994;73:298. abstr.
  29. Crosby DR, Jacobs JD, Bell WH. Special adjunctive considerations 1. transverse (horizontal) maxillary deficiency. In: Bell WH, ed. *Modern practice in orthognathic and reconstructive surgery*. 3th ed. Philadelphia, PA: Saunders; 1992. p. 2403-30.
  30. Alvaran N, Roldan SI, Buschang PH. Maxillary and mandibular arch widths of Colombians. *Am J Orthod Dentofacial Orthop* 2009;135:649-56.
  31. Pont A. Der zahn-index in der orthodontie. *Zeitschrift für Zahnärztliche Orthopaedie* 1909;3: 306-21.
  32. Schwarz AM, Gratzinger M. *Removable orthodontic appliances*. Philadelphia, PA: Saunders; 1966. p. 64.
  33. Howe RP, McNamara JA Jr, O'Connor KA. An examination of dental crowding and its relationship to tooth size and arch dimension. *Am J Orthod* 1983;83:363-73.
  34. Ricketts RM, Roth RH, Chaconas SJ, Schulhof RJ, Engel GA. *Orthodontic diagnosis and planning*. Denver, CO: Rocky Mountain Data Systems; 1982.
  35. Major PW, Johnson DE, Hesse KL, Glover KE. Effect of head orientation on posterior anterior cephalometric landmark identification. *Angle Orthod* 1996;66:51-60.
  36. Thurow RC. Cephalometric methods in research and private practice. *Angle Orthod* 1951;21:104-16.
  37. Lagravère MO, Carey J, Toogood RW, Major PW. Three-dimensional accuracy of measurements made with software on cone-beam computed tomography images. *Am J Orthod Dentofacial Orthop* 2008;134: 112-6.
  38. Hans MG, Valiathan M, Palomo JM. Cone beam computed tomography: A link with the past, a promise for the future. *Semin Orthod* 2011;17:81-7.
  39. Lascala CA, Panella J, Marques MM. Analysis of the accuracy of linear measurements obtained by cone beam computed tomography (CBCT-NewTom). *Dentomaxillofac Radiol* 2004;33:291-4.
  40. Cardoso JR, Pereira LM, Iversen MD, Ramos AL. What is gold standard and what is ground truth? *Dental Press J Orthod* 2014;19:27-30.
  41. Pretty IA, Maupomé G. A closer look at diagnosis in clinical dental practice: part 1. Reliability, validity, specificity and sensitivity of diagnostic procedures. *J Can Dent Assoc* 2004;70:251-5.
  42. Streit LM. *CWRU's transverse analysis developing norms [master's thesis]*. Cleveland, OH: Case Western Reserve University; 2012.

**Appendix 1.** Search Strategy for MEDLINE via OVID (1946 to present)

<b>Steps</b>	<b>Combination words</b>
1	(maxill* OR palat*).mp
2	(transverse OR arch width*).mp
3	(deficien* OR dimension* discrepanc* OR constrict* OR crossbite*).mp
4	occlusogram*.mp
5	pont's index*.mp
6	(dental model* OR dental cast*).mp
7	(CBCT* OR computed tomography).mp
8	((posteroanterior OR posterior anterior OR frontal) AND (cephalo* OR radiog*)).mp
9	(diagnos* OR quantit* OR evaluat* OR analys*).mp
10	1 and 2 and 3
11	4 or 5 or 6 or 7 or 8 or 9
12	10 and 11

## Appendix 2. Articles excluded in Phase 2

Author	Reason
Alvaran et al. <sup>1</sup>	<ul style="list-style-type: none"> <li>• Primary dentitions included in study sample</li> </ul>
Bayome et al. <sup>2</sup>	<ul style="list-style-type: none"> <li>• Did not evaluate the transverse dimension to identify deficiencies</li> <li>• Only evaluated transverse measurements between sexes and to identify correlations between vertical and transverse measurements</li> </ul>
Belluzzo et al. <sup>3</sup>	<ul style="list-style-type: none"> <li>• Did not address accuracy, validity or reliability of posterioranterior radiographic analysis in evaluating transverse deficiencies</li> </ul>
de Oliveira et al. <sup>4</sup>	<ul style="list-style-type: none"> <li>• Proposed a method to assess and predict the transverse dimension but did not report accuracy, validity or reliability of the method</li> </ul>
El-Zanaty et al. <sup>5</sup>	<ul style="list-style-type: none"> <li>• Did not apply a method or tool to assess the transverse dimension, only compared measurements between plaster and 3D casts</li> </ul>
Goldenberg et al. <sup>6</sup>	<ul style="list-style-type: none"> <li>• Only evaluated the reliability of CT in assessing post-SARPE changes, did not evaluate the use of CT as a diagnostic tool</li> </ul>
Huanca Ghislanzoni et al. <sup>7</sup>	<ul style="list-style-type: none"> <li>• Did not evaluate the use of tip &amp; torque in identifying transverse deficiencies</li> <li>• Did not assess accuracy, validity or reliability of the presented method for use in diagnosis of transverse deficiencies</li> </ul>
Lemieux et al. <sup>8</sup>	<ul style="list-style-type: none"> <li>• Did not evaluate the 3D superimposition method to be used in identifying maxillary transverse deficiencies</li> <li>• Only evaluated changes that occurred with expansion treatment</li> </ul>
Ovsenik <sup>9</sup>	<ul style="list-style-type: none"> <li>• Article evaluated degree of malocclusion in a general sense</li> <li>• Did not evaluate the accuracy, reliability or validity of assessing the maxillary transverse dimension with the method presented</li> </ul>
Sygouros et al. <sup>10</sup>	<ul style="list-style-type: none"> <li>• Only assessed transverse changes after SARME</li> <li>• No evaluation of accuracy, reliability or validity of the method for use in diagnosing the transverse dimension</li> </ul>
Talaat et al. <sup>11</sup>	<ul style="list-style-type: none"> <li>• Did not specifically assess maxillary arch dimensions for diagnostic purposes</li> </ul>
Varghese et al. <sup>12</sup>	<ul style="list-style-type: none"> <li>• Did not specifically assess maxillary arch dimensions for diagnostic purposes</li> </ul>

3D, Three-dimensional; CT, computed tomography; SARPE, surgically assisted rapid palatal expansion; SARME, surgically assisted rapid maxilla expansion.

## REFERENCES

1. Alvaran N, Roldan SI, Buschang PH. Maxillary and mandibular arch widths of colombians. *Am J Orthod Dentofacial Orthop* 2009;135:649-56.
2. Bayome M, Park JH, Kook YA. New three-dimensional cephalometric analyses among adults with a skeletal class I pattern and normal occlusion. *Korean J Orthod* 2013;43:62-73.
3. Belluzzo RH, Faltin K Jr, Ortolani C, Chelotti A. Correlation between transverse and vertical measurements in brazilian growing patients, evaluated by ricketts-faltin frontal analysis. *Dental Press J Orthod* 2013;18:50-4.
4. de Oliveira MA Jr, Pereira MD, Hino CT, Campaner AB, Scanavini MA, Ferreira LM. Prediction of transverse maxillary dimension using orthodontic models. *J Craniofac Surg* 2008;19:1465-71.
5. El-Zanaty HM, El-Beialy AR, Abou El-Ezz AM, Attia KH, El-Bialy AR, Mostafa YA. Three-dimensional dental measurements: an alternative to plaster models. *Am J Orthod Dentofacial Orthop* 2010;137:259-65.
6. Goldenberg DC, Alonso N, Goldenberg FC, Gebrin ES, Amaral TS, Scanavini MA, et al. Using computed tomography to evaluate maxillary changes after surgically assisted rapid palatal expansion. *J Craniofac Surg* 2007;18:302-11.
7. Huanca Ghislanzoni LT, Lineberger M, Cevidanes LH, Mapelli A, Sforza C, McNamara JA Jr. Evaluation of tip and torque on virtual study models: a validation study. *Prog Orthod* 2013;14:19.
8. Lemieux G, Carey JP, Flores-Mir C, Secanell M, Hart A, Dietrich N, et al. Three-dimensional cephalometric superimposition of the nasomaxillary complex. *Am J Orthod Dentofacial Orthop* 2014;146:758-64.
9. Ovsenik M. Assessment of malocclusion in the permanent dentition: reliability of intraoral measurements. *Eur J Orthod* 2007;29:654-9.
10. Sygouros A, Motro M, Ugurlu F, Acar A. Surgically

assisted rapid maxillary expansion: cone-beam computed tomography evaluation of different surgical techniques and their effects on the maxillary dentoskeletal complex. *Am J Orthod Dentofacial Orthop* 2014;146:748-57.

11. Talaat S, Kaboudan A, Breuning H, Ragy N, Elshebiny T, Kula K, et al. Reliability of linear and angular dental measurements with the

orthomechanics sequential analyzer. *Am J Orthod Dentofacial Orthop* 2015;147:264-9.

12. Varghese S, Kailasam V, Padmanabhan S, Vikraman B, Chithranjan A. Evaluation of the accuracy of linear measurements on spiral computed tomography-derived three-dimensional images and its comparison with digital cephalometric radiography. *Dentomaxillofac Radiol* 2010;39:216-23.