

Racecadotril : A Novel Antidiarrheal

Lt Col N Singh*, Lt Col S Narayan[†]

MJAFI 2008; 64 : 361-362

Key Words: Diarrhea; Anti secretory drugs; Racecadotril

Introduction

Diarrhea is among the commonest of illnesses affecting people from all age groups and causes enormous loss of money and man working hours [1]. The present modalities of treatment aim at restoring the fluid and electrolyte loss, the use of antimicrobials to eliminate the pathogens and antimotility agents to reduce the number of diarrheal days.

Oral rehydration has been the mainstay of treatment of diarrhea, however it does not reduce the frequency of stools or the number of diarrheal days. Antimotility drugs like loperamide have a limited role because of side effects. Potentiation of the effects of endogenous enkephalin activity by enkephalinase inhibition has produced a safe and effective anti secretory drug, Racecadotril [2].

Pharmacological Properties

[3-acetylmercapto-2-benzylpropanoyl] - glycine, benzyl ester, is a lipophilic derivative of thiorphan. Racecadotril is rapidly converted in the body to thiorphan, a potent enkephalinase inhibitor. Enkephalins are endogenous opioid peptides secreted by myenteric and sub mucosal neurons in the digestive tract. The enkephalins by activating the δ opioid receptor, inhibit the secretion of Cl^- and fluids thus reducing the loss of fluids and electrolytes during diarrhea [3,4]. The anti-secretory mechanisms are independent of effects on intestinal motility, differentiating this compound from μ -opiate receptor agonists like loperamide and diphenoxylate. Experimental studies in rodents and human volunteers demonstrated no delay on gastrointestinal transit or increase in experimental bacterial proliferation in small bowel of germ free piglets with racecadotril as compared to loperamide [5].

Pharmacokinetics

Racecadotril is administered by the oral route, is well absorbed from the intestinal tract and is rapidly converted

to its active metabolite thiorphan. Peak plasma levels are attained in about an hour and half life of the drug is three hours. Data on safety in pregnancy, lactation and renal/hepatic insufficiency is inadequate, which requires care in the usage.

Clinical Uses

Racecadotril is the first truly intestinal antisecretory drug to gain approval for treatment of diarrhea. The drug is available as 100 mg capsules and 10, 15 and 30 mg sachets. The recommended dosage is 100 mg three times a day for adults and 1.5 mg/kg three times a day for children. It improves the patient's perception of the effectiveness of therapy due to reduced number of stools. Studies have shown that racecadotril reduces the frequency and duration of acute diarrhea of both infectious and noninfectious origin [6-8].

Adverse Effects

The efficacy of racecadotril in acute diarrhoea is not associated with adverse gastrointestinal effects and fewer patients on racecadotril therapy suffered from abdominal distension following treatment (5.6 vs 18.2% on placebo) [9]. It caused significantly less constipation after resolution of diarrhea than loperamide. Incidence of itching was higher in racecadotril than loperamide group [10]. Racecadotril does not enter the central nervous system (CNS) thus it lacks any potential for neurotoxicity; however in children below two years of age where blood brain barrier is immature it can cause depression. Caution is also advocated in using racecadotril in disorders of carbohydrate intolerance due to the presence of saccharose as an excipient.

Conclusion

The pure antisecretory action of racecadotril, its high therapeutic index and lack of effect on the CNS makes it an ideal anti diarrheal. Whatever the type of rehydration (oral or intravenous), the treated group has

*Medical Officer (Pharmacology), Base Hospital (Delhi Cantt). [†]Classified Specialist, (Pediatrics), Military Hospital, Shillong.

a significantly lower number of stools and a faster recovery.

References

1. Revised Global Burden of Disease (GBD) 2002 estimates. WHO; World Health Report 2004.
2. Farthing F. Antisecretory drugs for diarrhoeal diseases. *Dig Dis* 2006; 24:47-58.
3. Farthing MJ. Novel targets for the control of secretory diarrhea. *Gut* 2002; 50: 315-8.
4. Farthing MJ. Introduction. Enkephalinase inhibition: A rational approach to antisecretory therapy for acute diarrhoea. *Aliment Pharmacol Ther* 1999; 13:1-2.
5. Duval-Iflah Y, Berard H, Baumer P, Guillaume P, et al. Effects of racecadotril and loperamide on bacterial proliferation and on the central nervous system of the newborn gnotobiotic piglet. *Aliment Pharmacol Ther* 1999; 13: 9-14.
6. Cojocaru B, Bocquet N, Timsit S, Wille C, et al. Effect of racecadotril in the management of acute diarrhea in infants and children. *Arch Pediatr* 2002; 9: 774-9.
7. Salazar-Lindo E, Santisteban-Ponce J, et al. Racecadotril in the treatment of acute watery diarrhea in children. *N Eng J Med* 2000; 343: 463-7.
8. Alam NH, Ashraf H, Khan WA, Karim MM, Fuchs GJ. Efficacy and tolerability of racecadotril in the treatment of cholera in adults: A double blind, randomised, controlled clinical trial. *Gut* 2003; 52: 1419-23.
9. Lecomte JM. An overview of clinical studies with racecadotril in adults. *Int J Antimicrob Agents*. 2000; 14:81-7.
10. Wang HH, Sheild MJ, Liao KF. A blind, randomised comparison of racecadotril and loperamide for stopping acute diarrhoea in adults. *World J Gastroenterol*; 2005;11:1540-3.

Radiological Quiz

Maj U Rajesh*, Lt Col NS Puar†, Maj S Vasudeva#

MJAFI 2008; 64 : 362

A 28 year old female presented with complaints of dull aching, continuous, non-radiating pain in left lower abdomen, which had no aggravating or relieving factors. Physical examination revealed a six cm palpable left sided pelvic mass.

Radiograph of the pelvis in antero-posterior projection (Fig. 1), left para-sagittal ultrasound image of the pelvis (Fig. 2) and axial contrast enhanced computed tomography (CECT) image of pelvis (Fig. 3) are shown.

What is your diagnosis?

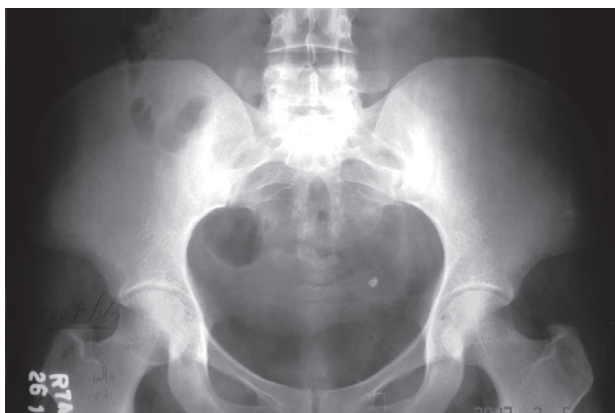

Fig. 1 : Radiograph of the pelvis in antero-posterior projection

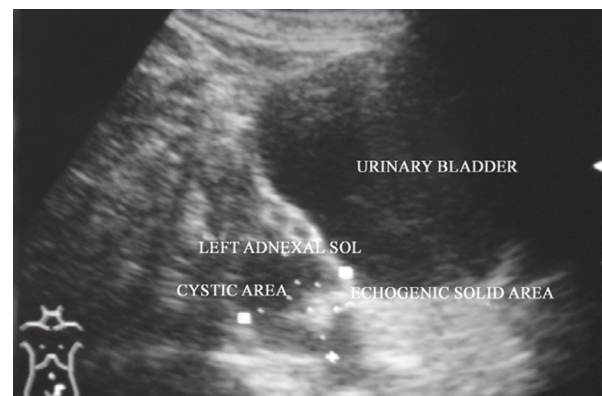


Fig. 2 : Left para-sagittal ultrasound image of the pelvis

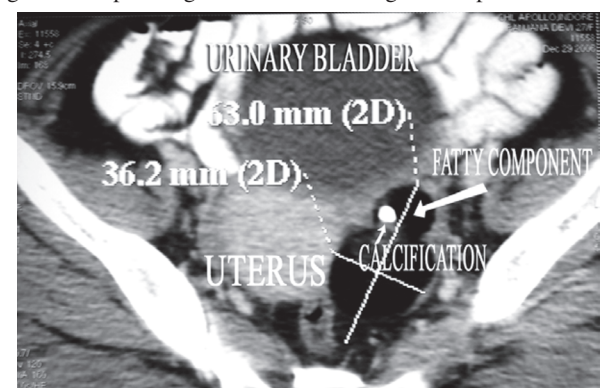


Fig. 3 : Axial contrast enhanced computed tomography image of the pelvis

Answer on Page. 384

*Graded Specialist (Radiodiagnosis), Military Hospital, Mhow- 453441 (M.P.). † Classified Specialist (Pathology), Command Hospital (Western Command), Chandimandir. #Graded Specialist (Obstetric & Gynaecology), Command Hospital (Central Command), Lucknow

Received : 16.06.07; Accepted : 26.05.08 Email : uddandamrajesh@yahoo.com