

# PAROXYSMAL TACHYCARDIA AND 2 : 1 HEART BLOCK

BY

MAURICE CAMPBELL

*From Guy's Hospital and the National Heart Hospital*

Received June 21, 1945

Recent work of William Evans (1944), demonstrating with chest leads that many cases of paroxysmal tachycardia have a faster auricular rate with 2 : 1 heart block and so resemble auricular flutter, demands a re-examination of our views of paroxysmal tachycardia. Evans has shown that chest leads, and in particular CR<sub>1</sub>, are the best method of detecting the form of auricular activity, and in view of this it may seem unwise to discuss the subject further when the material available is only the standard leads.

It is, however, possible to detect some signs of 2 : 1 block in nearly half of Evans' cases using the limb lead only (see p. 194); and it may be some time before adequate evidence with chest leads can be obtained as it is easier to make the diagnosis of, than to obtain graphic records of paroxysmal tachycardia. Meanwhile, it is important that well-established clinical facts should not be lost sight of or obscured, and that until a final classification is accepted, steps should be taken to minimize any confusion that may arise among those less familiar with and less regularly concerned with cardiographic interpretation.

The present paper deals with paroxysmal auricular (or supraventricular) tachycardia where electrocardiograms of the paroxysms were available. There is enough evidence in these records to show that 2 : 1 A-V block in paroxysmal tachycardia has often been missed and is more common than has been thought, but enough to show that it is far from being the rule. Nor does the finding of 2 : 1 block in auricular tachycardia prove that the mechanism is the same as in auricular flutter with 2 : 1 block. Evans' remarks about the rate in attacks are specially discussed: there does not appear to be any exact dividing line separating the two varieties of paroxysms according to rate. This paper is based on a study of 66 cases. In the paper of Campbell and Elliott (1939) there were 42 cases with cardiograms, but 8 of these were paroxysmal ventricular tachycardia. The remaining 34 cardiograms (taken between 1925-32) and 32 others (taken between 1933-39) have been carefully re-examined for possible evidence of 2 : 1 block. The last 32 were not a consecutive series, but their selection depended entirely on which records I have been able to find under war-time conditions after the destruction of some plates by enemy action. Unlike Evans, I have not included cases diagnosed as paroxysmal auricular flutter, and 17 examples of this are discussed separately.

I have, however, realized more strongly than ever that there are cardiograms where it is not easy to make the diagnosis between paroxysmal auricular tachycardia and paroxysmal auricular flutter (Fig. 4B, 7, 9, and 11). In the course of writing this paper two cases (see Fig. 12) have been removed from the latter to the former group.

In these 66 cases 22 provide some evidence of 2 : 1 block—10 clearly and 12 much more doubtfully—and 13 provide evidence against it. During the last few months I have not been able to get a record with chest leads of a paroxysm in any of these 13 patients, but in many of them the signs of auricular activity are so clear and the spacing of the different waves so arranged that it seems impossible that these could be 2 : 1 block. In the remaining 31 (half the total) I have not been able to see any evidence for 2 : 1 block, but the mere fact that it could be hidden and is not impossible in so many cases may be held to support Evans' view that it is common, and may help to explain why it has not been recognized more often.

TABLE I  
 CASES OF PAROXYSMAL TACHYCARDIA WITH OR WITHOUT EVIDENCE OF 2 : 1 BLOCK

	With evidence of 2 : 1 block: favouring Evans theory	With "no evidence"	With evidence against the presence of 2 : 1 block
Series A (published) (34 cases) ..	4 (+) 6	19	5
Series B (unpublished) (32 cases) ..	6 6	12	8
Total (66 cases) .. .. .	22	31	13

The differentiation of these three groups does not depend merely on the rate. In those with signs of 2 : 1 block the rate averaged 171 and varied between 144–193 (excluding the slowest and the two fastest cases). In those with evidence against 2 : 1 block the rate averaged 157 and varied between 140–176 (excluding the two slowest and the two fastest). In those without evidence either way the average rate was a little faster, 187, and twelve had rates between 200 and 240, but the remaining nineteen had rates between 145–190, the same as in the other groups. So the only conclusion that can be drawn is that if the rate is over 200 it is more difficult to see in the limb leads if there is or is not any evidence of 2 : 1 block.

#### PAROXYSMAL TACHYCARDIA WITH EVIDENCE OF 2 : 1 A-V BLOCK

Four of the 34 cases of my published series and 6 of the 32 of the second series provide fairly good evidence of hidden 2 : 1 block of the type described by Evans (1944) even without the study of chest leads.

The first (Fig. 6, Campbell and Elliott, 1939) has a deeper and wider S wave in lead II in paroxysms than in normal rhythm and this lies exactly half-way between the inverted P waves, showing its real nature. This is well shown in three separate paroxysms (Fig. 1A, all lead II) but is more difficult to see in leads I and III (Fig. 1B) although there is again in lead I the wider R wave without this clearly having the same significance.

In the second (Fig. 2) the 2 : 1 block (which was missed previously) is best shown in leads I and II where parts of the alternate missing P waves have been marked in on the left of the figure. In both leads I and II it is the curved upstroke of R (occurring exactly half-way between the two easily visible P waves) that represents the fusion of a hidden P wave and an ordinary R wave.

The third (Fig. 3) is perhaps less convincing, but especially in lead II of one paroxysm and in lead III of another there seems clear evidence of a small wave at a rate double that of the ventricle. None of these three look like the ordinary curves of 2 : 1 flutter.

The fourth (Fig. 5, Campbell and Elliott, 1939) is best shown in the small wave coming immediately after S in lead II and in the peak just after S in lead III, both these features being absent from the accompanying record of normal rhythm and being placed just half-way between the more obvious evidence of auricular activity. This patient, aged 57 when his paroxysms started, developed established auricular fibrillation 6 years later: it is possible that his paroxysms were flutter with very poorly marked auricular waves.

The fifth case has two very different types of paroxysms in 1934 and in 1937. The former (Fig. 4A) had no very good evidence of 2 : 1 block though the points that make me think it is present have been marked. (If those who are not convinced would set their dividers for exactly half the distance between successive R waves, I think they will be surprised at how often this shorter distance seems to fit exactly on to some rather small waves that had previously seemed obscure.) The later attacks (Fig. 4B) seem to have rather clearer evidence of 2 : 1 block though the auricular waves are very minute. This is the sort of case where the chest leads would probably show the auricular activity more clearly. It is also a case where the possibility of flutter with very small auricular excursions must be considered.

The sixth case (Fig. 5) is one where I had many records taken over some years, both of paroxysms and of normal rhythm. In normal rhythm the upstroke of R II is generally notched with a rather short P–R interval and the downstroke is always sharp: in paroxysms the downstroke of R is always notched and this is exactly half-way between the most prominent wave (probably P) between the QRS waves.

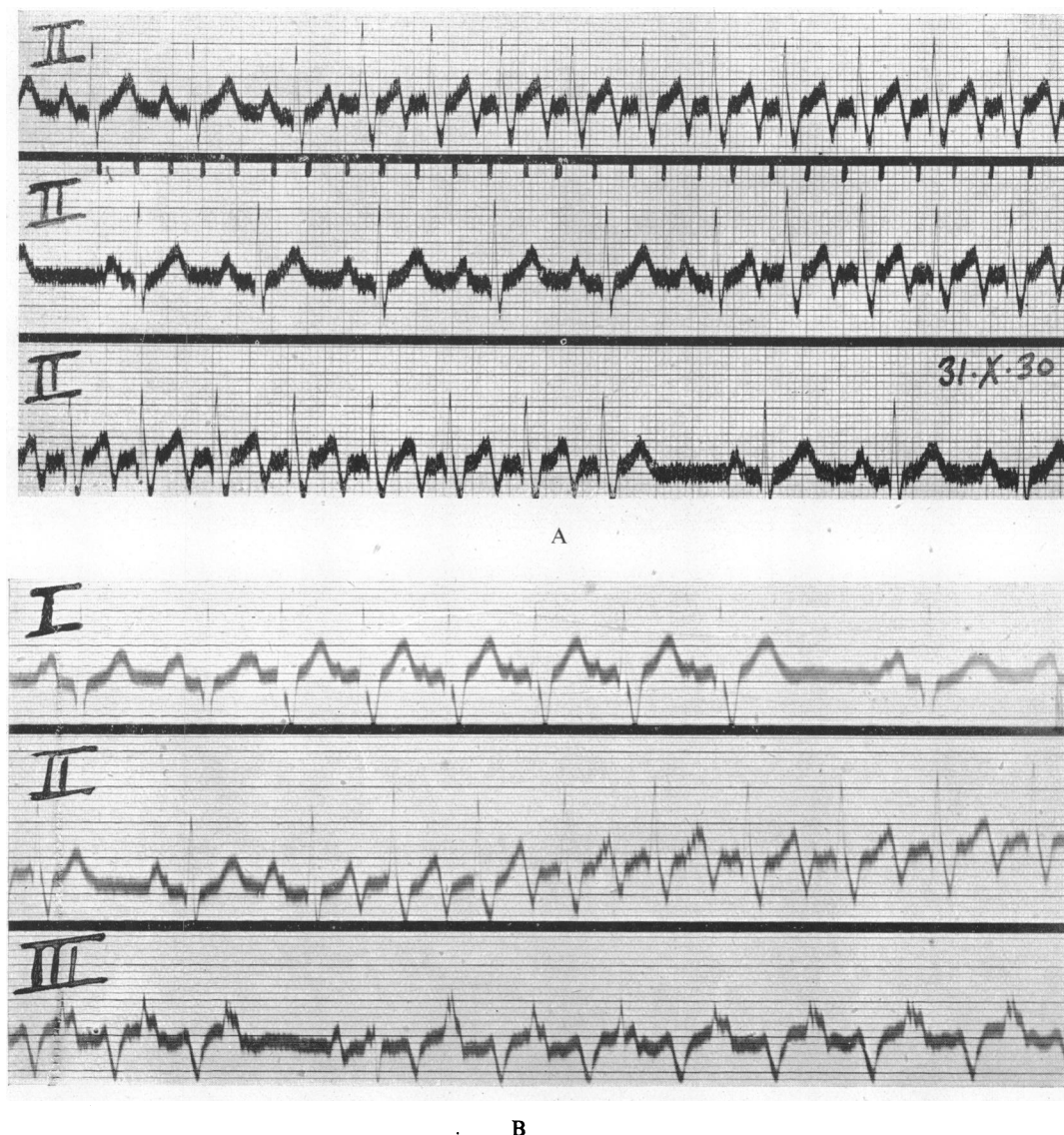


FIG. 1.—Paroxysmal auricular (? high nodal) tachycardia with 2: 1 block (A, 300; V, 150) from a boy with a heart that was otherwise normal, who had frequent short paroxysms during four years' observations. Case 2.

(A) Lead II only. Deeper and wider S waves are seen in all three paroxysms exactly half-way between the inverted P waves. (B) Standard leads. The same change is readily seen in lead II; in leads I and III it can, I think, be seen but would have been more difficult to demonstrate without lead II. This and the other figures have been reduced to about 5/6ths.

The seventh (Fig. 6) is rather different. That there is some auricular activity twice as fast as the ventricular seems very obvious in any of the three standard leads, but it had not been noticed by me though perhaps it would have been by many readers. (I had not studied this record for publication in my previous series but have always been interested in all my records of paroxysmal tachycardia.) The wide notched P wave following QRS had been passed as a wide notched QRS. The P wave in normal rhythm is less notched but it is wide and the P-R interval is prolonged so 2: 1 block is less unexpected.

The eighth (Fig. 7) and ninth are similar and without making a firm diagnosis I had thought of paroxysmal flutter with 2: 1 block but had decided on paroxysmal tachycardia because of the shape of the curve of auricular activity. Some may think the first diagnosis was correct as there is little of the curve on the iso-electric level.

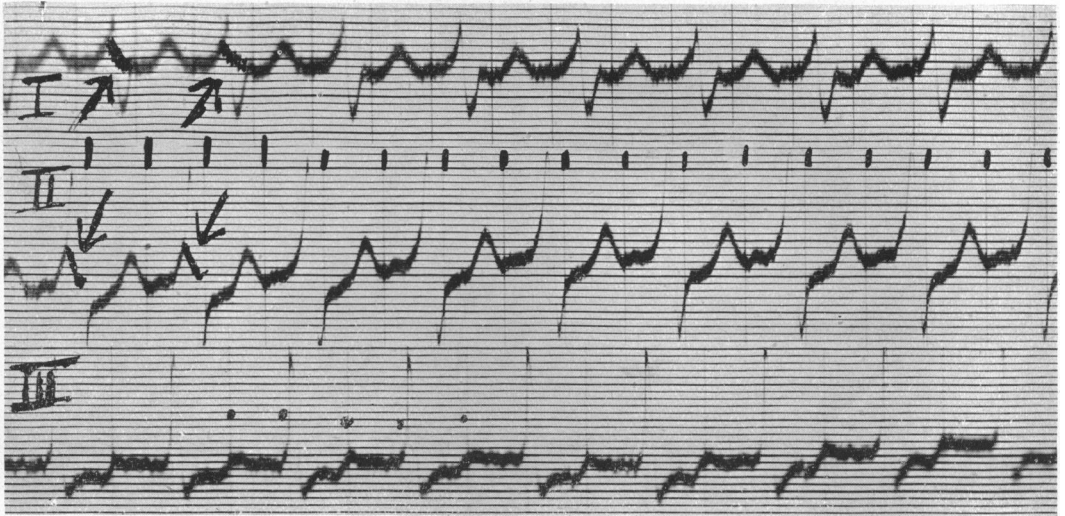


FIG. 2.—Paroxysmal auricular (? high nodal) tachycardia with 2 : 1 block (A, 300; V, 150) from a woman, aged 26–50, with mitral stenosis. Her attacks lasted up to 9 hours and came about once a month. Case 3. The second wave is partly hidden by QRS but its suspected shape has been inked in and marked with an arrow on the left of the figure.

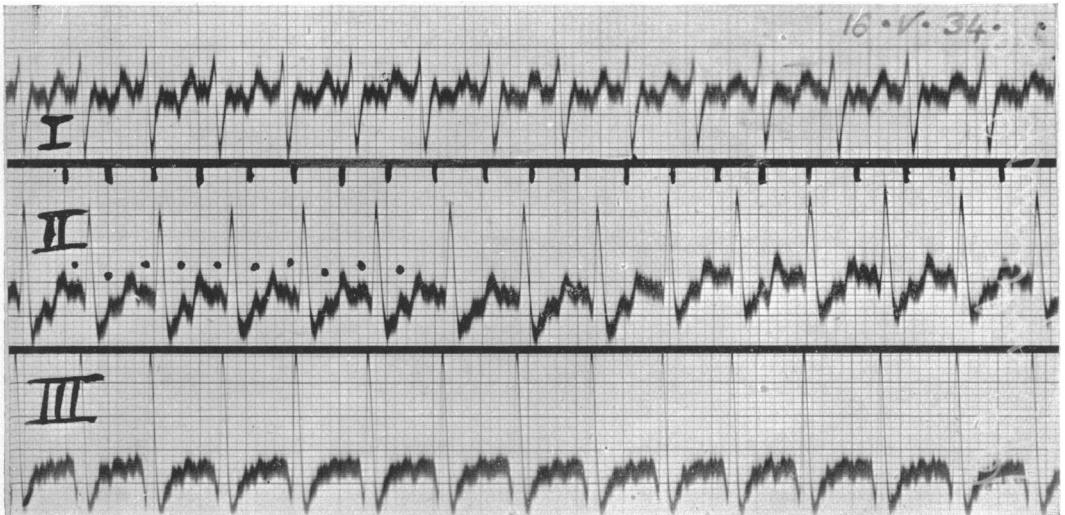


FIG. 3.—Paroxysmal supraventricular tachycardia with 2 : 1 block (A, 396; V, 198). From a woman, aged 27, with mitral stenosis who was under observation 9 years with attacks lasting from 6–48 hours. Case 84. The suspected P waves have been marked with a dot in lead II.

The tenth (Fig. 8) was (I now think wrongly) classified as paroxysmal flutter mainly because he showed at times 2 : 1 and at other times 1 : 1 block. Diagnosed clinically as paroxysmal tachycardia the first record of an attack shows 2 : 1 block (A, 222; V, 111; Fig. 8A). Although the auricular waves were not the shape of flutter I decided that the presence of block indicated this diagnosis. A few days later Fig. 8B was obtained without 2 : 1 block (A, 182; V, 182). This was certainly slow for 1 : 1 flutter which I thought it must be on the evidence of Fig. 8A, and alone it would certainly have been diagnosed as paroxysmal tachycardia.

Incidentally Fig. 8B disproves Evans' suggestion that all cases have 2 : 1 block. If 2 : 1 block is present but missed in this record, then 4 : 1 block should be present in Fig. 8A; this is obviously not so, as the curves indicating auricular activity could not be seen more clearly than they are in the standard leads.

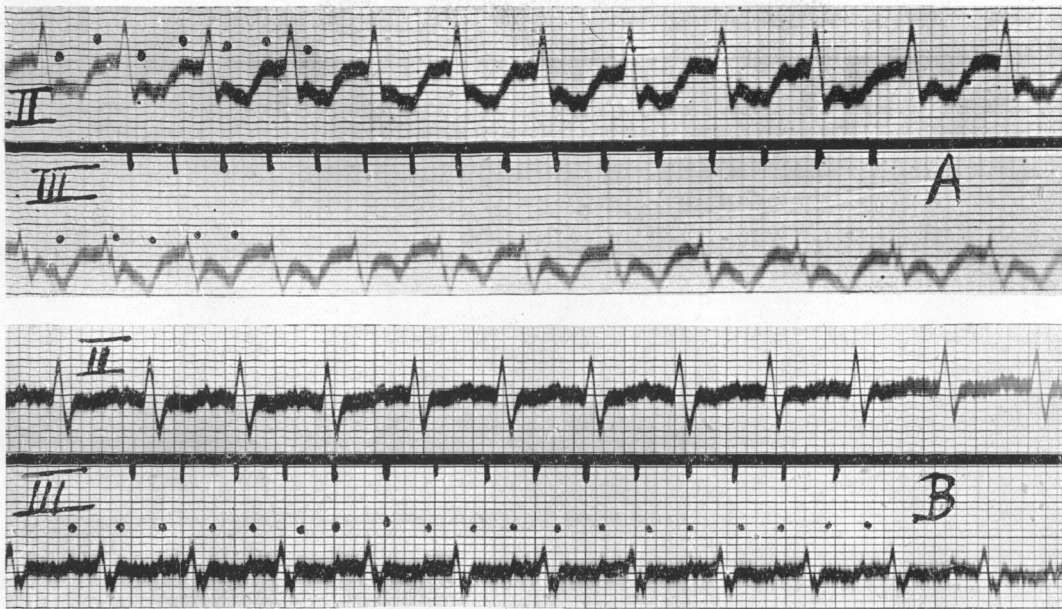

FIG. 4.—Paroxysmal supraventricular tachycardia with 2:1 block from a man, aged 68, with a large heart and high blood pressure, with attacks of increasing frequency lasting up to 7 days during the last 4 years of his life.

(A) 16/7/34, leads II and III. A, 332; V, 166. (B) 24/12/37, leads II and III. A, 342; V, 171. This might be flutter with 2:1 block with very low voltage auricular curves. In both cases the suspected P waves have been marked with dots.

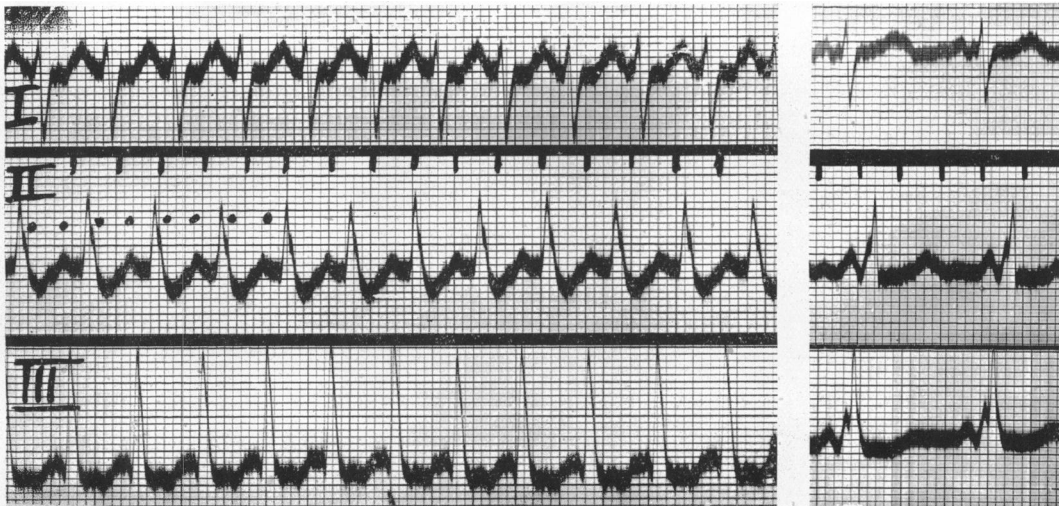

FIG. 5.—Paroxysmal supraventricular tachycardia with 2:1 block from a woman, aged 46, whose heart was otherwise normal. Attacks had been present for 25 years and lasted up to 48 hours.

On the right, normal rhythm. On the left, paroxysmal tachycardia (A, 386; V, 193), with the intervening P wave notching the downstroke of R in lead II and to a lesser extent in lead III.

I was reminded by these last records of an earlier one that I had put away not labelled more precisely than auricular tachycardia with 2:1 and 1:1 block (Fig. 9). I had not diagnosed paroxysmal tachycardia because the attacks were so long that it was almost if not quite the dominant rhythm during the last months of his life; but the marked waves favour this diagnosis, though the general shape of the curve resembles flutter. I have not included this case in either group.

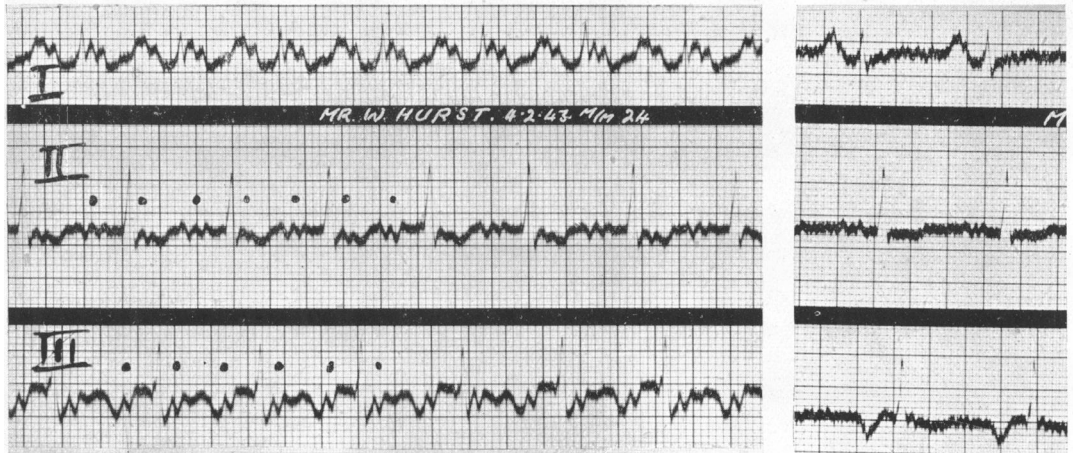


FIG. 6.—Paroxysmal auricular tachycardia with 2 : 1 block (A, 228; V, 114) from a man, aged 29, with mitral stenosis. His attacks generally lasted about 1–6 hours and had been present several years. On the right, normal rhythm, rate 82. On the left, a paroxysm. The P waves are large and notched, even more than in the record of normal rhythm, and this produces an unusual and curious appearance of the record. It is also unusual in that the 2 : 1 block is most easily seen in leads I and III.

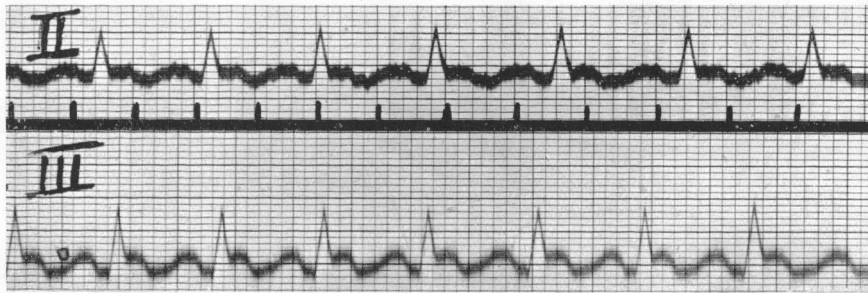

FIG. 7.—Paroxysmal auricular tachycardia with 2 : 1 block (A, 338; V, 169) from a woman, aged 50, with hyperthyroidism, and frequent paroxysms, generally lasting a few hours. The 2 : 1 block is more obvious than in many records and paroxysmal flutter with 2 : 1 block was thought a possible diagnosis. The shape of the auricular curves (here and in Fig. 9) is somewhat like flutter, but on the whole the shape was thought to be more against than in favour of flutter.

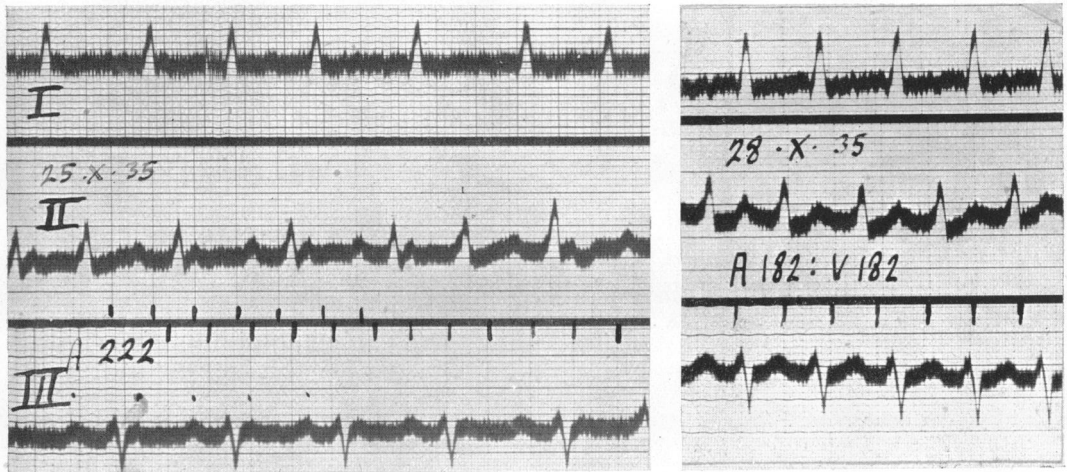


FIG. 8.—Paroxysmal auricular tachycardia with and without 2 : 1 A-V block, from a man of 44, who died with acute pericarditis and possibly syphilitic myocarditis after 18 months with paroxysms, generally lasting one or two hours. (A) With 2 : 1 block. A, 222; V, 111. (B) Without 2 : 1 block. A, 182; V, 182. Fig. 8 (B) proves that paroxysmal tachycardia occurs without hidden 2 : 1 block, because if 2 : 1 block was present but hidden here, 4 : 1 block would be present in Fig. 8 (A), which is obviously not the case.

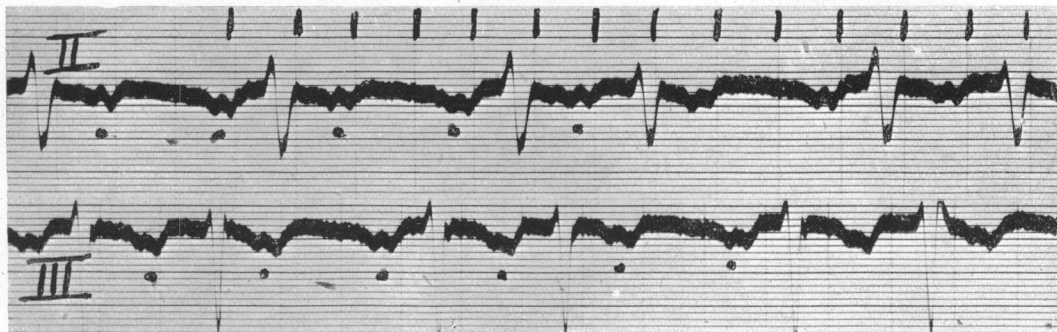


FIG. 9.—Irregular block (1:1 and 2:1) in auricular tachycardia from a man, aged 65, with myocardial disease. The case was not diagnosed as paroxysmal tachycardia, because of the block (now admitted to be an inadequate reason) and because the tachycardia was present for nearly or quite as much time as the normal rhythm. Lead II and III only.

The 12 that provide some slight evidence of 2:1 block need not be detailed but Fig. 10, 11, and 12 are given as examples. If the earlier 10 cases have not succeeded in convincing the reader that 2:1 block occurs but has been overlooked, these less striking ones will not do so: in any case a final decision as to how common the different types are will have to be reached after more detailed studies of unselected series making use of chest leads.

Fig. 10 is from a woman of 39 who had had frequent paroxysms for four years. She was obese and had a severe microcytic anæmia (Hb. 36 per cent but had been raised to 55 per cent with iron). She died from a pulmonary embolism from extensive venous thrombosis in both iliac veins. Death was during the second day of an attack but there had been other longer attacks. It is only in lead III as marked that there seemed to be some evidence of 2:1 block.

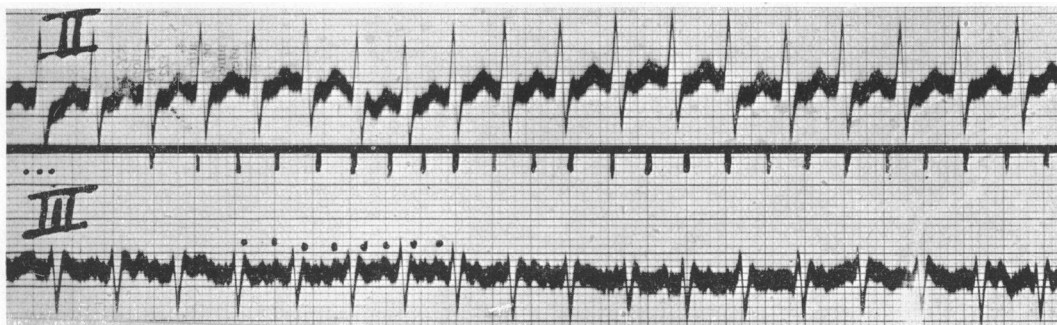


FIG. 10.—Paroxysmal supraventricular tachycardia with possible 2:1 block. Ventricular rate 200 (see text). Leads II and III only.

Fig. 11 has perhaps a little more evidence of 2:1 block as marked in leads II and III. The only known paroxysm followed a gastrectomy for a fibro-sarcoma of the stomach in a man of 61; the rhythm changed to fibrillation after seven days and then to normal rhythm with digitalization.

Fig. 12 shows a paroxysm—the only known one in a woman, aged 48, who had been under observation for twelve years with bradycardia and cardiac enlargement of unknown origin. She was in hospital at the time with bronchitis and threatened left ventricular failure. Generally she had left ventricular preponderance with rather wide QRS waves but not the picture of bundle branch block as during the attack. This was a record first diagnosed as paroxysmal tachycardia, then (on evidence of lead II) as paroxysmal flutter with 2:1 block, and finally again as probable paroxysmal tachycardia.

Fig. 13 (here) and Fig. 4 and 18 (Campbell and Elliott, *loc. cit.*) may be taken as examples of curves I have classified as “no evidence.” I can find nothing to suggest that there is 2:1 block but the main waves R and T or R and P are so spaced that they could hide such evidence if it was present.

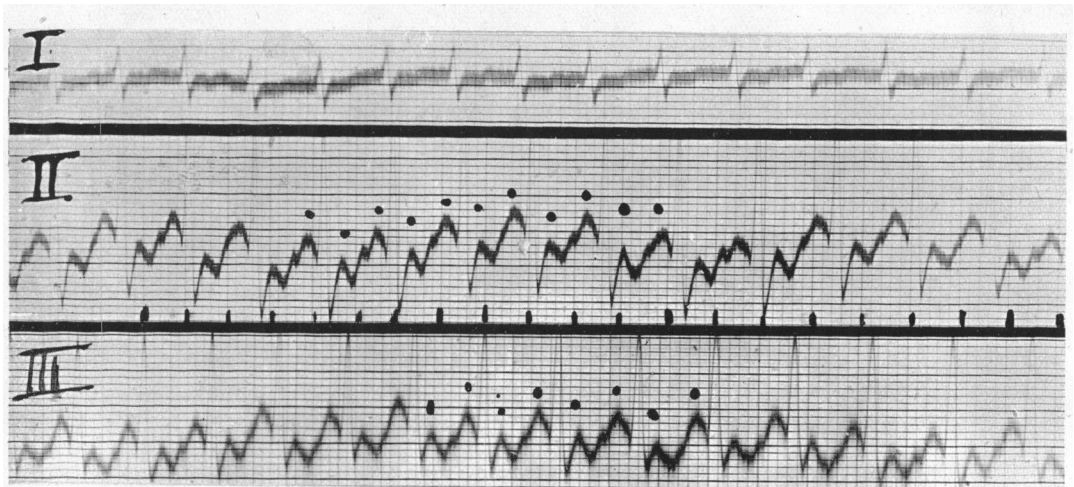


FIG. 11.—Paroxysmal supraventricular tachycardia with possible 2 : 1 block. Ventricular rate 166 (see text).  
Owing to the shape of the curves of auricular activity, it is more difficult to exclude auricular flutter with 2:1 block in this case.

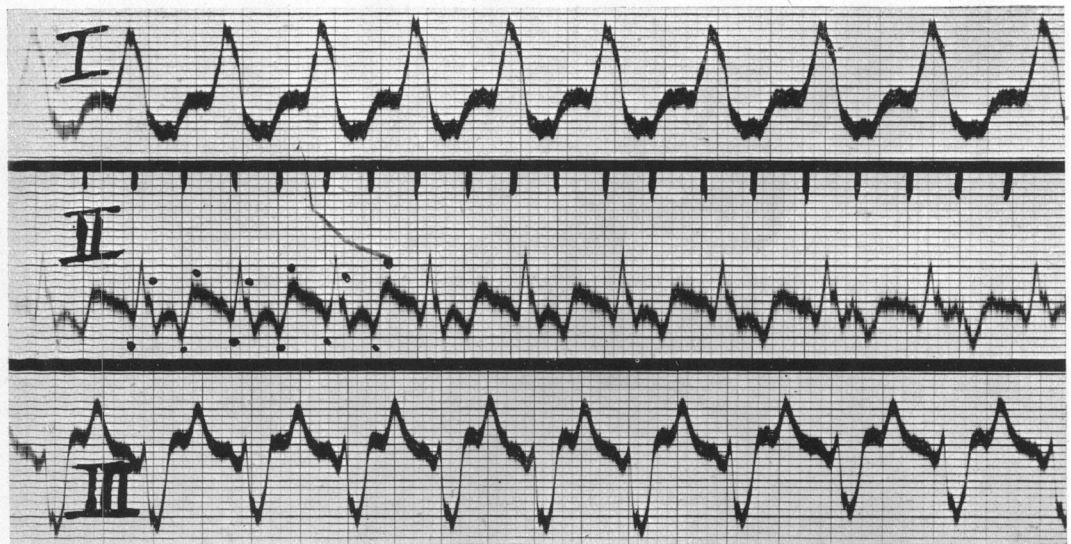


FIG. 12.—Paroxysmal tachycardia, ventricular rate 148 (see text).  
It is thought to be paroxysmal auricular tachycardia with bundle branch block and 2 : 1 block; but a diagnosis of paroxysmal ventricular tachycardia or of paroxysmal flutter with 2 : 1 block (see lead II) could be made. This curve illustrates the difficulty of decisive diagnosis in such cases without other experimental observations.

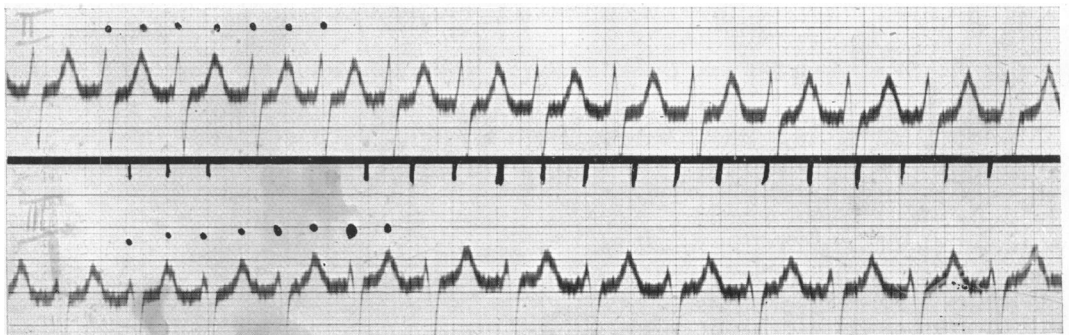


FIG. 13.—Paroxysmal supraventricular tachycardia where there is no direct evidence of 2 : 1 A-V block, but where it can not be excluded, as indicated by the dots. Ventricular rate 166. Leads II and III only.  
From a man, aged 49, whose heart was otherwise normal. Paroxysms had been present for 5 years and did not generally last more than 2 hours.



Fig. 13 is from a patient whose attacks were clinically ordinary paroxysmal tachycardia: there is no positive evidence of 2:1 block but the sharp tip of the T wave is so exactly halfway between the rather broad R that P waves might be hidden at one or both of these points. Half of all my cases (31 of 66) belonged to this group.

#### PAROXYSMAL TACHYCARDIA WITHOUT 2:1 BLOCK

In his series Evans recorded no such cases, but they appear to be fairly common—13 of the 66 cases. In these the curves of auricular activity are easily seen, and at the point halfway between these waves there is a level or-nearly level iso-electric period in which it should be easy to see the second auricular wave were it present. Fig. 14 (Fig. 7 of Campbell and Elliott) is perhaps the most striking example.

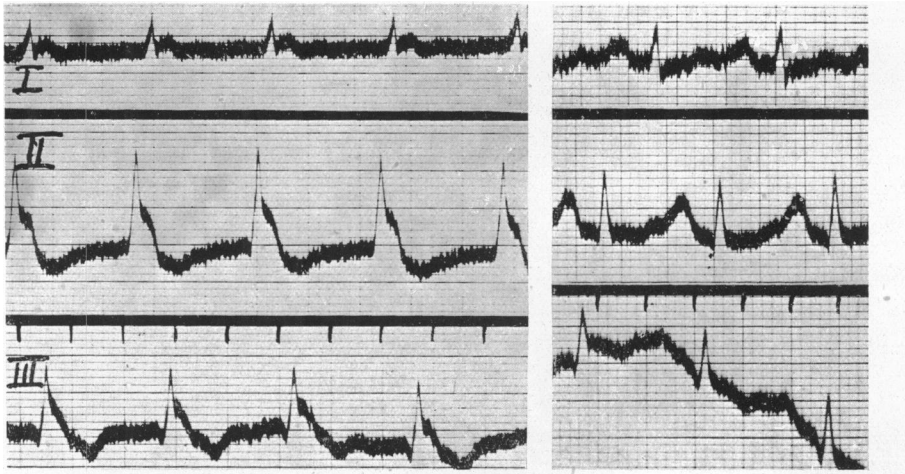


FIG. 14.—Paroxysma nodal tachycardia, rate 125, without 2:1 block. On the right normal rhythm. From a woman, aged 27, with mitral stenosis (Case 87). Attacks had been present for 6 years and generally lasted less than an hour.

The ending of the large P wave is seen just on the downstroke of R, especially in lead II, and there could not be 2:1 block as such a large wave could not be missed elsewhere in the record.

Three other examples of different types of supraventricular paroxysmal tachycardia are illustrated. In Fig. 15 the P-R interval is normal in the paroxysm in lead II but the P wave is fairly deeply inverted—the type that I have called “high” nodel. A second P wave, if it

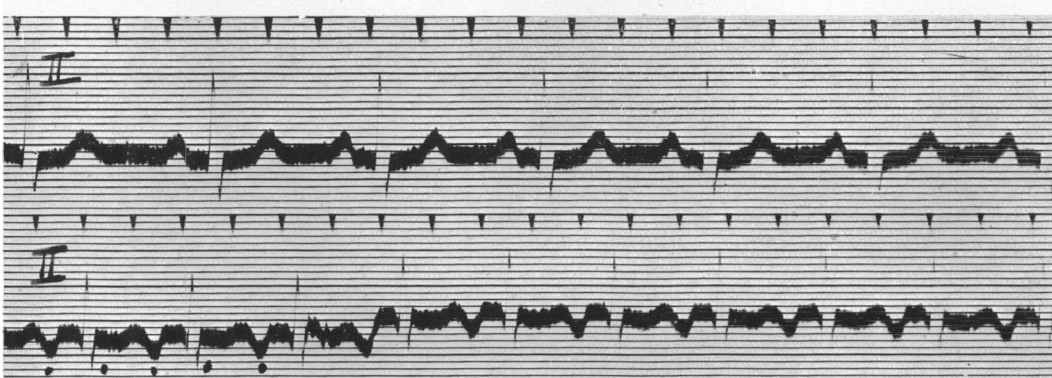


FIG. 15.—Paroxysmal “high nodal” tachycardia without 2:1 A-V block (below); and normal rhythm (above). From a woman, aged 34, with frequent short attacks whose heart was otherwise normal. Case 22. Lead II only.

The spacing is such that a second inverted P wave would be easily visible after QRS, were it present.

were present, would be easily seen in the smooth iso-electric S-T period shortly after S (marked with a dot).

Fig. 16 has an inverted P wave shortly after QRS—a typical example of nodal tachycardia. If a second P wave were present it should be easily seen in the level period just before QRS

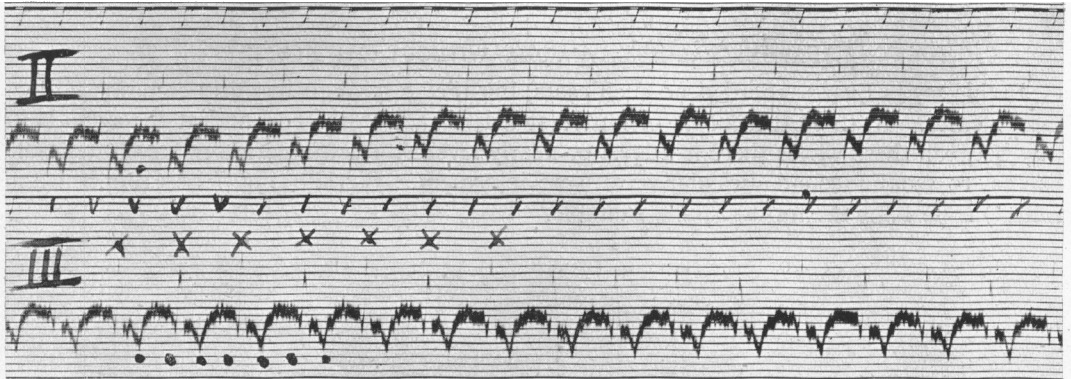


FIG. 16.—Paroxysmal nodal tachycardia without 2 : 1 A-V block. From a woman, aged 53, with a heart that was otherwise normal and frequent paroxysms lasting up to half an hour over a period of 36 years. Case 42. Leads II and III only.

The spacing is such that a second inverted P wave would be easily seen before QRS (as marked with dots), were it present.

in either lead II or III, and as there is no deformity there it is certain that 2 : 1 block is not present in this case either. If the rate happened to be a little faster the hypothetical P wave might be present but hidden in the start of QRS and this would place the case among those I have classified as “no evidence.”

Fig. 17 is auricular tachycardia at two slightly different rates so that the P wave is some-

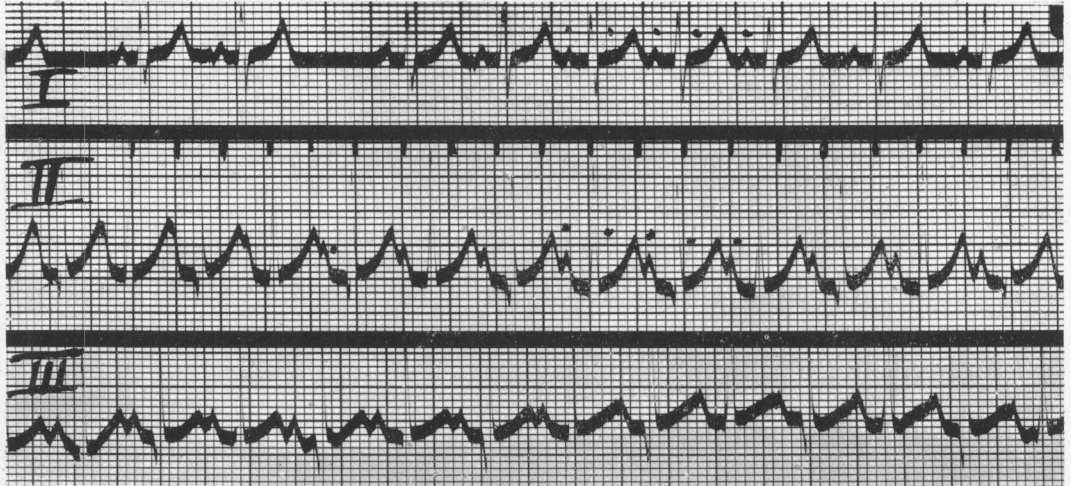


FIG. 17.—Paroxysmal auricular tachycardia without 2 : 1 A-V block. From a small child with a congenital heart (probably a ventricular septal defect with some degree of pulmonary stenosis) who had frequent paroxysms generally lasting for hours and died about a year later with pneumonia.

The spacing is such that a second upright P wave would be easily seen after QRS (as marked with dots), were it present.

times almost or quite hidden in the downstroke of the preceding T wave (rates 150 and 166). Again if a second P wave were present it should be clearly seen and could not be missed in the smooth slowly rising period shortly after S (marked with a dot).

Szekely (1944) reported some chest lead cardiograms of paroxysmal tachycardia which help to prove that 2 : 1 block is not always present (his Fig. 1 and 2A). Fig. 2A is specially conclusive because Fig. 2B shows that 2 : 1 block could occur and was easy to detect in this patient (compare my Fig. 8).

It seems, therefore, that in some records of paroxysmal tachycardia, more than one-quarter, there is, even in the standard leads, some evidence of auricular activity at twice the expected rate with 2:1 A-V block. It is, however, equally clear that in other records, nearly one-quarter, there is decisive evidence that no A-V block is present. About the remaining half it is not possible to express an opinion without further study using chest leads.

#### DISCUSSION OF EVANS' CASES

At first sight the findings of 2:1 A-V block in all of Evans' 27 consecutive cases is almost conclusive evidence that such block is present in all or nearly all cases of paroxysmal tachycardia. But examination of the cases makes this rather less certain, partly because he includes cases of flutter and partly because many of his cases are of a rather unusual type so that the series cannot be regarded as representative of paroxysmal tachycardia as a whole. Evans has kindly lent me the records of 11 of the unpublished cases so that 26 of the 27 can be discussed.

Case 6 (his Fig. 7) is certainly auricular flutter, sometimes with 2:1 and sometimes with 3:1 block. Evans agrees that by the criteria he has chosen for the selection of these cases paroxysmal flutter would be included. This also applies to his Cases 15 and 26. Case 26 is of special interest because the first record is orthodox flutter with 2:1 block (A, 218; V, 109) and the second shows a quite different picture at a rate of 217. Seeing this alone I should call it paroxysmal ventricular tachycardia; with the previous record it seems more like 1:1 flutter with bundle branch block owing to the more rapid rate. Evans regards it as 2:1 block in paroxysmal tachycardia (A, 434; V, 217) but his two auricular waves might be the first notch of the ventricular complex and a retrograde P wave on the downstroke of R: if he is correct it is hard to explain why there is 2:1 block at such different auricular rates as 434 and 218, the former showing that the ventricle is quite capable of responding at a rate of 217.

Cases 5, 9, and 14 (his Fig. 6, 11, and 14) might be regarded as flutter on the standard cardiograms. With the knowledge I have gained from Evans paper I have no difficulty in finding evidence of 2:1 block in leads I, II, or III (and actually it is clearer in III than in CR<sub>1</sub>, for Fig. 11). The first two had mitral stenosis and certainly the second had not typical paroxysmal tachycardia, but the third was a woman who was otherwise healthy, with typical paroxysmal tachycardia.

Cases 1 and 2 (his Fig. 3 and 4) have not got a regular rhythm in their attacks. Even in the standard leads of Case 1, I can now find the evidence of block but it is clearer in CR<sub>1</sub>. In Case 2, no such evidence can be found without the help of CR<sub>1</sub>. Cases 1 and 2 on the history available do not appear typical cases of paroxysmal tachycardia especially because the arrhythmia was converted to fibrillation with digitalis in each case.

This still leaves 18 cases, including 9 of those illustrated, where the cardiograms would certainly have been passed by everyone as paroxysmal tachycardia. In 11 of them the history also is of classical paroxysmal tachycardia, but in the other 7 some question might be raised: in Case 3 because "latterly the attacks had lasted for some months," in Case 4 because they occurred during a terminal heart failure with broncho-pneumonia and were changed to fibrillation with quinidine (once); in Cases 7 and 16 because the attacks only came in the terminal stages of mitral stenosis and once (in Case 7) the rhythm was changed to fibrillation by digitalis; and in Cases 18, 19, and 23 because they occurred after cardiac infarction and in Case 18 were changed to fibrillation by digitalis; Cases 19 and 23 died within a short period.

It is, of course, true that paroxysmal tachycardia may occur for the first time in the late stages of heart failure or after cardiac infarction, and may at times change to fibrillation under the influence of digitalis; but both these events are more common with auricular flutter, and therefore such cases are not the best ones for evidence of the characteristic and common behaviour of paroxysmal tachycardia.

Even so, if one is hypercritical and rules out every case where the diagnosis might be questioned on cardiographic or more doubtfully on clinical grounds there are still 11 cases of classical paroxysmal tachycardia. In all of these 11 (except perhaps in Case 22 (his Fig. 15)

and Cases 17 and 20, not illustrated, where the evidence still seems to me inconclusive) there was certainly 2 : 1 A-V block.

For comparison with my own figures I have examined Evans standard limb lead cardiograms for signs of 2 : 1 block in the 20 cases, including 11 with published cardiograms, but excluding the 6 that are or might be flutter. In 9 there seems to be no doubt that 2 : 1 block can be demonstrated (his Fig. 3, 8, 9, 10, 13, and 21, and 3 unpublished); in 11 I should still have to mark them as "no evidence": none are examples of the records that seem to me against accepting his view as the rule for all cases of paroxysmal tachycardia.

That, even now after familiarizing myself with the slighter indications of 2 : 1 block, I can only discover evidence of its presence in less than half the cases shows how essential a lead such as CR<sub>1</sub> is in assessing auricular activity in paroxysmal tachycardia.

#### OTHER CASES WITH 2 : 1 BLOCK

Most other workers who have found 2 : 1 block have reported only one or two cases and therefore do no more than prove that 2 : 1 block does occur, but two papers deal with a larger number of cases and must be considered in more detail.

Barker, Wilson, Johnston, and Wishart (1943) have reviewed 35 cases of paroxysmal auricular tachycardia with A-V block, generally 2 : 1, 18 of their own and 17 that had been reported by others. They found that these attacks differed in certain ways from ordinary paroxysmal tachycardia. The attacks lasted longer, in more than half the patients for two days or more and sometimes for 26, 60, and 94 days. The disability caused by the attacks also seemed to be greater but as this would probably be diminished by the presence of 2 : 1 block the explanation may be the longer attacks and the relatively high proportion with organic heart disease. Full doses of digitalis often restored normal rhythm and quinidine also did so but less often. Pressure on the carotid sinus, mecholyl, and acetylcholine were only successful in stopping attacks in one case.

Barker *et al.* stress the value of præcordial or œsophageal leads as in some cases the auricular deflections are small or not readily apparent in the standard limb leads. They emphasize that all the curves are quite different from those of auricular flutter, in that the auricular waves are separated by periods of electrical quiescence with the curve at rest on the base line. They conclude that paroxysmal auricular tachycardia with A-V block resembles auricular flutter in many respects but differs from it in some important particulars.

In a further paper Barker, Wilson, and Johnston (1943) discuss the arguments for circus rhythm as the mechanism of paroxysmal auricular tachycardia, but this paper is less pertinent to the present discussion: they suggest that the circus movement must have special features and this may be because its circulation path includes either the S-A or A-V node. Decherd *et al.* (1944 and 1945), however, adduced arguments against the rhythm being due to a circus movement.

Decherd, Herrmann, and Schwab (1943) have described 38 cases of paroxysmal supra-ventricular tachycardia with some degree of partial A-V block: they were selected from 102 cases of paroxysmal tachycardia and so formed a high proportion. This group of cases, as they themselves emphasize, was very unlike an ordinary group with paroxysmal tachycardia. Of the 38 cases, 55 per cent died during the period in hospital when their paroxysm with block was observed. In 35 of the 38 congestive heart failure was present before the appearance of the paroxysmal tachycardia with A-V block, 80 per cent having hypertensive or arteriosclerotic heart disease. Only 7 patients had not received digitalis and 23 had "an obvious over-dosage of digitalis." In 25 digitalis medication preceded and may have precipitated the tachycardia. Aminophylline had been given intravenously to 7 cases shortly before the attack.

Only 2 of the 38 cases had hearts that were otherwise normal and of these one had received a moderate, and the other an excessive, amount of digitalis. The ætiological factors were, therefore, very unlike that generally found in a random sample of cases of paroxysmal tachycardia. They were, in fact, nearer in many ways to the ætiological factors found with paroxysmal ventricular tachycardia. They also resembled the conditions under which partial

heart block with dropped beats occurs in patients without paroxysmal tachycardia (Campbell, 1943)—digitalis medication, sometimes in excessive doses, and infection, and often the two combined.

Decherd *et al.* emphasize that we do not possess absolute criteria for the sharp differentiation of auricular tachycardia and flutter.

Finally the 2:1 block found by Decherd *et al.* and by Barker *et al.* is of a different type from that of Evans. Evans' cases had ventricular rates that were normal for paroxysmal tachycardia and auricular rates twice as fast as this. The other reported cases had auricular rates that were normal for paroxysmal tachycardia and slower ventricular rates—generally half as fast as the auricular rate. Thus, in the cases of Barker *et al.* with 2:1 block the auricular rate averaged 189 (most cases having rates between 160 and 220) and the ventricular rate half of this. And in the cases of Decherd *et al.* the auricular rate averaged 192, and was generally between 166 and 250, and the ventricular rate was half this. In the cases of Evans, on the other hand, the ventricular rate was normal, generally between 130-250, and he suggests that the auricular rate was twice as fast as this. These data are summarized in Table II.

TABLE II  
HEART RATES IN PAROXYSMAL TACHYCARDIA

Author	Auricle	Ventricle
Barket <i>et al.</i> .. ..	160-220 (average 189)	80-110
Decherd <i>et al.</i> .. ..	166-250 (average 192)	83-125
Campbell .. ..	140-240 * (average 178)	140-240
Price (1941) .. ..	120-250 (usual 160-200)	120-250
Evans .. ..	260-500 *	130-250

On the other hand, the few cases of Brown (1936) appear to have been of the same type as those described by Evans, as he thought these were 2:1 A-V block with auricular rates of 300 and 428.

Before discussing the subject more generally, certain conclusions from a short series of cases of paroxysmal auricular flutter will be given.

PAROXYSMAL AURICULAR FLUTTER

Under the same conditions that I have collected 66 cases of paroxysmal tachycardia I have collected 17 cases of paroxysmal auricular flutter, in each instance with electrocardiographic evidence of the attack. Those cases where all the paroxysms showed an irregular rhythm simulating fibrillation and possibly some where paroxysms occurred only for a short time before flutter became established have been excluded.

The whole clinical picture of these patients is so different from paroxysmal tachycardia that even if it was proved that the underlying mechanism of both abnormal rhythms were the same or similar, some other explanation of the different clinical pictures would be needed.

Of the 17 cases, 12 were men and 5 were women. It has generally been found that flutter is more common in men, but that paroxysmal tachycardia has about the same incidence in both sexes. The age incidence was spread from 30-74, but the only two cases under 40 had rheumatic mitral disease. Even including them, the average age when the attacks started was 54 and the maximum incidence was between 55-59 years of age. The age distribution of the cases is shown below, where it is contrasted with the age incidence of paroxysmal tachycardia.

TABLE III  
AGE INCIDENCE OF PAROXYSMAL FLUTTER AND OF PAROXYSMAL TACHYCARDIA (AT ONSET)

	Up to 9	10 to 19	20 to 29	30 to 39	40 to 49	50 to 59	60 to 69	70 and over
Paroxysmal auricular flutter: number of cases .. ..	—	—	—	2	2	8	4	1
Percentage .. ..	—	—	—	12	12	46	24	6
Paroxysmal tachycardia: percentage	7	16	31	22	12	8	4	—

\* This over-simplifies the question because I agree with Evans that in some cases the true auricular rate is twice as fast as the apparent rate.

In paroxysmal flutter nearly all the cases started after 40 (88 per cent): in paroxysmal tachycardia most started before 40 (76 per cent).

There was an equally striking contrast in the ætiology. Half the cases with paroxysmal tachycardia were otherwise normal. Only three of those with paroxysmal flutter were without other evidence of heart disease and as these three were aged 55, 56, and 60 it is difficult to be sure that the hearts were really normal though the youngest of the three is still in good health 15 years later. The ætiological factors were as follows:

Congenital	..	..	1	Coronary disease	..	..	3	Chest diseases	..	..	..	3
Rheumatic	..	..	2	High blood pressure	..	..	2	Normal (aged 55, 56, and 60)	..	..	..	3
Thyrotoxic	..	..	2	Heart failure	..	..	1					

Equally striking was the difference in the length of time during which the attacks had been present before the patient came under observation. In paroxysmal tachycardia this period was often many years while in flutter it was generally not more than months or was clearly associated with some other development of the heart disease.

Only 5 of the cases had attacks that could be regarded as indistinguishable from ordinary paroxysmal tachycardia and in these they had been present for 2, 6, 9, 30, and 34 months—always less than three years. Possibly the first of these was an exception as he thought he had been cured after a year of paroxysmal tachycardia by Sir James Mackenzie, 22 years before: in the interval he had developed a blood pressure of 240/160 and had reached the age of 74.

In 4 others the attacks were generally irregular and often paroxysmal auricular fibrillation and it was only later that one or more attacks of flutter with regular A-V block were observed. The details were: paroxysms for 6 years, mostly irregular, later established auricular fibrillation; paroxysms for 4 years, nearly if not all irregular and frequently recorded as paroxysmal auricular fibrillation, good health with fewer paroxysms 12 years later; paroxysms for 5 years diagnosed as paroxysmal auricular fibrillation till a cardiogram showed auricular flutter with longish periods of regular 2 : 1 block (the irregular periods being a mixture of 2 : 1 and 1 : 1 were difficult to distinguish from fibrillation without the help of regular 2 : 1 periods); about equal numbers of paroxysms of flutter and fibrillation, both recorded, in an elderly woman with thyrotoxicosis.

In 4, the patients were already in hospital when the first attack occurred: with congestive failure; with cardiac infarction; with carcinoma of the bronchus; and with a pleural effusion. In 2 others the patient was so incapacitated by a first or by an early attack that he was taken into hospital: on the thirtieth day of a first attack with anginal pain; and on the thirty-fifth day of a third attack in a patient with angina and doubtful cardiac infarction.

In the last 2 of the 17 cases the rhythm was more like established flutter interrupted by normal rhythm: the first attack in one was stopped by quinidine after two months, and the second attack by quinidine after rather longer than this; the second had congenital pulmonary stenosis with slow flutter (A, 190; V, 95 and A, 166; V, 83) which was present as often as normal rhythm without much change in his symptoms.

Even this short account of the cases with paroxysmal auricular flutter gives a very different picture from that of a series of cases with paroxysmal tachycardia.

*The Rate.* In these 17 patients with paroxysmal auricular flutter the auricular rate varied between 170 and 376 \* a minute; but in 13 it was between 240 and 336 and in 10 between 276 and 336.\* The average rate was 290. The most usual finding was 2 : 1 block so that the ventricular rate was about half this, generally between 120 and 168. Higher degrees of block were less common though 4 : 1 block occurred with a relatively slow ventricular rate, generally in cases that were unusual in some other way also. 3 : 1 block was not seen as a persistent rhythm though it is frequently mixed with 2 : 1 or with 4 : 1 block and was observed in some of these cases when they had irregular hearts.

In Table IV, the ventricular rates in paroxysmal tachycardia and flutter are contracted and the differences are very striking; although there is much overlapping. In flutter most

\* Price (1941) gives 180–360, most commonly about 300, and Conybeare (1942) gives 260–320 as the usual limits of auricular flutter.

(83 per cent) are between 120 and 180. In paroxysmal tachycardia most (88 per cent) are between 140 and 220. Or this can be expressed in another way. If the ventricular rate is below 140, flutter is more likely (2 to 1). If the ventricular rate is between 140 and 180, paroxysmal tachycardia is more likely but paroxysmal flutter is not uncommon (3½ to 1): but if the ventricular rate is over 180, paroxysmal tachycardia is almost certain (13 to 1).

TABLE IV  
VENTRICULAR RATES IN PAROXYSMAL TACHYCARDIA AND PAROXYSMAL AURICULAR FLUTTER

	Ventricular rate							
	Below 120	120 to 139	140 to 159	160 to 179	180 to 199	200 to 219	220 to 239	240 and above
Paroxysmal tachycardia, 66 cases .. .. .	1	2	16	21	9	12	3	2
Paroxysmal flutter, 17 cases .. .. .	1	4	4	6	2	0	0	0
Paroxysmal tachycardia, percentage .. .. .	1	3	24	32	14	18	5	3
Paroxysmal flutter, percentage .. .. .	5	24	24	35	12	0	0	0

The rate of 160 is the nearest possible approach to a dividing line but it is very inexact. In half the cases of flutter (52 per cent), the rate is below 160: in three-quarters of the cases (72 per cent), of paroxysmal tachycardia, the rate is above 160, and in nearly half between 160-200.

DISCUSSION

Evans (1944) has shown clearly with chest leads that 2 : 1 A-V block often occurs in paroxysmal tachycardia, but has been overlooked.

A re-examination of older records, with standard leads only, confirms this discovery. The presence of 2 : 1 block can be found in about one-quarter of the records, but in another quarter there is good evidence against the view that it is always present. The remaining half provide no conclusive evidence, so the frequency of 2 : 1 block will have to be decided by examining further patients with chest leads.

Evans found 2 : 1 block in all of 27 consecutive cases which would suggest that it was almost, if not quite, the rule. But he included some cases of paroxysmal flutter and a proportion of his series were examples of one sub-division of paroxysmal tachycardia with serious heart disease and "terminal" paroxysms, which differs in some ways (the response to digitalis, the tendency to change to auricular fibrillation, and the frequency of 2 : 1 block) from the common type of paroxysms that often recur for years without much more significance than their inconvenience.

He also quoted the long series of cases of Barker *et al.* (1943), and of Decherd *et al.* (1943), with paroxysmal tachycardia and 2 : 1 block, but here too the authors emphasize, though from rather different points of view, that they are dealing with somewhat unusual examples of paroxysmal tachycardia.

Evans claims that the rate alone distinguishes paroxysmal tachycardia and flutter which are fundamentally the same. "Auricular flutter is paroxysmal tachycardia in which a moderate auricular rate (200-260) facilitates the finding of A-V dissociation. . . . Again, paroxysmal tachycardia is auricular flutter where the more rapid auricular rate (260-500) prejudices the recognition of the auricular waves hidden within the ventricular complexes and hinders the discovery of 2 : 1 A-V dissociation." This cannot be accepted. At rates below 130 (auricle 260, if 2 : 1 block is present), or even below 140, flutter is common and paroxysmal tachycardia is less common: with a ventricular rate above 180, paroxysmal tachycardia is common and flutter is rare. But with ventricular rates between 140-180, the percentages of each are almost the same (see Table IV) and paroxysmal tachycardia is more common only because it is a more common disorder.

It is probably true that there is no single criterion by which paroxysmal tachycardia and flutter can be distinguished. The shape of the curves denoting auricular activity is probably

the best. This shape (in leads II and III) in flutter, is often so characteristic that any student can be taught in a few minutes to recognize most cases of flutter.

It is open to question how atypical these may be and still allow the diagnosis of flutter. In the past, I (and perhaps others) have been too much influenced in such an atypical case by the presence of 2 : 1 A-V block in diagnosing flutter (see Fig. 8 and text). If there is no period on the iso-electric level and the curve rises (generally more sharply) and falls (generally less sharply) with regularity, the case should be diagnosed as flutter. If there is a period on the iso-electric level interrupted by something that may represent a normal or inverted P wave, the case should be diagnosed as paroxysmal tachycardia. No decision should be made on the presence or absence of 2 : 1 block, though this will be a more constant feature of flutter.

Evans here stressed that there are exceptions to all the points used for clinical differentiation. This is true, but it is also true of much differential diagnosis. If clinically, all or most of the points favour a diagnosis of flutter, it will generally be found that the cardiogram does also. In my opinion, the diagnosis should be made on the electrocardiogram alone and when this has been done, the following clinical points, set out in tabular form, will generally point in the same direction:

<i>Paroxysmal tachycardia</i>	<i>Paroxysmal auricular flutter</i>
Is found more often with a heart that is otherwise normal (at least 55 per cent).	Is rarely found except with a heart that is diseased.
Generally starts before the age of 40 (76 per cent).	Generally starts after the age of 40 (88 per cent).
The attacks are shorter: not often 4 days, rarely more than 10 days, and very rarely 30-40 days: it is not an established rhythm.	The attacks are longer; they may be of any length and are generally days rather than hours; it is more often an established than a paroxysmal rhythm.
It does not often change to auricular fibrillation (spontaneously or with digitalis), nor lead to established fibrillation—though any of these things may occur.	It readily changes to auricular fibrillation with digitalization, and paroxysms of fibrillation and flutter often occur in the same patient.
The ætiology is not like that of auricular fibrillation.	The ætiology is like that of auricular fibrillation.
2 : 1 or other degrees of A-V block are not readily induced by pressure on the carotid sinus or by digitalization.	2 : 1 or higher grades of A-V block are readily induced by pressure on the carotid sinus or by digitalization.
The usual ventricular rate is between 140 and 220 (88 per cent).	The usual ventricular rate is between 120 and 180 (83 per cent) or 120 and 170 (76 per cent).

#### CONCLUSIONS

Evans' demonstration of 2 : 1 A-V block in paroxysmal tachycardia has been confirmed in some cases, though not in all.

It is most easily seen and most frequently present in paroxysmal tachycardia that is relatively terminal in patients with diseased hearts, but is not confined to these cases.

The rate alone does not provide adequate grounds for distinguishing paroxysmal tachycardia and paroxysmal auricular flutter.

The clinical pictures of the two differ, but there are exceptions to each of the grounds for differential diagnosis.

The diagnosis of auricular flutter should be made on the shape of the auricular curves and the absence of an iso-electric period, regardless of whether 2 : 1 A-V block is present or absent.



The clinical diagnosis of paroxysmal tachycardia will inevitably include some cases of flutter. When cardiographic evidence is available, a distinction should be made between the following groups.

- (1) Paroxysmal auricular flutter: with regular block, most often 2 : 1; but occasionally 1 : 1 or other grades.
- (2) Paroxysmal auricular tachycardia with 2 : 1 A-V block.  
Possibly divisible into two types (a) auricular rate normal (160–250), ventricular rate half normal; certainly commoner in failing hearts after digitalization (Barker and Decherd) and (b) auricular rate twice normal (250–500), ventricular rate normal; possibly commoner in failing hearts and terminal paroxysms (Evans).
- (3) Paroxysmal auricular (or supraventricular or nodal) tachycardia without A-V block.
- (4) Paroxysmal ventricular tachycardia.

Whether paroxysmal tachycardia depends on a circus movement at some part different from the circus movement of auricular flutter or not, is still unsettled.

#### REFERENCES

- Barker, P. S., Wilson, F. N., and Johnston, F. D. (1943). *Amer. Heart J.*, **26**, 435.  
 —, —, —, and Wishart, S. W. (1943). *Ibid.*, **25**, 765.  
 Brown, W. H. (1936). *Ibid.*, **12**, 307.  
 Campbell, M., and Elliott, G. A. (1939). *Brit. Heart J.*, **1**, 123.  
 Conybeare, J. J. (1942). *Textbook of Medicine*, 6th ed., E. and S. Livingstone, Edinburgh, p. 510.  
 Decherd, G. M., and Herrmann, G. R. (1944). *Amer. Heart J.*, **28**, 457.  
 —, —, and Schwab, E. H. (1943). *Ibid.*, **26**, 446.  
 Decherd, G. M., Ruskin, A., and Herrmann, G. R. (1945). *Ibid.*, **29**, 20.  
 Evans, W. (1944). *Brit. Heart J.*, **6**, 221.  
 Price, F. W. (1941). *A Textbook of the Practice of Medicine*, 6th ed., Oxford University Press, pp. 892 and 900.  
 Szekely, P. (1944). *Brit. Heart J.*, **6**, 238.