

MYXŒDEMA WITH PERICARDIAL EFFUSION

BY

ROBERT SCHNITZER AND DAVID GUTMANN

From the Lister Emergency Hospital, Hitchin

Received September 14, 1945

There are few diseases that are so frequently mistaken in general practice as diseases of the thyroid gland. This not only applies to mild cases of thyrotoxicosis (Linnell, 1945) but also to cases of hypothyroidism and quite often even to fully developed cases of myxœdema with all its typical signs.

Just as in hyperthyroidism, in which the cardiac changes may be astonishingly small, there are instances of profound hypothyroidism with normal circulatory findings. Usually, however, the heart appears dilated to the right and to the left, and the cardiac sounds are muffled and soft. The term myxœdema heart has been applied to a condition found in about three-quarters of the cases of myxœdema (Zondek, 1918 and 1919; Fahr, 1925, 1927, and 1932; and Fournier, 1942). The myxœdema heart was described in the original report of Zondek (1918) in which he spoke of it as a clinical entity. Similar reports by Fahr, Fournier, and others, followed. Christian, and other observers, questioned the existence of such an entity and the cardiac signs were described as congestive heart failure complicating the myxœdema. It has, however, been proved that while digitalis is ineffective in those cases, treatment with adequate doses of thyroid is usually followed by a striking decrease of the size of the heart (reversible or "accordion heart"). Freeman (1934) and others found that at least part of the cardiac enlargement is due to pericardial effusion. White (1944) prints the picture of such a myxœdema heart in his text-book, showing a decrease of the transverse diameter of the heart shadow by 6 cm. as the result of successful treatment by thyroid. Considerable decrease in the size of the heart after thyroid treatment was further reported by Lehrman, Clark, and Means (1933) and by Campbell and Suzman (1934).

Cardiac involvement of a significant degree is an important sign, for it means that the grade of myxœdema is a serious one, or that other heart trouble, such as coronary or hypertensive disease, is present (White, 1944). Fahr (1925) found evidence of heart failure in 75 per cent of all his cases of myxœdema, 30 per cent of them showing rather severe signs and symptoms. While thyroid treatment relieved the signs and symptoms rather promptly, digitalis was found to be of doubtful value. He found many cases of myxœdema heart complicated by arteriosclerosis of the coronary vessels, and thyroid was found to be contra-indicated because the coronary flow may decrease at the same time as the power of the heart increases. The elevation of metabolism by thyroid therapy may induce symptoms of coronary insufficiency and attacks of angina pectoris may develop (White, 1944). In that case it is recommended to discontinue, or at least to reduce, the dosage of thyroid. According to White, congestive failure as a cause of death in myxœdema is very rare. The exact cause of the cardiac enlargement responsible for the term myxœdema heart is still a matter of dispute. It was thought to be the result partly of dilatation, partly of myxœdematous swelling and permeation of the myocardium by œdema, comparable to the alteration of the skin, and sometimes of an excess of fluid in the pericardium. While all these factors seem to play a role in the development of the myxœdema heart, recent observations seem to indicate that a pericardial effusion is generally present. Clear evidence of this was found in the case under discussion where a diagnostic paracentesis of the pericardial cavity revealed a pericardial effusion and 60 c.c. of straw-coloured fluid were aspirated. Similar results have lately been reported by a number of American observers but whether or not this effusion alone is responsible for all clinical signs is still uncertain. Tatum (1912) found pericardial effusion in thyroidectomised animals and Goldberg (1927) performed thyroidectomies on sheep and goats.

Two years later at autopsy he found the presence of pericardial effusion. The heart was pale and flabby and sections showed disintegration of heart muscle fibres.

Another interesting observation in myxœdema, and particularly in myxœdema heart with pericardial effusion, is the typical change of the cardiogram and the return of the tracing to normal after thyroid administration. In myxœdema the cardiogram is often characterized by an extremely low voltage curve. All the deflections are very small and inversion or absence of the T wave is not rarely found. Cutaneous alterations were at one time thought to be responsible for these changes. Recent investigations, however, tend to refute this assumption. Hallock (1933, 1934) found no abnormality in cardiograms of cases of generalized scleroderma and generalized ichthyosis. According to other observers the abnormal cardiogram and the cardiac enlargement of myxœdema results from myxœdematous swelling of the myocardial fibres. Adequate treatment with thyroid is usually followed by a striking improvement of the cardiogram. This too, was proved in the case under discussion. Since a reduction in the size of all waves of the cardiogram (low voltage) with occasionally inverted T wave in all leads is often found with effusion in the pericardial cavity, it may be difficult, if not impossible, to decide in a case of myxœdema heart whether the abnormal tracing is due to the myxœdema *per se*, or perhaps to a co-existing pericardial effusion. The alterations of the cardiogram in pericardial effusion are ascribed to the short circuiting of the action currents by the mantle of liquid which surrounds the heart so that only small potentials are intercepted at the surface of the body. The same alterations can be experimentally produced by the injection of normal salt solution into the pericardial cavity; such an artificial effusion can only be very small since a normal pericardium cannot be stretched. The low voltage tracing vanishes when the effusion is removed by therapeutic measures (Scherf and Boyd, 1945). To be sure the changes in the cardiogram in pericardial effusion are not invariably found, as in some cases the heart may not be entirely surrounded by fluid, and in some areas the heart may be adherent to the pericardium and to the surrounding tissues. An interesting cardiographic distinction between massive pericardial effusion and marked cardiac enlargement without effusion, has recently been suggested by Tung (1941): the duration of the electric systole (Q-T interval) is normal in the former and prolonged in the latter (White, 1944).

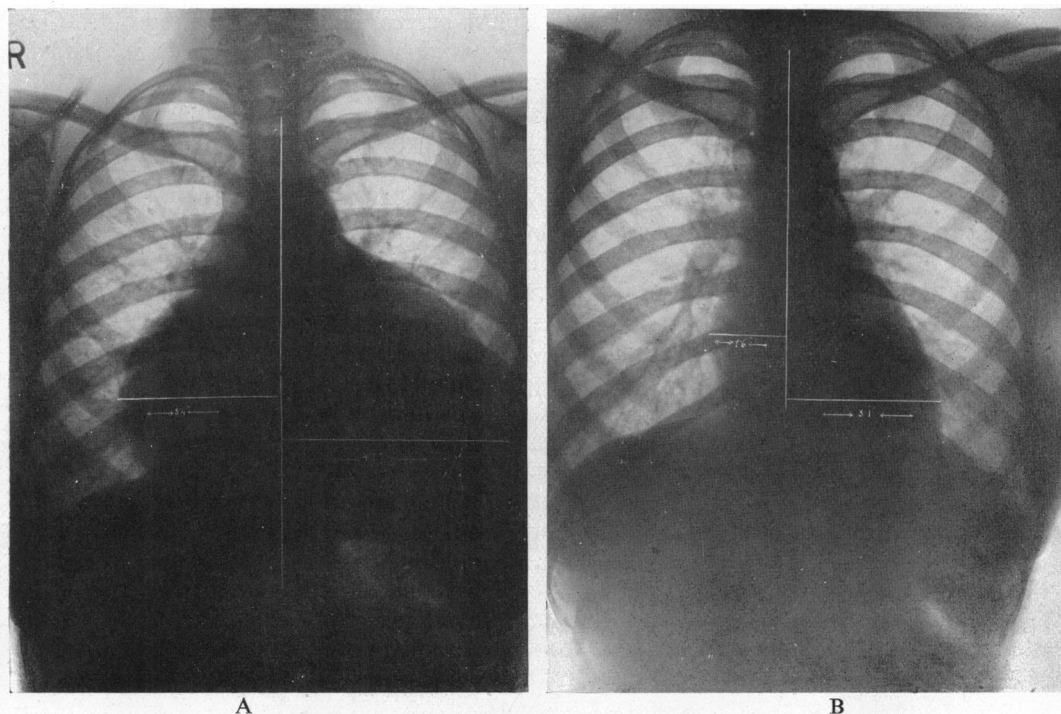


FIG. 1.—Teleradiograms of the heart before and after treatment.

(A) Before treatment, maximum transverse diameter 20.6 cm. (B) After treatment, maximum transverse diameter 12.0 cm.

Since no positive histological evidence proving the existence of a myxœdematous alteration of the myocardium has been obtained so far, the similarity of the cardiograms in pericardial effusion and in myxœdema could find its explanation in an abnormality common to both, that is, the effusion. It is therefore possible that a pericardial effusion existed in many, perhaps in all cases described under the term myxœdema heart.

CASE REPORT

Miss A., aged 30 years, was admitted to hospital in January, 1945. For the last six months she had complained of dyspnœa on slight exertion, swelling of the ankles, puffiness of the face with swelling under the eyes, clumsiness of the hands, and loss of energy. She had put on a considerable amount of weight during the last few months and it was noticed that her speech became slow and slurred, although the patient herself was not aware of this.

On examination the temperature was subnormal, the respiration rate 20, and the weight 10 stone. Sallow pallor of skin which was dry and scaly, particularly on arms and legs, cyanosis over malar prominences, dry and brittle hair with some loss of outer third of eyebrows, puffy eyelids with narrow lid-slits, forehead slightly wrinkled, voice hoarse, speech slow and slurred, slow reactions, and slightly retarded cerebration. Cardiac dullness greatly increased to right and left. Cardiac impulse not visible. Apex beat displaced outwards and downwards, as judged by the intensity of the heart sounds, within the area of cardiac dullness. Heart sounds soft and distant, no thrill nor murmurs. Pulse 60 a minute, small, regular, and equal. Blood pressure 105/70. Abdomen rather prominent and flabby, but no evidence of fluid made out. Nothing abnormal palpable. No œdema.

The diagnosis of myxœdema with myxœdema heart was made.

X-Ray of heart on admission showed gross cardiac enlargement to the right and to the left, the maximum transverse diameter being 20.6 cm. (Fig. 1A). The electrocardiogram showed a low voltage curve and complete absence of P and T wave in all leads (Fig. 2A). Paracentesis of the pericardial cavity revealed the presence of a pericardial effusion. The needle was inserted in the fifth left intercostal space four and a half inches from the sternal border, and 60 c.c. of clear, straw-coloured fluid were aspirated. Plasma cholesterol 305 mg. per 100 c.c. Hæmoglobin 64 per cent. Red blood cells 3,230,000 per cub. mm. Colour index 0.98. White blood cells 5700 per cub. mm. Erythrocyte sedimentation rate 38 mm. in 1 hour (Westergren). Wassermann negative. The basal metabolic rate was not estimated

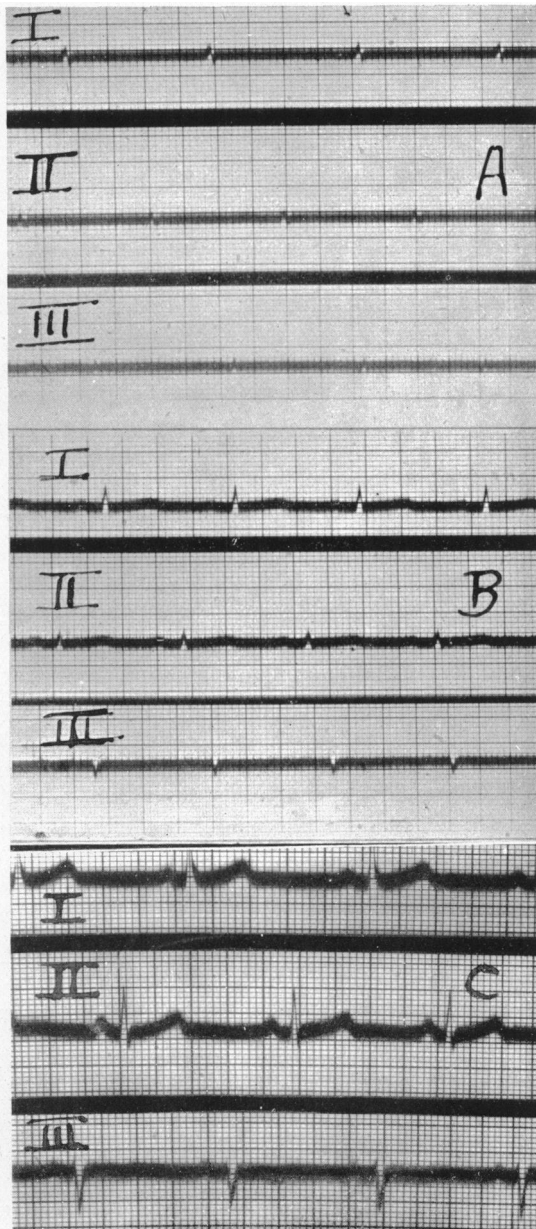


FIG. 2.—Electrocardiograms before and after treatment. (A) On admission, with extremely low voltage of all excursions. (B) After two months treatment with thyroid, showing increasing, but still low, voltage. (C) On discharge, showing return to normal, with left axis deviation.

as no apparatus was available and the progress of the case was ascertained by monthly estimations of the plasma cholesterol.

Treatment and Progress. A trial dosage of thyroid, $\frac{1}{2}$ grain b.i.d., was given for a week. It was then increased to 1 grain t.i.d., as no unfavourable reactions were observed. On this dosage the patient was kept for the next ten weeks when thyroid was reduced to $\frac{1}{2}$ grain b.i.d. as a maintenance dose. She was also having fersolate tablets.

A series of radiograms of the heart showed a steady decrease in the size and the final one, after four and a half months of treatment with thyroid, showed a total decrease of the transverse diameter of the heart shadow by 8.6 cm. (Fig. 1B). The electrocardiogram became normal with all deflections well defined (Fig. 2 B and C), but there was now evidence of left ventricular preponderance. Blood pressure 120/85. Plasma cholesterol 185 mg. per 100 c.c. Hæmoglobin 94 per cent. Erythrocytes sedimentation rate 10 mm. in 1 hour. The raised erythrocyte sedimentation rate before treatment was probably due to the associated anæmia.

The patient was extremely fit on discharge, all the signs and symptoms of myxœdema had subsided, and she had lost 22 pounds within three months. She was advised to continue with the maintenance dose of $\frac{1}{2}$ grain of thyroid, twice a day.

SUMMARY AND CONCLUSIONS

Some of the reported cases of pericardial effusion in myxœdema heart are reviewed, and the typical changes in the size of the heart and in the cardiogram are discussed.

A case of advanced myxœdema with gross enlargement of the heart in a woman of 30 years of age is recorded. Pericardial paracentesis revealed a pericardial effusion. The transverse diameter of the heart shadow before treatment was 20.6 cm. and after four and a half months of treatment with thyroid it decreased to 12 cm., showing a total decrease of 8.6 cm.

An initial low voltage curve of the cardiogram with absence of T wave in all limb leads was restored to normal after treatment, but there was evidence of left ventricular preponderance.

A trial dose of thyroid, $\frac{1}{2}$ grain b.i.d., was given and as no unfavourable effect was observed this dose was increased to 1 grain t.i.d., and was finally reduced to $\frac{1}{2}$ grain b.i.d. as the maintenance dose.

The similarity of the electrocardiograms in cases of pericardial effusion and in cases of myxœdema, suggests a common abnormality which may be the presence of fluid in both disorders. This would then support the opinion that a pericardial effusion exists in many, if not in all cases described as myxœdema heart.

We have to thank Dr. P. J. W. Mills, Medical Superintendent, for his kind permission to publish this case, and Dr. John Parkinson and Dr. J. W. Linnell for their interest and encouragement in the preparation of this paper. Our thanks are also due to Dr. Cornelius Papp for supplying us with some of the references, and to Dr. Cedric Hilliard, Radiologist, and his technical staff for their kind co-operation.

REFERENCES

- Campbell, M., and Suzman, S. S. (1934). *Guy's Hosp. Rep.* **84**, 281.
 Carns, M. L., and Lee, H. J. (1936). *Wisconsin med. J.*, **35**, 33.
 Christian, H. A. (1925). *Rhode Island med. J.*, **8**, 109.
 Davis, J. C. (1931). *Ann. intern. Med.*, **4**, 733.
 Fahr, G. (1925). *J. Amer. med. Ass.*, **84**, 345.
 — (1932). *Amer. Heart J.*, **8**, 91.
 Feasby, W. R. (1940). *Ibid.*, **19**, 749.
 Fournier, J. C. M. (1942). *Proc. Staff Meetings Mayo Clinic*, **17**, 212.
 Freeman, E. B. (1934). *Amer. intern. Med.*, **7**, 1070.
 Gant, J. C. (1935). *New England J. Med.*, **213**, 918.
 Goldberg, S. A. (1927). *Quart. J. Exper. Physiol.*, **17**, 15–30.
 Hallock, P. (1933–1934). *Amer. Heart J.*, **9**, 196.
 Harrell, G. T., and Johnson, C. (1943). *Ibid.*, **25**, 505.
 Holzman, J. E. (1929). *Ibid.*, **4**, 351.
 Lehrman, J., Clark, R. J., and Means, J. H. (1933–34). *Ann. intern. Med.*, **6**, 1251; **8**, 82.
 Linnell, J. W. (1945). *The Practitioner*, March, 138.
 Ohler, W. R., and Abramson, J. (1934). *Arch. intern. Med.*, **53**, 165.
 Scherf, D. (1930). *Wien. Klin. Wschr.*, **43**, 298.
 —, and Boyd, L. J. (1943). *Cardiovascular Diseases, their Diagnosis and Treatment*, 2nd ed., 165 and 252.
 —, — (1945). *Clinical Electrocardiography*, p. 44.
 Tung, C. L. (1941). *Amer. Heart J.*, **22**, 35.
 White, P. D. (1944). *Heart Disease*, 3rd edit., pp. 419 and 650.
 Zondek, H. (1918). *Münch. med. Wschr.*, **65**, 1180.
 — (1919). *Ibid.*, **66**, 681.