

CONGENITAL AORTIC ANEURYSM WITH VALVULAR STENOSIS AND DISSECTING ANEURYSM

BY

C. P. PETCH

Medial necrosis of the aorta is often associated with dissecting aneurysms that occur early in life. In the case described this defect was combined with a true aneurysm and aortic valvular stenosis.

Case Report

A man of 35 was admitted to hospital with a presumptive diagnosis of coronary thrombosis. He had been found to have a cardiac murmur at the age of five, but his activities had never been restricted. There was no history of rheumatism or syphilis. The abnormality of his heart had been noticed again during his service in the Army, and had resulted in his being downgraded from category A1 to C3. After returning to civil life he had continued work in an office without illness until the day before his admission to hospital. On that day his first symptom had been a sense of tightness in the chest, which gradually developed into a severe substernal pain spreading to both shoulders. It was continuous, worse on breathing and on movement, and made him sweat profusely. He did not vomit or feel short of breath.

On admission his temperature was 101° F.; pulse regular at 110; blood pressure 100/80. His heart was observed to be enlarged to the left and a pericardial friction rub was heard. There were no signs of cardiac failure and the other systems were normal. Arachnodactyly was not found. The next morning the pericardial friction had gone, and a harsh basal systolic murmur with a soft blowing diastolic was audible. At the apex there was a systolic murmur but no diastolic. An electrocardiogram (Fig. 1) was chiefly remarkable for the elevation of the S-T segment in leads I, II, V4 and V6, with preservation of the R wave in the præcordial leads; it was regarded as being compatible with acute pericarditis. White blood cells at this time numbered 9200, 76 per cent being polymorphs. During the next five days the pain decreased and the fever subsided gradually to normal. On the fifth day he died without warning.

Necropsy report. A large hæmopericardium was found. The ascending aorta was the site of a thin-walled aneurysm about the size of a grapefruit which had ruptured by a horizontal split

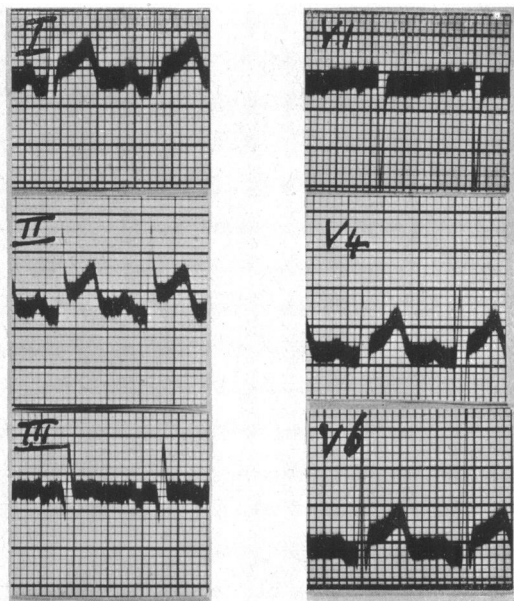


FIG. 1.—Electrocardiogram showing elevation of S-T segments in leads I, II, V4 and V6.

7 cm. long between 5 and 7 cm. above the valve (Fig. 2). Dissection between the coats of the aorta had occurred downwards to the pericardium but not to any extent upwards, and the true aneurysm rather than the dissection was the striking feature. The intima was quite smooth. The aortic valve was stenosed, admitting only one finger. The two posterior cusps were fused, and the whole

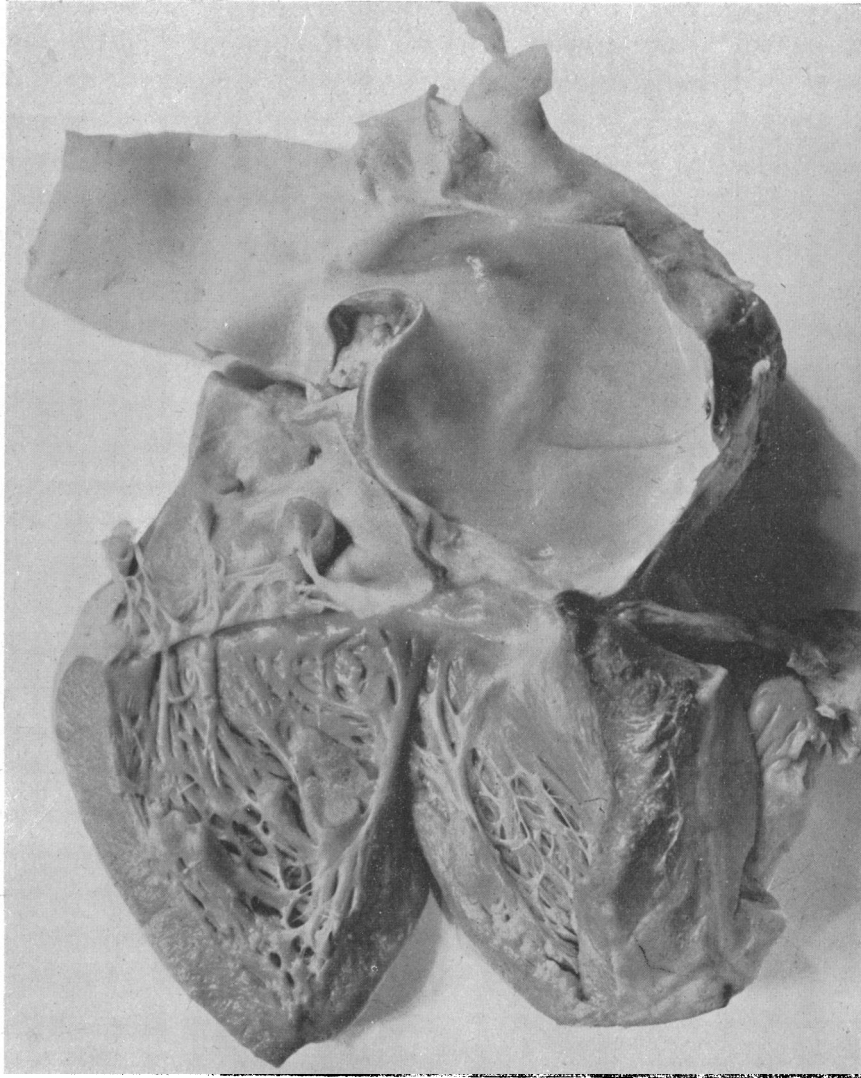


FIG. 2.—The left ventricle and ascending aorta opened; the split appears as a horizontal line in the intima. ($\times 3/5$ natural size.)

structure was calcified and incompetent. There was a slight narrowing of the lumen of the aorta in the region of the ductus, which was closed, but true coarctation was absent. No other significant abnormality was found, the coronary arteries being patent, the myocardium healthy, and the cardiac septa intact. On microscopy, sections of the aorta showed mucoid degenerative changes and fragmentation of elastic fibres in the media.

Comment

Schnikter and Bayer (1944) collected 141 cases of ruptured dissecting aneurysm of the aorta under the age of 40, and drew attention to the frequent association of other defects. Cystic medial necrosis was held to be the underlying abnormality. A congenital narrowing of the aorta in the region of the isthmus was found in 32 per cent, but aortic valvular stenosis was described only once. These authors also referred to the liability of these subjects to rheumatic heart disease, though in the present case the early recognition of the murmur may indicate a congenital valvular lesion. Saccular aneurysm of the ascending aorta was not found in this series, but Baer *et al.* (1943) described two cases in which such an aneurysm was found in this site and was considered congenital. Again, the condition of the media was thought to be the cause. These aneurysms did not rupture or dissect but the patients died young, at the ages of 13 and 26. Both had arachnodactyly, cardiac hypertrophy, and other defects. Reynolds (1950) has also discussed the association of aortic aneurysms and dissecting aneurysms with arachnodactyly. The present case had the same typical changes in the media, but differed from both groups in its subsequent progress, in that a saccular aneurysm was formed that ruptured to cause death.

Summary

Rupture of a congenital saccular aneurysm of the aorta at the age of 35 is described. Medial necrosis was found; the aortic valve was stenosed.

I am indebted to Dr. T. Goodier for the post-mortem examination and to Dr. W. G. Millar for the photograph.

REFERENCES

- Baer, R. W., Taussig, H. B., and Oppenheimer, E. H. (1943). *Bull. Johns Hopkins Hosp.*, **72**, 309.
Reynolds, G. (1950). *Guy's Hosp. Rep.*, **99**, 178.
Schnikter, M. A., and Bayer, C. A. (1944). *Ann. intern. Med.*, **20**, 486.