

CASE REPORTS

A CASE OF ENDOCARDIAL FIBROSIS SHOWING HEPARIN-RESISTANCE

BY

ANEURIN HUGHES AND G. HARVEY SMITH

From the Department of Medicine, University of St. Andrews

Endocardial fibrosis has recently been reviewed by Gray (1951) and in a *Lancet* annotation (1952). The myocardial lesions of this disease are very similar to those following arsenical dermatitis (Brown and McNamara, 1940), scarlatina, and sulphur ointment dermatitis (Brody and Smith, 1936), thus suggesting allergy as an aetiological factor. Abrahams *et al.* (1949, 1951) demonstrated heparin-resistance in rheumatic fever—a disease widely regarded as allergic in origin. In the case reported here a similar resistance to the action of heparin was demonstrated; furthermore, aortic hypoplasia and eosinophilia were absent, and connection with the tropics so remote as probably to be of no significance. Pulmonary infarctions were believed to follow thrombosis in the pulmonary arterial tree rather than embolism.

Case Report

A married man, aged 54, railway porter, was admitted to the Professorial Medical Unit, Maryfield Hospital, Dundee, on 16/8/51. Following a clinical episode of myocardial infarction in 1949, he had been breathless and able to perform only light work. Two weeks before admission, when at rest, he first felt pain over the left lower ribs in front, but spreading occasionally across the chest. It began gradually and was accompanied by breathlessness which increased in severity until on admission he was dyspnoeic at rest.

Past history. Apart from service in Macedonia in the 1914–18 war he had not been in tropical or sub-tropical countries. He had then contracted malaria (1916)—a single attack with no relapses.

Examination on admission. The temperature was 100.5° F., the pulse 110 a minute, respiration 24 a minute. He was cyanosed and orthopnoeic, with raised venous pressure, liver enlargement, and oedema. The blood pressure was 118/80. Frequent extrasystoles were present. There was cardiac enlargement, the apex beat being tapping in quality and situated 3.7 cm. outside the mid-clavicular line. No murmurs were heard but the second sound was widely split in all areas. Crepitations were present at both lung bases.

Blood. E.S.R. 20 mm. in 1 hr. (Westergren). Hb. 104 per cent (14.4 g. per 100 ml.), R.B.C. 4 million and W.B.C. 12,000 per cu. mm.; differential white count normal—no eosinophilia. W.R. negative. Blood cultures (broth) negative on four occasions.

Cardiogram on 21/8/51 showed a right axis deviation and a vertical heart, abnormal P waves in leads II and VI, P–R interval of 0.2 sec., QRS of 0.12 sec., low voltage T waves, and a pathological Q wave in V5 suggesting an old anterolateral infarct (Fig. 1A).

Chest X-ray showed generalized cardiac enlargement with cardiothoracic ratio of 72 per cent and pulmonary congestion.

The *urine* was chemically and microscopically normal.

Progress

Intramuscular heparin administration was begun on admission and continued for seven days. Prolongation of clotting times (by Lee and White's method) did not follow the usual therapeutic doses. For example, on the first day at 6 p.m. the clotting time was 4 minutes; 25,000 units of heparin were then injected; at 9.15 p.m. the clotting time was only 5 minutes and at 6.30 a.m. on the next morning, it was 5½ minutes. Again, on the third day 25,000 units of heparin at midnight was followed by a clotting time of only 6 minutes at 6.30 a.m., while on the sixth day, following the same dose at midnight, the 6.30 a.m. clotting time was only 8½ minutes, which was the longest time recorded. Tromexan was then given for five weeks. In spite of adequate reduction in prothrombin levels (between 10 and 30% throughout), four further attacks of chest pain occurred accompanied on each occasion by blood in the sputum. These episodes suggested repeated pulmonary infarctions. On 1/10/51 heparin therapy was started again and on this occasion a normal response was obtained. For example, with a control clotting time before heparin of 8 minutes,

12,500 units intra-muscularly produced clotting times of 22 and 32 minutes, 4 and 8 hours respectively after the injection. Thereafter, for seven days, the clotting times were easily maintained between 18 and 56 minutes by daily doses not exceeding 25,000 units. In spite of this, another myocardial infarction occurred on 4/10/51; the electrocardiogram was confirmatory, showing S-T shift in V3 and further prolongation of the P-R interval (Fig. 1B).

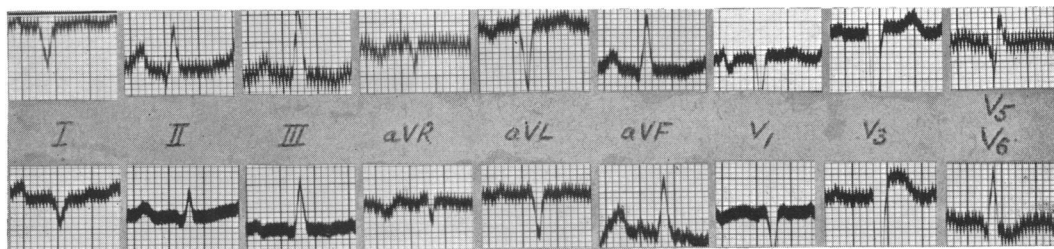

FIG. 1.—(A) Electrocardiogram on 21/8/51 showing evidence of the anterolateral infarction. (B) Record on 4/10/51 showing evidence of further myocardial infarction.

Low-grade pyrexia in association with the attacks of chest pain did not respond to chemotherapy and antibiotics. Œdema increased in spite of administration of digitalis, squill, low-sodium diet, kation exchange resin, and mercurial diuretics, until eventually it required drainage. The congestive failure was intractable, and in this way the patient's condition gradually and progressively deteriorated until death occurred on 18/11/51, three months after admission to the ward.

Post-mortem Examination

The heart was enlarged and globular and weighed 616 g. Diffuse fibrosis throughout the myocardium was most pronounced in the sub-endocardial zone. A fairly recent infarction of the anteroseptal wall of the left ventricle and two older infarctions of the posterior wall were present (Fig. 2). Although gross atheroma

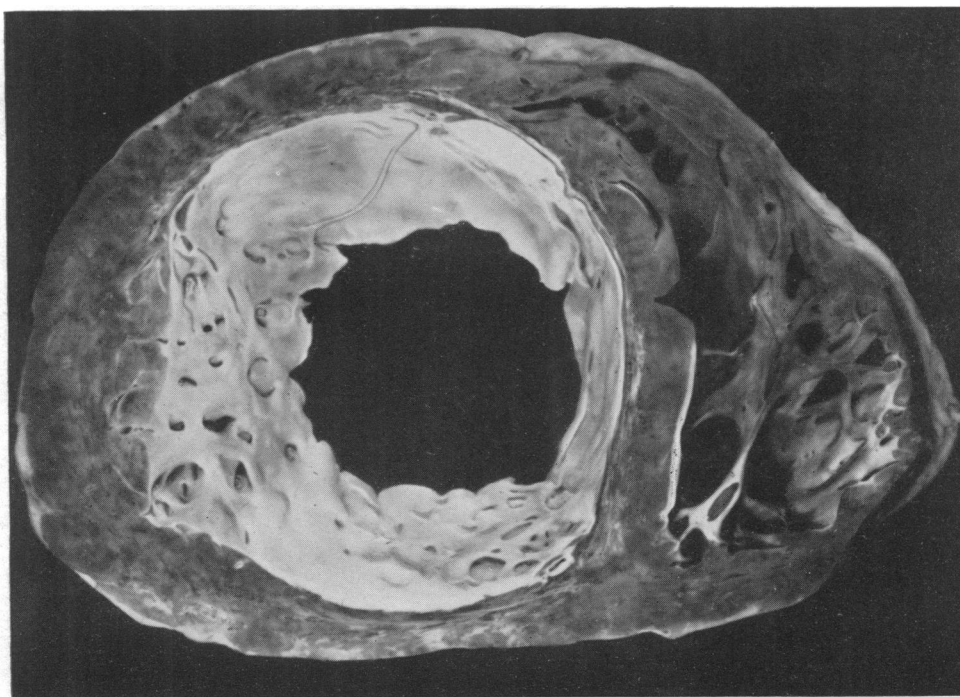


FIG. 2.—Transverse section of heart viewed from above showing interior of left and right ventricles and endocardial fibrosis.

of the coronary arteries was found, there was no evidence of thrombosis in the branches. All four heart chambers contained organizing mural thrombi; the endocardium of the left auricle and ventricle was very thick (2.0 mm.), white and opaque. Similar changes were present in much less degree in the cavities of the right side of the heart. The tricuspid valve was normal; atheromatous deposits were seen on the pulmonary valve and in the pulmonary trunk. The cusps of the mitral valve were thickened and opaque and this thickening extended along the chordæ tendineæ to the papillary muscles. The aortic valve was competent but showed several warty deposits upon the ventricular aspect of its mitral cusp. The aorta was normally developed and showed no evidence of hypoplasia. Microscopic examination of the left ventricle showed gross fibrous thickening of the endocardium and fibrous replacement of muscle. The latter was most pronounced in the sub-endocardial region except for a band of muscle tissue which seemed to have escaped destruction. Generally, the myocardium showed irregular bands of fibrous tissue spreading for varying distances between muscle bundles and in places compressing them. This gross increase in connective tissue together with patchy lymphocytic infiltration resembled a chronic inflammatory process (Fig. 3). The areas of infarction showed the usual appearances, compatible with the age of the lesion.

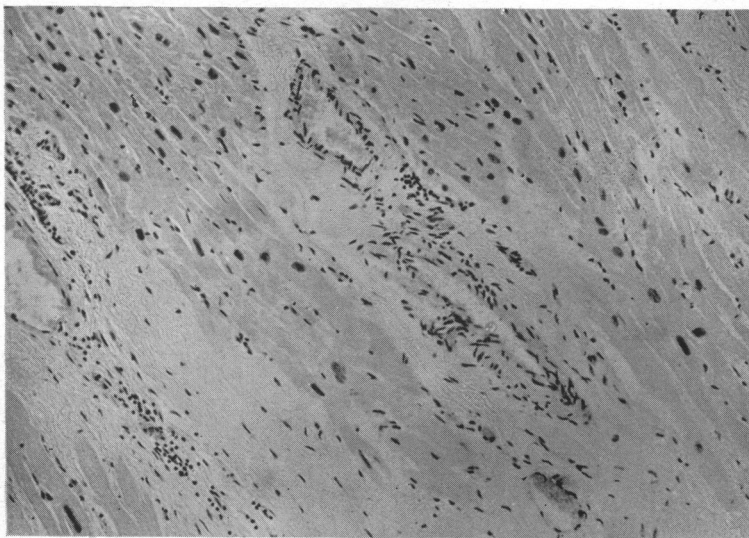


FIG. 3.—Section of the left ventricular myocardium showing interstitial fibrous replacement of muscle and areas of lymphocytic infiltration.

Both lungs contained multiple infarcts of varying size, some old and in various stages of organization, others recent and hæmorrhagic. One very large hæmorrhagic infarction was present in the posterior part of the right upper lobe, apparently caused by thrombosis of a large branch of the pulmonary artery. The pulmonary arterial tree was grossly atheromatous and there was no doubt that some of the infarcts were due to antemortem intra-arterial thrombosis and were not of embolic origin.

Summary

A case of endocardial fibrosis showing heparin-resistance and some other features is reported. Necropsy showed infarctions in the heart and in the lungs. In the latter situation they were believed to be due to thrombosis in the pulmonary arterial branches.

We are grateful to Professor Ian G. W. Hill for his invaluable help and advice.

REFERENCES

- Abrahams, D. G., and Glynn, L. E. (1949). *Clin. Science*, **8**, 171.
 —, —, and Loewi, G. (1951). *Clin. Science*, **10**, 1.
 Brody, H., and Smith, L. W. (1936). *Amer. J. Path.*, **12**, 373.
 Brown, C. E., and McNamara, D. H. (1940). *Arch. Dem. Syph.*, **42**, 312.
 Gray, I. R. (1951). *Brit. Heart J.*, **13**, 387.
Lancet Annotation (1952). **1**, 90.