

EBSTEIN'S ANOMALY :  
REPORT OF A CASE DIAGNOSED DURING LIFE

BY

A. J. KERWIN

*From the Department of Medicine, the Toronto Western Hospital and the University of Toronto\**

The congenital malformation and displacement of the tricuspid valve described by Ebstein nearly a century ago is rare; less than 50 cases have been reported, many of them recently. Yater and Shapiro (1937) considered a clinical diagnosis to be impossible, but Engle *et al.* (1950) indicated the criteria for such a diagnosis: briefly these were gross enlargement of the right heart with decreased pulsation, decreased vascularity of the lungs, right bundle branch block, and delayed A-V conduction. Cardiac catheterization was regarded as a useful aid by Reynolds (1950) and by Broadbent *et al.* (1953). Soloff *et al.* (1951) made the diagnosis chiefly on the angiocardiogram. Blacket *et al.* (1952) reported 5 cases in one of which "the diagnosis has been confirmed at autopsy," but it is not clear whether the diagnosis was definite or on what evidence it was made before the fatal catheterization.

*Case Report*

In the present case the diagnosis was made during life and was confirmed post mortem eleven weeks later.

An 18-year-old man was referred for cardiac investigation. No detailed history of his early life was available. The patient led a normal active life except that extreme effort would result in dyspnoea and fatigue. Exercise such as swimming produced cyanosis but usually his colour was ruddier than that of the average person.

His height was 5 feet 5 inches and weight 120 lb. and his muscle and chest development were normal. His cheeks, lips, and ears were unusually florid and there was no cyanosis. A systolic murmur was heard with maximum intensity in the third and fourth left interspaces near the sternum and was propagated to the apex and base. The heart rate was 70 a minute and regular in rhythm and the blood pressure was 126/80. Clubbing of fingers and toes was absent. Physical examination was otherwise essentially normal.

The electrocardiogram showed low voltage in the limb leads and the QRS duration was 0.16 sec. The chest leads were remarkable. V3R and V1 showed a deep fast Q and a slow late R indicating right bundle branch block. Between V1 and V2 there was an abrupt change to a small R and tall R1 followed by a slightly negative and then a positive peaked T wave. In the V4 position the T wave became deeply negative. At V5 there was another abrupt change, the QRS decreasing greatly and becoming tent-shaped. At V6 an early tall R wave was followed by a slow wide S wave. The P-R interval was 0.17 sec. and the P vector pointed upward and to the left in the frontal plane. In leads I and V1 the P was broad and slightly notched. The cardiogram was interpreted as showing chiefly right ventricular events as far to the left as the V4 position. Position V5 was probably just to the right of the transition zone, while V6 was the first position to show left ventricular events.

X-ray report (Fig. 1) (Dr. L. R. Harnick): "The heart is globular in shape and is enlarged with a cardiothoracic ratio of 17.5 to 29 cm. There is a striking avascularity of the lung fields and the hilar vessels as well as the pulmonary trunk are greatly reduced in size. The arch of the aorta is small but probably normal. In the lateral film there is marked enlargement anteriorly, the appearance being consistent with right ventricular enlargement."

On cardiac catheterization, the right atrium seemed very large; a ventricular type of pressure curve was not obtained until the tip of the catheter was far to the left of the mid line and nearly to the left border of

\* This investigation was supported by a grant from the National Research Council of Canada.

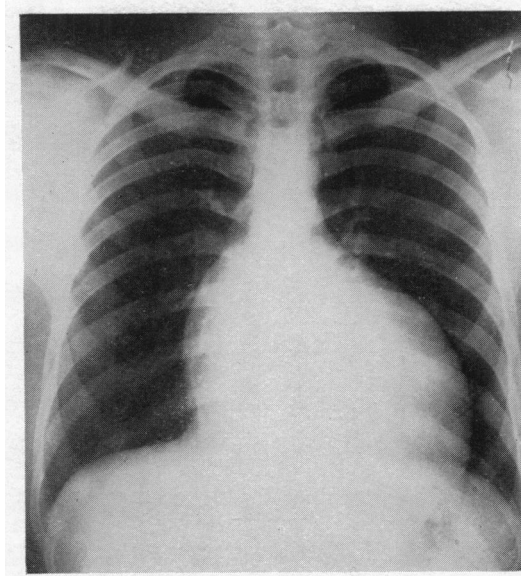


FIG. 1.—Roentgenogram of the heart in the postero-anterior view. Note the marked decrease in the vascularity of the lung fields.

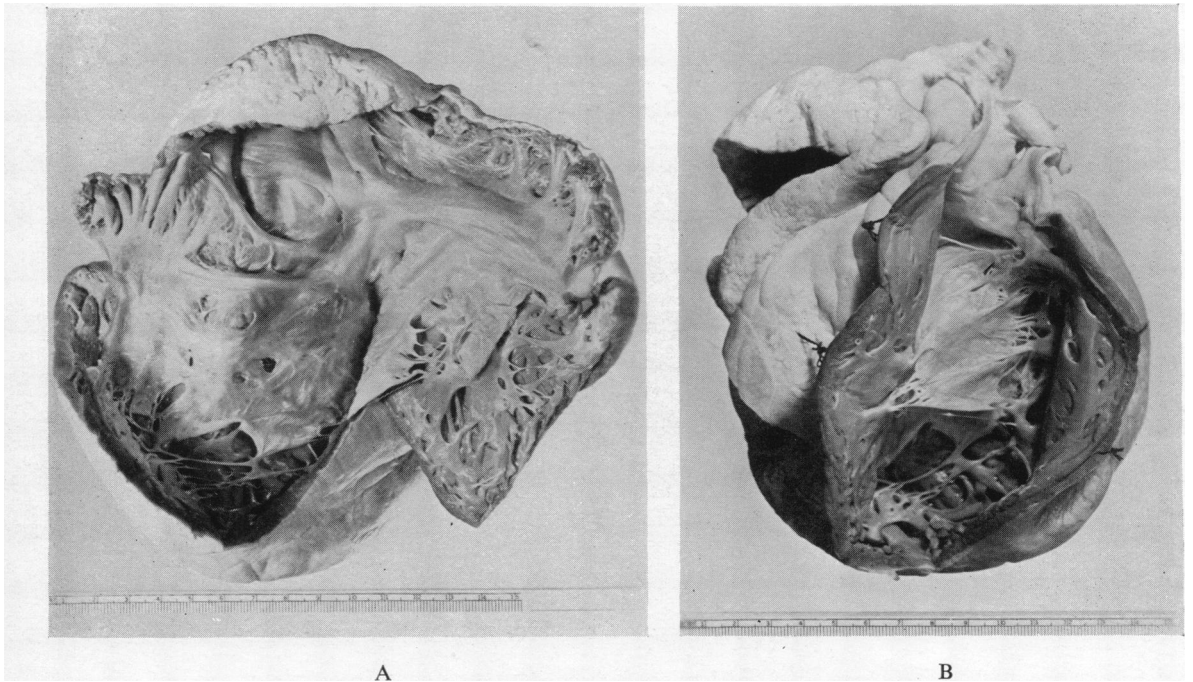


FIG. 2.—(A) Heart opened to show the right atrium and the large membranous sheet of the tricuspid valve attached to the wall of the right ventricle. (B) Heart opened to show the outflow tract and pulmonary valve, as well as the tricuspid malformation.

the heart. The catheter could not be made to turn up into the pulmonary artery. The pressure in the right ventricle was slightly raised (32/6 mm. Hg) as were also those of the right atrium (16/10 mm.), the superior vena cava (20/11 mm.) and the inferior vena cava (16/10 mm.). There was no evidence of an arterio-venous shunt, the oxygen saturations in the right ventricle, right atrium, superior and inferior venæ cavæ being 13·7, 14·4, 13·7, and 14·2 vol. per cent respectively. The moderate femoral artery unsaturation (86%) was attributed to a veno-arterial shunt which was wrongly thought to be through a small atrial septal defect although the catheter had not been passed into the left atrium. On the basis of the very large right atrium, the apparent displacement of the tricuspid valve to the left, and the avascularity of the lung fields, a diagnosis of Ebstein's anomaly was made.

Eleven weeks later after swimming about half a mile, he died suddenly.

*Autopsy Report* (Dr. W. S. Alexander). Upon opening the chest cavity there was very extensive dilatation of the heart so that the heart itself occupied more than half of the thoracic cavity. This was due entirely to tremendous dilatation of the right auricle and ventricle. The weight of the formalin fixed heart was 400 g.

Examination of the right atrium (Fig. 2A) showed extreme dilatation, both of the atrium and auricular appendix with muscle hypertrophy of the walls of both chambers. The muscle showed extensive trabeculation. The tricuspid valve structure was grossly abnormal. Instead of a recognizable tricuspid valve, there was a membranous sheet encircling the A-V orifice. This sheet was attached to the A-V ring in a somewhat irregular fashion, but the major abnormality was at its free margin, which was attached by a number of strong thin tendinous cords to the wall of the ventricle quite close to the apical region, so that the valve substance lay as a drape from the A-V orifice almost to the apex of the very greatly dilated right ventricle. There were numerous perforations of this drape, both close to its point of attachment at the base and at the apex.

The right ventricle was grossly hypertrophied and extremely dilated (Fig. 2B). The hypertrophy involved not only the wall of the heart but the columnæ carneæ and the hypertrophied columns extending up behind the fixed valve substance. The wall of the right ventricle proximal to the insertions of the tricuspid valve measured between 7 and 8 mm. in thickness while that of the distal portion, the outflow tract, varied from 4 to 5 mm. There was no free communication between the cavity of the ventricle and pulmonary artery since the valve drape covered the region of the infundibulum. There was moderate dilatation behind the infundibulum and it would appear that much of the blood that escaped from the pulmonary artery reached the infundibulum through the perforations of the sheet of fibrous tissue. The pulmonary valve itself showed no evidence of stenosis. The pulmonary artery was smaller than average size. The ductus arteriosus was well closed.

In comparison with the huge right atrium and grossly dilated appendix, the left atrium was a tiny chamber and the appendix was a very small structure projecting from the surface of the heart. The mitral valve was normal in appearance and led to a left ventricle which, in comparison with the grossly dilated right, was a small structure. The thickness of the muscle, however, was within normal limits for his age and development. The aortic valves were normal in appearance. The aorta itself, however, was smaller than usual and the diameter was considerably reduced. The coronary vessels showed an apparently normal pattern and appearance.

Examination of the interatrial septum showed no evidence of a septal defect. The interventricular septum showed in the region of the pars membranacea septi a pouch, the orifice of which presented on the left ventricular surface of the septum while the pouch itself projected into the right ventricle behind the fibrous sheet of the tricuspid valve. As far as could be determined on gross inspection, there was no perforation of this structure. The ventricular surface on the right side, however, was grossly irregular with thick and thin areas alternating.

The rest of the autopsies showed nothing of significance.

#### *Discussion*

The pathology and abnormal physiology of this condition have been discussed at some length by Engle *et al.* (1950), Baker *et al.* (1950), Blacket *et al.* (1952), Broadbent *et al.* (1953), and Edwards *et al.* (1953) and will not be detailed here. There is one point worthy of note. Engle *et al.* (1950) remarked that, "Thinness of the right ventricular wall proximal to the valve has been noted in nearly all the recorded cases," and in each of their three cases this condition obtained. In the only autopsied case among the five seen by Blacket *et al.* (1952) the muscle of both the proximal and distal portions of the right ventricle was thin but "very similar." Engle *et al.* (1950) postulated that some defect of the visceral coelomic wall destined

to give rise to the right ventricular myocardium might account for the maldevelopment of the muscle and the malformation of the tricuspid valve. However, Edwards (1953) pointed out that one of his cases failed to show atrophy, perhaps because the patient was only two months old. He suggested the possibility that the atrophy might be secondary to the altered dynamics.

In the present case, the wall of the proximal portion of ventricle was thicker than normal while that of the distal portion was slightly if at all increased. This fact would indicate that a visceral cœlomic defect is not an integral part of the deformity. Presumably an unusual degree of tricuspid stenosis would account for the proximal hypertrophy. In this case the altered dynamics were not such as to produce atrophy even over a period of 18 years. It is none the less clear that the output of the right heart was subnormal as indicated by the decreased vascularity of the lung fields.

A noteworthy feature of the pressures at catheterization is the tendency for these to be about the same in the right ventricle and right atrium as shown by Broadbent *et al.* (1953). Perhaps this is due to some degree of tricuspid regurgitation though signs of right-sided passive congestion are usually lacking. The present case failed to show this tendency to equalization of the pressures in the atrium and ventricle. No doubt the variability in the type of deformity produces abnormalities in the dynamics that differ considerably from case to case.

Practically all cases show right bundle branch block and some have prolonged A-V conduction as well. These findings have been attributed by Engle *et al.* (1950) to the dilatation and thinning of the right atrium and proximal right ventricle. This explanation is scarcely tenable in this patient who showed hypertrophy of both these chambers as well as an extreme degree of right bundle branch block.

Two authors (Blacket *et al.* and Campbell) have reported sudden death occurring during catheterization, and in another case it happened during the induction of anæsthesia before thoracotomy (Broadbent *et al.*, 1950). This so far unexplained hazard may be related either to anæsthesia or to the trauma of catheterization, possibly through the production of an arrhythmia. Sudden death occurred in the present case apparently as a result of physical effort. Because of the liability to unexpected death, cardiac catheterization should in most cases be avoided, since the clinical diagnosis can now be made with reasonable assurance, chiefly on the basis of the X-ray appearance.

#### Summary

A case of Ebstein's anomaly is reported in which the diagnosis was made during life and confirmed post mortem. The diagnosis was based on the X-ray appearance and the very large size of the right atrium at catheterization. The pressure differences between the right atrium and ventricle were well marked, unlike some cases reported in which the two pressures were similar.

Anatomically this case was also different in that the musculature of the right atrium and proximal right ventricle was hypertrophied and not atrophied as is usually the case. There was no atrial septal defect though this is commonly present in Ebstein's anomaly.

It is emphasized that sudden unexpected death occurs during anæsthesia, catheterization, or exercise in these patients. Catheterization should be done only if the clinical diagnosis is in doubt. A reasonably accurate clinical diagnosis can be made on the radiological and the electrocardiographic findings, and is important because no surgical treatment can be offered at present and exploration may be dangerous.

I am indebted to Dr. M. Israels and Dr. Gordon Murray for permission to publish this case, to Dr. W. S. Alexander for the autopsy report, and to Dr. J. D. Stephen for making the specimen available for examination.

#### REFERENCES

- Baker, C., Brinton, W. D., and Channell, G. D. (1950). *Guy's Hosp. Rep.*, **99**, 247.  
 Blacket, R. B., Sinclair-Smith, B. C., Palmer, A. J., Halliday, J. H., and Maddox, J. K. (1952). *Austral. Ann. Med.*, **1**, 26.  
 Broadbent, J. C., Wood, E. H., Burchell, H. B., and Parker, R. L. (1953). *Proc. Mayo Clin.*, **28**, 79.  
 Campbell, M. (1953). Editorial Note in Henderson *et al.* (1953).  
 Edwards, J. E. (1953). *Proc. Mayo Clin.*, **28**, 89.  
 Engle, M. A., Payne, T. P. B., Bruins, C., and Taussig, H. B. (1950). *Circulation*, **1**, 1246.  
 Gøtzsche, H., and Falholt, W. (1954). *Amer. Heart J.*, **47**, 587.  
 Henderson, C. B., Jackson, F., and Swan, W. G. A. (1953). *Brit. Heart J.*, **15**, 360.  
 Reynolds, G. (1950). *Guy's Hosp. Rep.*, **99**, 276.  
 Soloff, L., Stauffer, H. M., and Zatuchni, J. (1951). *Amer. J. med. Sci.*, **222**, 554.  
 Yater, W. M., and Shapiro, M. J. (1937). *Ann. intern. Med.*, **11**, 1043.