

Decalcification of a choroidal osteoma

Susan N Trimble, Howard Schatz

Abstract

A 56-year-old man presented with a clearly defined orange tumour in the posterior pole of his left eye. A choroidal osteoma was suspected, and ultrasonography confirmed the diagnosis. Fluorescein angiography demonstrated subretinal neovascularisation on the nasal edge of the tumour, which was treated with krypton laser photocoagulation twice. Recurrent subretinal neovascularisation occurred one year later and was not amenable to treatment. Three years after the patient first presented, thinning of the tumour was noted on follow-up examination. During the next 15 months the tumour completely disappeared, leaving an area of retinal pigment epithelial and choroidal atrophy. Total decalcification of the choroidal osteoma was demonstrated by ultrasonography.

Choroidal osteomas are juxtapapillary choroidal lesions which contain bone, and have been recognised since 1978.^{1,2} We report a second case of choroidal osteoma which gradually disappeared after laser treatment for subretinal neovascularisation.³ In both cases decalcification occurred, leaving an area of atrophic retinal pigment epithelium and choriocapillaris.

Case report

In June 1982, a 56-year-old white male was seen in consultation with a three- or four-week history of distorted vision in his left eye. The history was negative except for past thyroid cancer in 1955. A thyroid resection was done initially, and metastatic rib cage tumours were removed in 1963. When he presented to us, his visual acuity was 20/20 in the right eye and 20/50 in the left eye. A well defined, slightly elevated mass was seen in the posterior pole of the left eye. The mass was orange centrally and was yellow-white where the retinal pigment epithelium was thinned along

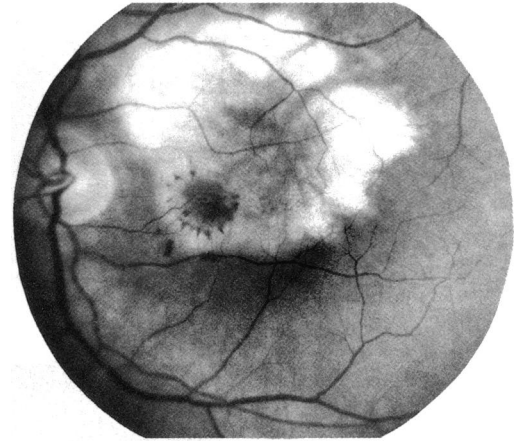


Figure 1B Red-free photograph left macula. Note the choroidal osteoma in the upper part of the macula. There is a patch of subretinal neovascularisation in the papillomacular bundle adjacent to the fovea. Note a few spots of subretinal haemorrhage.

the margin (Fig 1A). Fluorescein angiography demonstrated the tumour and subretinal neovascularisation located nasal to the left fovea (Figs 1 B-D). On the ultrasonogram there was very high reflectivity and extreme acoustic shadowing of orbital fat behind the globe consistent with the diagnosis of choroidal osteoma.

The subretinal neovascularisation was treated with krypton laser photocoagulation. Two months later the patient's vision dropped from 20/40 to 8/200, and recurrent subretinal neovascularisation was again treated with laser. His vision did not improve, though the macula remained dry for the next year. In August 1983 there was a new haemorrhage with serous detachment in the macula, and recurrent subretinal neovascularisation was defined on the fluorescein angiogram (Figs 2, A-C). Since then his vision has remained 3/200.

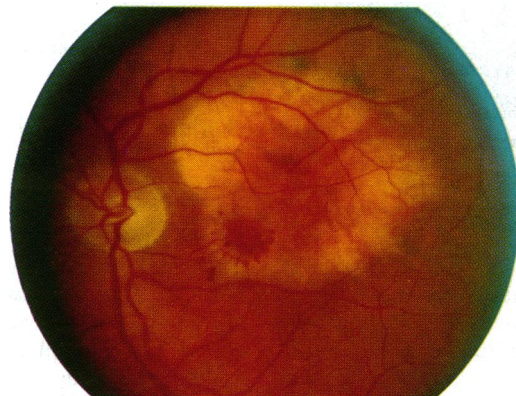


Figure 1A June 1982. Well defined choroidal osteoma with reddish centre and yellow-white edge. Note subretinal neovascularisation at inferior nasal edge of tumour.

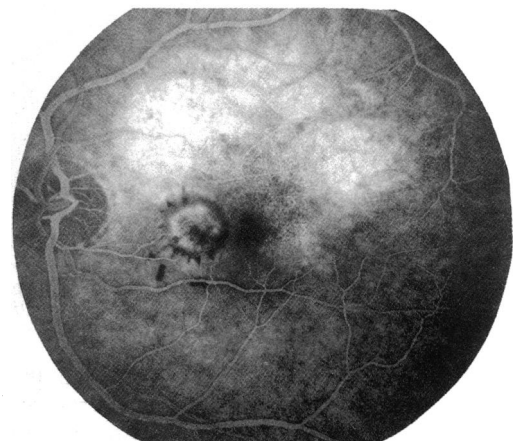

Figure 1C Midphase angiogram showing moderate fluorescence from the choroidal osteoma as well as hyperfluorescence from the ring of subretinal neovascularisation nasal to the fovea. The haemorrhage hypofluoresces.

Department of
Ophthalmology, Loyola
University Medical
Center, Maywood,
Illinois, USA
S N Trimble

Retina Research Fund,
St Mary's Hospital and
Medical Center, and
Department of
Ophthalmology,
University of California,
San Francisco, USA
H Schatz

Correspondence to:
Howard Schatz, MD, 1 Daniel
Burnham Court, San
Francisco, CA 94109, USA.

Accepted for publication
18 July 1990

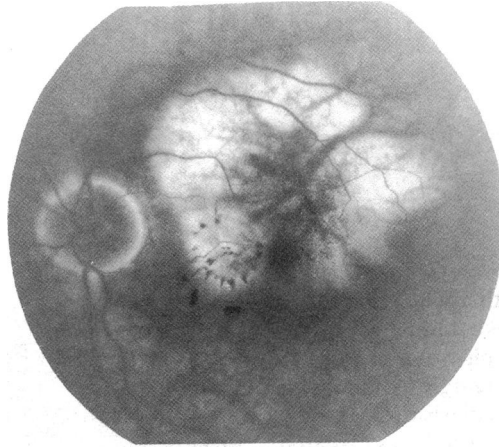


Figure 1D Late phase fluorescein angiogram shows that the choroidal osteoma stains and there is leakage into the subretinal space from the patch of subretinal neovascularisation.

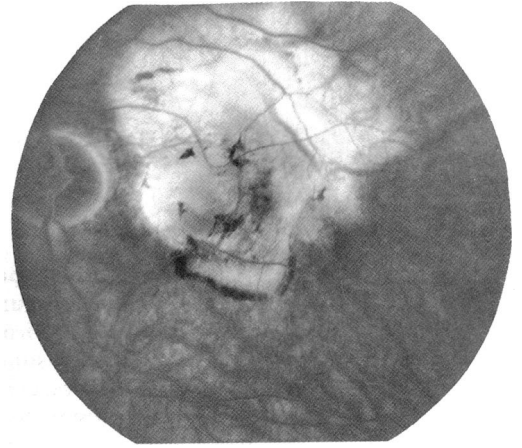


Figure 2C Late phase angiogram shows leakage from the patch of subretinal neovascularisation below and staining of the choroidal osteoma and previous laser treatment.

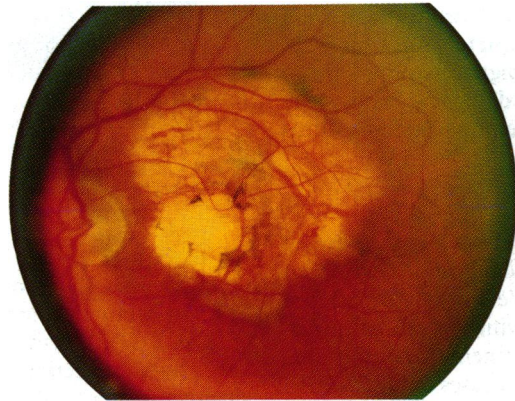


Figure 2A Fourteen months later. The patch of subretinal neovascularisation has been treated, and there is an atrophic scar in the papillomacular bundle. The subretinal neovascularisation has recurred just below the fovea. The choroidal osteoma appears thinner with visualisation of choroidal vessels.

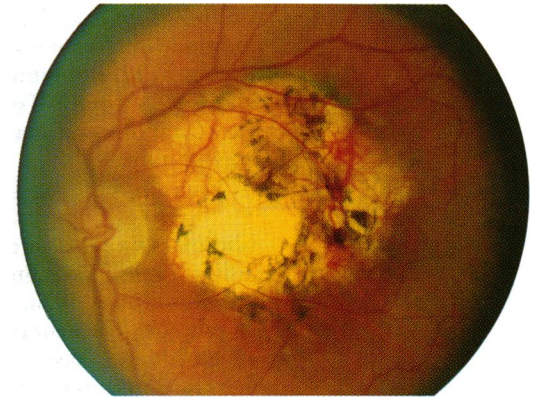


Figure 3 July 1986 Complete decalcification of the choroidal osteoma has occurred leaving an area of pigment epithelial and choroidal atrophy. Clumps of pigment are seen.

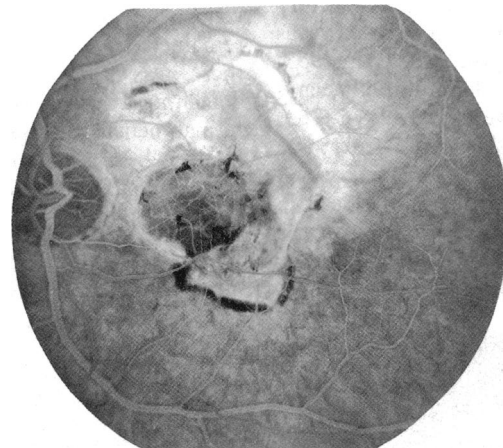


Figure 2B Midphase angiograms showing hyperfluorescence from the patch of subretinal neovascularisation below the macula with a surrounding ring of subretinal haemorrhage (hypofluorescent ring), atrophy from the previous laser nasal to the fovea, and thinning of the choroidal osteoma above.

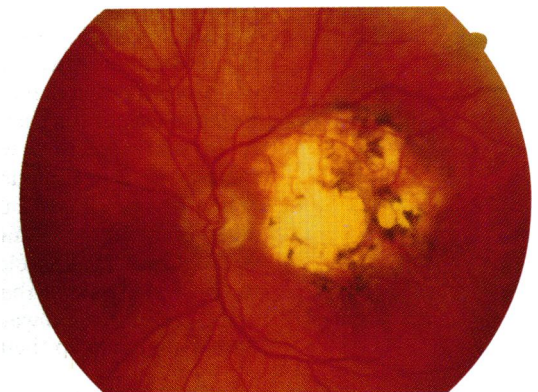


Figure 4A September 1988. Additional chorioretinal atrophy has occurred since July 1986.

chorioretinal atrophy at the tumour site (Figs 4A-D).

Discussion

Choroidal osteomas are yellow-white or orange, peripapillary lesions with discrete, well defined borders. They are seen most often in young white, healthy females. The aetiology is not known, but one factor may be intraocular inflammation. They have been found in eyes with associated inflammatory diseases.⁴⁻⁶ We have reported a case of an osteoma that developed

In April 1985 the tumour appeared to be thinning, and retinal pigment epithelial atrophy was noted. Ultrasonography still showed calcification. Fifteen months later the pigment epithelium was more atrophic (Fig 3), and total decalcification was confirmed by ultrasonography. Examination in 1988 revealed additional

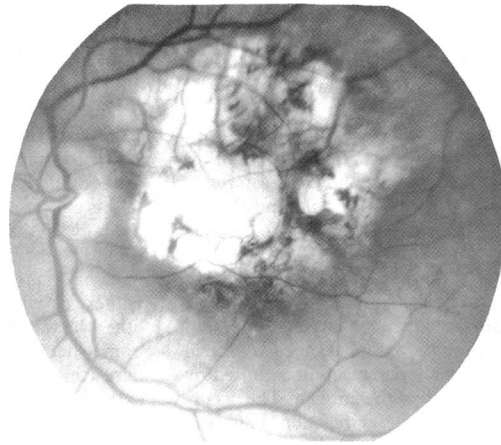


Figure 4B Red-free photograph. Atrophic areas are seen at the previous tumour site. There is thinning and loss of retinal pigment epithelium and choroid with scattered pigment clumping.

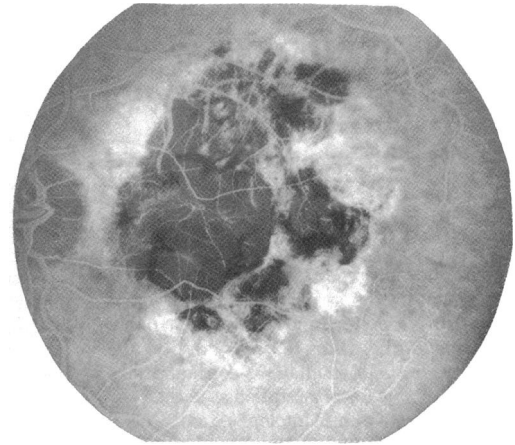


Figure 4C Mid-phase angiography shows hypofluorescence in the areas of chorioretinal atrophy. In the surrounding retina is hyperfluorescence due to visualisation of choriocapillaris where overlying retinal pigment epithelium is defective.

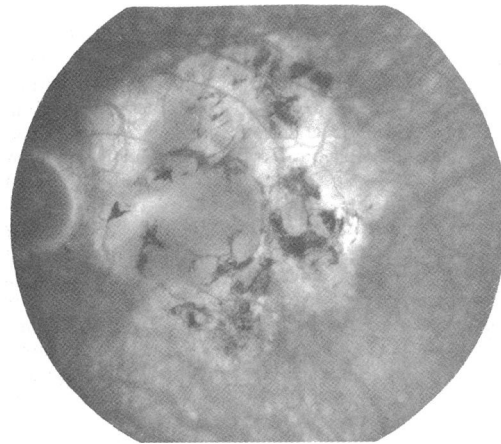


Figure 4D Late stage angiogram shows hyperfluorescence from scleral staining. Pigment clumps are hypofluorescent.

at a site where focal choroiditis had occurred five years previously.⁷

Unexpected decalcification and disappearance of a choroidal osteoma was observed and first reported by us in 1988.³ In that case a 23-year-old woman had a choroidal osteoma confirmed by ultrasonography and orbital tomography. Over five years it grew slowly. Subretinal neovascularisation developed and was treated with argon laser photocoagulation. Gradual thinning and tumour decalcification followed. Eighteen months later complete decalcification and atrophy had occurred. At that time a bed of pigment epithelial and choriocapillaris atrophy remained. Disappearance of the choroidal osteoma and loss of calcium was confirmed by fluorescein angiography and ultrasonography.

A second case is reported here in a 56-year-old man. The development of parafoveal subretinal neovascularisation occurred in both patients and

was treated with laser photocoagulation. Whether this factor is of any significance in the subsequent disappearance of the tumour is unknown.

Resorption of bone is initiated when there is osteoclast formation adjacent to bone. Osteoclasts are multinucleated cells formed by the fusion of mononuclear precursors. In addition mononuclear phagocytic inflammatory cells (monocytes and macrophages) may participate in resorption of normal or pathological bone.

Reporting this second case is important because the phenomenon of decalcification and disappearance of choroidal osteomas could be part of the natural course of the disease. Since choroidal osteomas were first identified in 1978, most cases have been followed up for a decade or less. Another factor in both our cases is that each had laser treatment for subretinal neovascularisation. Perhaps a cascade of osteoclast activity was initiated after it which led to the disappearance of the osteoma. In a patient who presents with a well defined area of chorioretinal atrophy in the posterior pole a decalcified choroidal osteoma should be considered in the differential diagnosis.

- 1 Williams AT, Font RL, VanDyk HJL, Riekhof FT. Osseous choristoma of the choroid simulating a choroidal melanoma. *Arch Ophthalmol* 1978; **96**: 1874-7.
- 2 Gass JDM, Guerry RK, Jack RL, Haris G. Choroidal osteoma. *Arch Ophthalmol* 1978; **96**: 428-35.
- 3 Trimble SN, Schatz H, Schneider GB. Spontaneous decalcification of a choroidal osteoma. *Ophthalmology* 1988; **95**: 631-4.
- 4 Kline LB, Skalka HW, Davidson JD, Wilmes FJ. Bilateral choroidal osteomas associated with fatal systemic illness. *Am J Ophthalmol* 1982; **93**: 192-97.
- 5 Gass JDM. *Stereoscopic atlas of macular diseases*. 3rd ed. St. Louis: 1987: **1**: 152, 153, 180.
- 6 Katz RS, Gass JDM. Multiple choroidal osteomas developing in association with recurrent orbital inflammatory pseudotumour. *Arch Ophthalmol* 1983; **101**: 1724-7.
- 7 Trimble SN, Schatz H. Choroidal osteoma after intraocular inflammation. *Am J Ophthalmol* 1982; **96**: 759-64.