

Behçet's disease: activated T lymphocytes in retinal perivasculitis

David G Charteris, Caroline Champ, A Ralph Rosenthal, Susan L Lightman

Abstract

A 38-year-old man who died from systemic Behçet's disease had previously suffered from severe, recurrent bilateral retinal vasculitis, and anterior uveitis for 10 years. Immunopathological examination of the eyes postmortem revealed marked hyaline thickening of the retinal and optic nerve vessels. The vessels had an intramural and perivascular infiltrate of T lymphocytes which stained positively for CD4 and IL2 receptor surface markers. Small numbers of cells in the optic nerve head, retinal vascular endothelium, and retinal pigment epithelium were HLA DR positive.

(*Br J Ophthalmol* 1992; 76: 499-501)

Behçet's disease is a multisystem inflammatory disorder mediated by an occlusive vasculitis.¹ The disease is characterised by aphthous mouth ulcers, genital ulcers, and ocular inflammation. Ocular manifestations of Behçet's disease, which occur in 70-85% of cases, are a recurrent iridocyclitis, retinal vasculitis, and retinal ischaemia. These frequently lead to cystoid macular oedema and optic atrophy resulting in profound visual loss.

Alterations in complement components in aqueous humour² and peripheral blood^{3,4} led to the theory that immune complex deposition caused the immunopathology in Behçet's disease. Studies of tissues involved in the disease process⁵⁻⁸ have however shown that it is predominantly T lymphocytes which infiltrate the affected tissues. This suggests a central role for cell-mediated immunity in the disease process.

Histopathological examination of enucleated eyes from patients with Behçet's disease reveals a non-granulomatous uveitis, retinal vasculitis, and infarction.^{9,10} This paper documents the findings of a pathological and immunohistochemical study on eyes obtained postmortem from a patient who died from Behçet's disease.

Case report

A 29-year-old man was diagnosed as having Behçet's disease in 1981 on the basis of a 3 year history of recurrent retinal vasculitis, anterior uveitis, and oropharyngeal aphthous ulcers. These manifestations were controlled initially by high dose oral prednisolone. Between 1985 and 1990 his systemic condition deteriorated with the development of erythema nodosum, multiple joint symptoms, and meningoencephalitis which resulted in epilepsy. Treatment with chlorambucil, cyclosporin, cyclophosphamide, and azathioprine failed to halt the progression of the disease. The patient died in October 1990 from pneumonia secondary to raised intracranial pressure due to central nervous system involvement which failed to respond to treatment.

From 1981 until his death he had recurrent episodes of anterior uveitis (with hypopyon) and retinal vasculitis in both eyes. This resulted in retinal ischaemia and visual loss despite systemic immunosuppression and orbital steroid injections. A dense cataract developed in the left eye early in the disease process, but cataract extraction was not considered justified because of the advanced retinal ischaemia. At his last ophthalmic review 3 months prior to death he had no light perception in either eye. The right optic disc was swollen and surrounded by multiple retinal haemorrhages and retinal oedema (Fig 1). The retinal vessels in the right eye were sheathed. There was no view of the left fundus due to the lens opacity. Anterior uveitis was minimal in both eyes. Intraocular pressures were normal throughout the course of the disease. Immunosuppressive treatment at the time of death was high dose systemic prednisolone, azathioprine, and cyclophosphamide.

Materials and methods

Consent was obtained for full postmortem examination including examination of the eyes. Both eyes were removed, the right globe was fixed in 4% glutaraldehyde and the left globe was frozen in OCT (Shandon, Runcorn). Horizontal sections, through the pupil and optic nerve, of both globes were cut at 6 µm thickness. Initial staining was carried out using haematoxylin and eosin. Sections of the frozen (left) eye were stained immunohistochemically using the avidin-biotin-complex (ABC) method (Vector, Peterborough). Briefly, slides were fixed in acetone, endogenous peroxidase activity quenched and blocked using normal serum. Primary monoclonal antibodies (Table 1) were applied for 30 minutes at appropriate concentration, biotinylated secondary antibody and ABC complex were subsequently applied following washing in phosphate-buffered saline.

Department of Clinical Science, Institute of Ophthalmology, 17-25 Cayton Street, London EC1V 9AT
D G Charteris
S L Lightman

Leicester Royal Infirmary, Leicester LE2 7LX
C Champ
A R Rosenthal

Correspondence to: Mr D G Charteris, Manchester Royal Eye Hospital, Oxford Road, Manchester M13 9WH.

Accepted for publication 10 February 1992

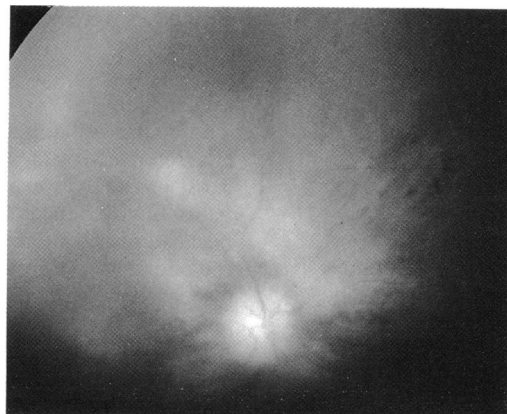
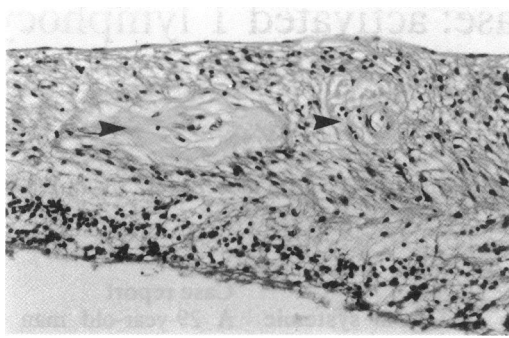


Figure 1 Right optic fundus 3 months prior to death. The optic disc is oedematous with surrounding retinal haemorrhages and patches of retinal oedema.

Figure 2 Disorganised, detached retina of the left eye showing marked hyaline thickening and luminal narrowing of retinal vessels (arrowheads) with intramural inflammatory infiltration. *H and E* $\times 140$.



Slides were then developed in amino ethyl carbazole to give a red final reaction product and counterstained in haematoxylin.

CONTROLS

Sections of each level examined were stained immunohistochemically as above with the omission of the primary monoclonal antibody to provide negative controls. Frozen sections from a normal eye were stained with each monoclonal antibody to demonstrate the distribution of each cell type in uninflamed ocular tissue. Known positive tissues (inflammatory eyelid or orbital lesions) were stained simultaneously using each primary monoclonal antibody to verify the effectiveness of the staining procedure.

Results

Pathological examination of the brain revealed widespread cerebral oedema with gyral flattening but no evidence of coning. Histologically, there was no active cerebral vasculitis.

The pathological appearances were similar in the right and left eyes. There was a mild lymphocytic infiltrate of the iris and ciliary body; this extended into the choroid where there were scattered lymphocytes in all sections examined. The retinas showing loss of ganglion cells and

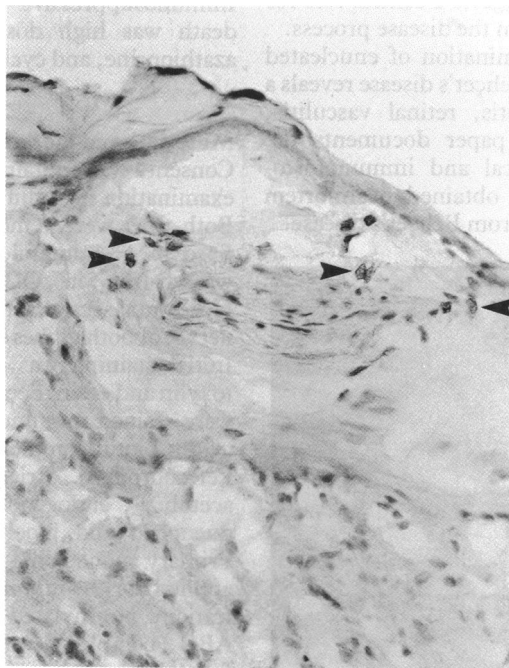


Table 1 Primary monoclonal antibodies

| Antibody | Source | Specificity |
|----------|--------|---------------------------|
| T3 | Dako* | Pan T lymphocytes |
| T4 | Dako | CD4+ T lymphocytes |
| T8 | Dako | CD8+ T lymphocytes |
| L 26 | Dako | B lymphocytes |
| IL2R | Dako | Interleukin 2 receptor |
| MAC 3 | Dako | Monocytes/macrophages |
| HLA DR | Dako | HLA DR antigen expression |

*High Wycombe, UK

photoreceptors. The retinal vessels were patent but showed marked hyaline thickening of their walls (Fig 2). There were infiltrating lymphocytes within this hyaline tissues. The retinas were focally detached with underlying patches of subretinal fluid. In the right eye the optic nerve head was oedematous and there was a lymphocytic perivasculitis of the central retinal vessels extending into the nerve. The left optic nerve head was not oedematous but had a perivasculitis. Both optic nerves had moderate loss of neural tissue.

Positive immunohistochemical staining for T lymphocytes was seen in cells in the retinal vessel walls and surrounding the optic nerve head vessels (Fig 3). These cells also stained positively with the CD4 monoclonal antibody; however the small number of cells present precluded counts of T cell subset ratios. The perivascular T cells also stained positively with the IL2 receptor monoclonal antibody. Lymphocytes in the iris, ciliary body, and choroid were also positive for the T lymphocyte monoclonal antibody although they were generally IL2 receptor negative. No CD8+ T lymphocytes or B lymphocytes were found. A few cells in the hyalinised vessel walls were positive for the macrophage primary antibody. No neutrophils were identified in the vasculitic lesions.

A small number of stromal cells of fibroblastic morphology in the optic nerve head and retinal vascular endothelial cells were HLA DR positive. There were also numerous HLA DR positive cells in the retinal pigment epithelium.

CONTROLS

There was minimal background staining in sections where the primary antibody was omitted. In the normal eye there were very occasional cells in the choroid which were positive for the T lymphocyte and CD4 monoclonal antibodies. There were also small numbers of cells in the choroid which were HLA DR positive. All other antibodies were negative.

Discussion

The ocular inflammation in Behçet's disease is characterised by a severe occlusive vasculitis. Most of the eyes examined pathologically from patients with Behçet's disease have been removed because of secondary complications and reflect the end stage pathology of the condition.^{9,10} The eyes we have studied were obtained postmortem and were not removed because of complicating pathology. This tissue therefore, although subject to modification by immunosuppressive therapy, gives a better picture of the ongoing

immunopathology of the condition. A perivascular lymphocytic infiltrate and marked thickening of the vascular walls was seen in the retinal and optic nerve vessels of both eyes and the lymphocytes in and around the vessel walls were identified as T cells. The perivascular lymphocytes in ocular sarcoidosis¹¹ and pars planitis¹² have also been identified as T cells.

A proportion of the T cells found in the perivascular infiltrates and within the vessel walls stained positively with CD4 and IL2 receptor monoclonal antibodies. The IL2 receptor expression of these cells is remarkable since the patient was heavily immunosuppressed at the time of death and demonstrates the difficulty in treating adequately the severe vasculitis seen in Behçet's disease.

The role of T lymphocytes in the tissue pathology of Behçet's disease has been demonstrated in immunohistopathological studies of tissues from other affected sites.⁵⁻⁸ The identification of T cells as the predominant cell type in the ongoing vascular lesions in the eye supports the view that cell-mediated immune mechanisms are responsible for the tissue damage seen in this condition. The absence of B lymphocytes and neutrophils is evidence that humoral immune mechanisms do not play a major role in the ocular immunopathology.

The expression of the MHC class II antigen HLA DR by retinal pigment epithelial cells and vascular endothelial cells has been described in other forms of intraocular inflammatory disease.¹¹⁻¹⁴ Aberrant expression of MHC class II antigens has been demonstrated on endogenous tissue cells in conditions thought to be of auto-immune aetiology,^{15,16} and it has been suggested that these cells may play a role in antigen presentation to infiltrating CD4+ T lymphocytes¹⁷ such as those demonstrated in this study.

Successful immunotherapy of intraocular disease will depend on targeting specific cellular components involved in the pathogenesis of the tissue destruction. The demonstration in this study activated CD4+ T cells in the vasculitic lesions in ocular Behçet's disease suggests that

future treatment directed at the down-regulation of the effects of CD4+ T cells would be beneficial in controlling the severe ocular inflammation.

The work was supported by Wellcome Trust Grant No 030412 11.4R.

- 1 Michelson JB, Chisari FV. Behçet's disease. *Surv Ophthalmol* 1982; 26: 190-203.
- 2 Shimada K, Yaoita H, Shikano S. Chemotactic activity in the aqueous humor of patients with Behçet's disease. *Jpn J Ophthalmol* 1972; 16: 84-92.
- 3 Shimada K, Kogure M, Kawashima T, Nishioka K. Reduction of complement in Behçet's disease and drug allergy. *Med Biol* 1974; 52: 234-9.
- 4 Williams BD, Lehner T. Immune complexes in Behçet's syndrome and recurrent oral ulceration. *Br Med J* 1977; 1: 1387-9.
- 5 Yamana S, Jones SL, Aoi K, Aoyama T. Lymphocyte subsets in erythema nodosum-like lesions from patients with Behçet's disease. In: Lehner T, Barnes CG, eds. *Recent advances in Behçet's disease*. London: Royal Society of Medicine 1986, pp 117-21.
- 6 Kaneko F, Takahashi Y, Muramatsu Y, Miura Y. Immunological studies on aphthous ulcer and erythema nodosum-like eruptions in Behçet's disease. *Br J Dermatol* 1985; 113: 303-12.
- 7 Poulter LW, Lehner T, Duke O. Immunohistological investigation of recurrent oral ulcers and Behçet's disease. In: Lehner T, Barnes CG, eds. *Recent advances in Behçet's disease*. London: Royal Society of Medicine, 1986, 123-8.
- 8 Yamana S, Jones SL, Shimamoto T, Shiota T, Aoyama T, Takasugi K. Immunohistological analysis of lymphocytes infiltrating the terminal ileum in a patient with intestinal Behçet's disease. In: Lehner T, Barnes CG, eds. *Recent advances in Behçet's disease*. London: Royal Society of Medicine 1986, 129.
- 9 Fenton RH, Easom HA. Behçet's syndrome. A histopathologic study of the eye. *Arch Ophthalmol* 1964; 72: 71-81.
- 10 Shikano S. Ocular pathology of Behçet's syndrome. In: *International symposium on Behçet's disease*. Basel: Karger, 1966, 111-36.
- 11 Chan CC, Wetzig RP, Palestine AG, Kuwabara T, Nussenblatt RB. Immunopathology of ocular sarcoidosis. *Arch Ophthalmol* 1987; 105: 1398-402.
- 12 Wetzig RP, Chan CC, Nussenblatt RB, Palestine AG, Mazur DO, Mittal KK. Clinical and immunopathological studies of pars planitis in a family. *Br J Ophthalmol* 1988; 72: 5-10.
- 13 Chan CC, Detrick B, Nussenblatt RB, Palestine AG, Fujikawa LS, Hooks JJ. HLA-DR antigens on retinal pigment epithelial cells from patients with uveitis. *Arch Ophthalmol* 1986; 104: 725-9.
- 14 Chan CC, Palestine AG, Kuwabara T, Nussenblatt RB. Immunopathological study of Vogt-Koyanagi-Harada syndrome. *Am J Ophthalmol* 1988; 105: 607-11.
- 15 Hanafusa T, Pujol-Borrell R, Chiovato L, Russell RCG, Doniach D, Bottazzo GF. Aberrant expression of HLA-DR antigen on thyrocytes in Graves' disease; relevance for autoimmunity. *Lancet* 1983; ii: 1111-5.
- 16 Ballardini G, Mirakian R, Bianchi FB, Pisi E, Doniach D, Bottazzo GF. Aberrant expression of HLA-DR antigens on bile duct epithelium in primary biliary cirrhosis: relevance to pathogenesis. *Lancet* 1984; ii: 1009-13.
- 17 Bottazzo GF, Pujol-Borrell R, Hanafusa T, Feldmann M. Role of aberrant HLA-DR expression and antigen presentation in induction of endocrine autoimmunity. *Lancet* 1983; ii: 1115-9.