

Eye movement tics

F Shawkat, C M Harris, M Jacobs, D Taylor, E M Brett

Abstract

An 8-year-old girl presented with opsoclonus-like eye movement and an 18 month history of intermittent facial tics. Investigations were all normal. Electro-oculography showed the eye movements to be of variable amplitude (10–40 degrees), with no intersaccadic interval, and with a frequency of 3–4 Hz. Saccades, smooth pursuit, optokinetic, and vestibular reflexes were all normal. These abnormal eye movements eventually disappeared. It is thought that they were a form of ocular tics.

(*Br J Ophthalmol* 1992; 76: 697–699)

Tics are quick, involuntary, and repetitive muscular movements that can be transient or persistent, local or widely generalised.¹ It is common for children with tics to present to a paediatrician with accompanying symptoms of emotional disturbances. Tics are common in childhood with a prevalence of 13% and an age of onset of 6–12 years.² By the age of 7 years, approximately 5% of children have a history of such abnormal movement disorders.³ Most often tics originate with facial movements which then may gradually extend to other parts of the body. They may be a continuum from mild, simple, suppressible tics to chronic multiple, and complex ones.^{4,6} Most childhood tics resolve spontaneously and, in patients with multifocal tics, the last to resolve are often eye blinking tics.⁷

The few eye movement tics reported in the literature have been associated with ocular and facial tics and resembled nystagmus.⁸ Frankel and Cummings⁹ reported eye rolling tics in a group of patients with Tourette's syndrome who also had blepharospasm. Binyon and Prendergast¹⁰ presented three cases with ocular tics: one had infantile autism and Tourette's syndrome, another had other types of tics that were complicated by neurological, behavioural, and educational problems. Their third patient had isolated eye movement tics that eventually disappeared. Opsoclonus-like eye movements have not been reported.

Case report

An 8-year-old girl was referred because of episodes of bizarre eye movements. She was born to unrelated parents following a normal pregnancy by forceps delivery. There were no neonatal problems and her development was normal. She was a very bright, intelligent, outgoing child and well above average academically. She was the older of two children. There was a family history of a grandfather who had multifocal tics as a child but this did not include eye movements.

At the age of 6.5 years she developed

symmetrical facial tics which became more frequent and florid over the next 4 months. These continued on and off for 12 months, though they did subside substantially. No neurological or physical abnormalities were found. Eighteen months after the initial onset of tics she developed episodes of lid retraction, convergence, and rotatory nystagmus of which she appeared to be unaware. The duration of these episodes was 5–15 seconds and they varied from a couple of episodes a day to repeated attacks lasting for much of the day. Initial investigations of computed tomographic scan of the brain, electroencephalogram, ultrasound of the adrenals, and 24 hour catecholamine excretion were all normal. These tests were performed because the original provisional diagnosis was that of dancing eye syndrome.

On admission to hospital neurological examination was found to be normal, with full external ocular movements. When questioned about her eye movements she said that she 'sometimes knows it is going to happen', though she often appeared to be unaware of them. She was also capable of initiating and suppressing these oscillations.

Urine creatinine and homovanillic acid levels were normal. Magnetic resonance imaging, repeat electroencephalogram, brainstem and visual evoked potentials, and electroretinograms were also normal. Electro-oculographic eye movement studies were carried out and a video recording was taken of the opsoclonus. Five weeks after her hospital admission the anomalous eye movements had completely resolved.

EYE MOVEMENT RECORDINGS

Horizontal eye movements were recorded using electro-oculography (EOG) and they were monitored on video. The chaotic saccadic bursts occurred without any intersaccadic intervals, and in the horizontal and vertical planes, thus fulfilling the criteria of 'opsoclonus'.¹¹

Our patient exhibited bursts of conjugate, rotatory, and pendular oscillations. The ampli-

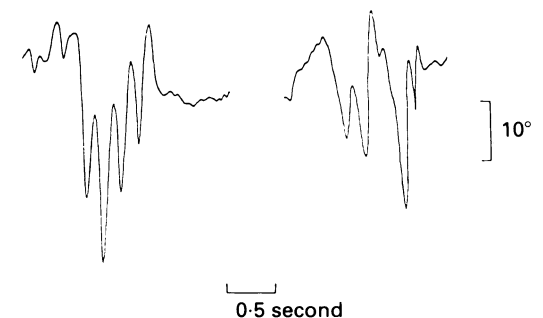


Figure 1 Horizontal electro-oculogram depicting the opsoclonus. Two typical examples of the spontaneous eye oscillations.

Department of
Ophthalmology
F Shawkat
C M Harris
M Jacobs
D Taylor

Department of
Neurology, Hospital for
Sick Children, Great
Ormond Street, London
WC1 3JH
E M Brett

Correspondence to:
F Shawkat.

Accepted for publication
9 June 1992

tude of the horizontal components was rather variable and ranged from 10 to 40 degrees with a frequency of 3–4 Hz (Fig 1). These eye movements were often observed in association with eyebrow raising, facial grimacing, and, on some occasions, with arm and leg extensions and slight arching of the back.

Saccades were normal. Smooth pursuit gain was 1.0 at 20 deg/s. Full field, binocular optokinetic nystagmus gain was 0.9 at 25 deg/s. Vestibular nystagmus in the dark had a peak gain of 0.9, with a chair acceleration of 18 deg/s up to 80 deg/s. The vestibular time constant was estimated to be 15 seconds. These results are all within the normal limits for our laboratory. However, short episodes of opsoclonus were evident throughout the testing session and the oscillations were superimposed upon the normal eye movements.

Discussion

Opsoclonus is a rare but striking disorder of ocular motility. It is characterised by involuntary, chaotic bursts of multidirectional, high amplitude, high frequency saccades, without an intersaccadic interval.¹¹ The absence of intersaccadic intervals distinguishes opsoclonus from macrosaccadic oscillations.¹²

In children opsoclonus usually occurs in one of three settings: transient neonatal opsoclonus,¹³ parainfectious or encephalopathic opsoclonus, and the syndrome of opsoclonus and myoclonus,¹⁴ which can be neuroblastoma related. This has also been known as 'dancing eye syndrome', 'myoclonic encephalopathy', and 'infantile polymyoclonia';¹⁵ and is characterised by an acute or subacute onset of polymyoclonia, cerebellar ataxia, and opsoclonus.

Precise localisation of the lesion causing opsoclonus remains uncertain,^{16,17} and studies have shown mild to severe loss of cerebellar Purkinje cells.^{18–21} It is likely that with the complex neuronal network involved in the generation of saccades, there may be more than one anatomical site involved in the pathogenesis of opsoclonus.²²

In our patient a diagnosis of 'dancing eye syndrome' was rejected owing to the lack of other clinical symptoms and to the characteristics of the oscillations. They were of lower frequency (3–4 Hz) than in opsoclonus recorded from patients with brainstem and cerebellar pathology, including children with 'dancing eye syndrome', which are in the order of 10 Hz.²³ Studies^{11,24} have reported a wide frequency range for opsoclonus (from 5 to 13 Hz) yet our patient's saccadic frequency remains outside this range. Another unusual feature of the opsoclonus in our case was the large variability in the amplitude of the oscillations.

Simultaneous video and EOG recording enabled careful and continuous monitoring of the patient's behaviour. Our patient did have some accompanying facial motor behaviour, the most common being eyebrow raising, retraction, and twitching of the eyelids during the bout of opsoclonus and facial grimacing just prior to its onset. Opsoclonus has been reported together with eyelid movement and twitching,²⁵

blinking,¹⁶ and lid retraction.²⁶ However these signs usually present together with other manifestations such as ataxia, myoclonus, and tremor. Thus, the possibility of ocular tics was entertained.

Tics possess three features that can help differentiate them from other movement disorders²⁷: (1) they are often preceded by a sensation and an irresistible urge to move²⁸; (2) they can be wilfully suppressed; and (3) they persist in all stages of sleep.²⁹ We did not record our patient's eye movements during sleep but they were consistent with the first two features.

It has been thought that tics are manifestations of underlying psychological conflict. Our patient's ocular tics could be considered as a form of 'conversion disorder'. This is defined as a disturbance of physical functioning that cannot be explained by pathophysiological mechanisms but is due to psychological conflict or need.³⁰ Studies suggest that conversion symptoms usually develop in children with pre-existing vulnerabilities: they tend to have academic problems, be conscientious, perfectionistic, and egocentric.³¹ Our patient was noted to be very intelligent, hyperactive, and outgoing though IQ was not formally assessed. Studies also suggest that those with tics have above average intelligence,^{32,33} but they perform better only on tests involving psychomotor speed and reaction times⁴; this has been interpreted to represent an exaggerated motor response to stress.

The association of stress and anxiety with tics has been well documented.^{4,6,34} Through discussions with the patient's parents it became apparent that they had high expectations of their daughter and it was revealed that the onset of her symptoms occurred soon after the birth of the second child. This could well have been the 'stressor' to initiate and exacerbate her symptoms, to which she may have already had a predisposition.

The possibility was raised that the eye movements may be voluntary. Voluntary nystagmus and flutter occur in normal subjects and can also be learnt.³⁵ They are usually associated with a convergence effort, but this was not observed in our case.

Though the abnormal eye movements have disappeared it is important to follow up this patient in case of any further symptoms. We believe this is a form of ocular tics. Follow-up studies⁴ have shown that two thirds of patients recover completely, with the best prognosis being for children whose onset of tics was between 6 and 8 years of age.

We thank the Wooden Spoon Society, the Iris Fund, Help a Child to See and the Leathersellers Charitable Trust for their support.

- 1 Graham P. *Child psychiatry: a developmental approach*. Oxford: Oxford University Press, 1991.
- 2 Lapouse R, Monk MA. Behaviour deviations in a representative sample of children: variation by sex, age, race, social class and family size. *Am J Orthopsychiat* 1964; 34: 436–46.
- 3 Kellmer Pringle ML, Butler NR, Davie R. In: *11,000 seven year olds*. London: National Bureau for Co-operation in Child Care, 1987: 185.
- 4 Golden GS. Tics and Tourette's: a continuum of symptoms? *Ann Neurol* 1978; 4: 145–8.
- 5 Fahn S. The clinical spectrum of motor tics. In: Friedhoff AJ and Chase TN, eds. *Gilles de la Tourette Syndrome*. *Adv Neurol*. New York: Raven Press, 1982; 35: 341–4.
- 6 Shapiro AK, Shapiro ES, Bruun RD, Sweet RD. *Gilles de la Tourette's syndrome*. New York: Raven Press, 1978.

- 7 Corbett JA, Matthews AM, Connell PH, Shapiro DA. Tics and Gilles de la Tourette's syndrome: a follow-up study and critical review. *Br J Psychiat* 1969; 115: 1229-41.
- 8 Meige H, Feindel E. *Tics and their treatment*. (Translated by SAK Wilson). London: Appleton 1907.
- 9 Frankel M, Cummings JL. Neuro-ophthalmic abnormalities in Tourette's syndrome: functional and anatomic implications. *Neurology* 1984; 34: 359-61.
- 10 Binyon S, Prendergast M. Eye-movement tics in children. *Dev Med Child Neurol* 1991; 33: 343-55.
- 11 Vignaendra V, Lim CL. Electro-oculographic analysis of opsoclonus: its relationship to saccadic and nonsaccadic eye movements. *Neurology* 1977; 27: 1129-33.
- 12 Fukazawa T, Tashiro K, Hamada T, Kase M. Multisystem degeneration: drugs and square wave jerks. *Neurology* 1986; 36: 1230-3.
- 13 Hoyt CS, Mousel DK, Weber AA. Transient supranuclear disturbances of gaze in healthy neonates. *Am J Ophthalmol* 1980; 89: 708-13.
- 14 Kinsbourne M. Myoclonic encephalopathy of infants. *J Neurol Neurosurg Psychiat* 1962; 25: 271-9.
- 15 Dyken P, Kolar O. Dancing eyes, dancing feet: infantile polymyoelonia. *Brain* 1968; 91: 305-20.
- 16 Cogan DG. Ocular dysmetria: flutter like oscillations of the eyes, and opsoclonus. *Arch Ophthalmol* 1954; 51: 318-35.
- 17 Wertenbaker C, Behrens MM, Hunter SB, et al. Opsoclonus: a cerebellar disorder? *Neuro-ophthalmol* 1981; 2: 73-83.
- 18 Henson RA, Ulrich H. *Cancer and the nervous system: the neurological manifestations of systemic malignant disease*. London: Blackwell, 1982: 431.
- 19 Ellenberger C, Campa JF, Netsky MG. Opsoclonus and parenchymatous degeneration of the cerebellum. The cerebellar origin of an abnormal ocular movement. *Neurology* 1968; 18: 1041-6.
- 20 Graus F, Cordon-Cardo C, Cho E-S, Posner JB. Opsoclonus and oat cell carcinoma of lung: lack of evidence for anti-CNS antibodies. *Lancet* 1984; i: 1479.
- 21 Kilgo GR, Schwartze GM. Opsoclonus. Update on clinical and pathologic associations. *J Clin Neuro-Ophthalmol* 1984; 4: 109-13.
- 22 Zee DS. Eye movement disorders and ocular motor control. *Curr Opin Neurol Neurosurg* 1989; 2: 749-58.
- 23 Leigh RJ, Zee DS. *The neurology of eye movements*. Philadelphia: FA Davis, 1991.
- 24 Pampiglione G, Maia M. Syndrome of rapid irregular movements of eyes and limbs in childhood. *Br Med J* 1972; 1: 469-73.
- 25 Cogan DG. Opsoclonus, body tremulousness, and benign encephalitis. *Arch Ophthalmol* 1968; 79: 545-51.
- 26 Bellur SN. Opsoclonus: its clinical value. *Neurology* 1975; 25: 502-7.
- 27 Jankovic J. The neurology of tics. In: Marsden CD, Fahn S, eds. *Movement disorders-2*. London: Butterworths, 1987.
- 28 Bliss J. Sensory experiences of Gilles de la Tourette's syndrome. *Arch Gen Psychiat* 1980; 37: 1343-7.
- 29 Glaze DG, Frost JD, Jankovic J. Gilles de la Tourette's syndrome. Disorder of arousal. *Neurology* 1983; 33: 586-92.
- 30 Davidson Nemzer E. Somatoform Disorders. In: Lewis M, ed. *Child and adolescent psychiatry*. Baltimore: Williams and Wilkins, 1991.
- 31 Leslie SA. Diagnosis and treatment of hysterical conversion reactions. *Arch Dis Child* 1988; 63: 506-11.
- 32 Mahler MS, Luke JA, Daltroff W. Clinical and follow-up study of the tic syndrome in children. *Am J Orthopsychiat* 1945; 15: 631-47.
- 33 Zausmer DM. Treatment of tics in childhood. *Arch Dis Child* 1954; 29: 537-42.
- 34 Trimble MR, Robertson MM. The psychopathology of tics. In: Marsden CD, Fahn S, eds. *Movement disorders -2*. London: Butterworths, 1987.
- 35 Hotson JR. Convergence-initiated voluntary flutter: a normal intrinsic capability in man. *Brain Res* 1984; 294: 299-304.