

Orbital volume measurement in the management of pure blowout fractures of the orbital floor

D G Charteris, C-H Chan, R W Whitehouse, J L Noble

Abstract

With the recent advent of accurate orbital volume assessment by computed tomography, a retrospective analysis was made of 31 patients with 'pure' blowout fracture of the orbital floor, managed either surgically or conservatively, to determine whether orbital volume measurement could provide an additional parameter of use in the management of such fractures. There was a significant difference in orbital volume discrepancy between patients managed surgically or conservatively suggesting that this investigation may be of use in decision making on surgical intervention in patients with orbital blowout fractures.

(*Br J Ophthalmol* 1993; 77: 100-102)

The term 'pure blowout' is used to refer to a fracture of the floor or medial wall of the orbit without a fracture of the orbital rim. These fractures may cause entrapment of orbital soft tissue structures with resulting enophthalmos and limitation of vertical or horizontal ocular motility. This type of fracture must be distinguished from an 'impure' blowout fracture where the orbital rim and adjacent facial bones are involved.¹

Diagnosis of a blowout fracture is made on the basis of the characteristic clinical findings of limitation of vertical (and horizontal) ocular movements causing diplopia, enophthalmos, and, in some cases, decreased sensation in the distribution of the infraorbital nerve. The mechanism of these findings is considered to be buckling of the orbital rim and increased intra-orbital pressure causing expansion in the volume

of the bony orbit and entrapment of the orbital soft tissue structures in the fracture with or without injury to the infraorbital nerve as it passes through the infraorbital groove. The clinical manifestations may be masked in the initial period following the injury by orbital and periorbital bruising and oedema and swelling of the inferior and medial rectus muscles. The clinical diagnosis can be supported by radiological investigations. Conventional plain x rays may show the characteristic 'tear-drop' appearance in the maxillary antrum (although this may be masked by blood in the antrum). Orbital tomograms provide a more sensitive investigation for defining orbital floor fractures. Because of the complexity in the anatomy of the orbital and ethmoidal regions computed tomography (CT) is now recognised to be the best imaging technique for diagnosing fractures.²

The management of orbital blowout fractures is aimed towards the prevention of long term diplopia (due to restriction of ocular movements) and enophthalmos. Some cases will recover fully with conservative management while others require surgical intervention to release entrapped structures from the fracture site and, on occasions, to provide orbital volume replacement. The indications for, and timing of, surgical intervention remain controversial.³⁻⁶ The rationale for early surgical intervention to release entrapped extraocular muscles and prevent secondary muscle scarring and contracture has been questioned as a significant numbers of cases will continue to have resolution of diplopia in the weeks following injury, and such an approach would therefore lead to unnecessary surgery in a number of cases.⁷ It is, however, accepted that early surgery produces more satis-

Manchester Royal Eye Hospital, Oxford Road, Manchester M13 9WH
D G Charteris
C-H Chan
J L Noble

Department of Diagnostic Radiology, The Stopford Medical School, Oxford Road, Manchester M13 9PT
R W Whitehouse

Correspondence to: Mrs J L Noble.

Accepted for publication 3 November 1992

Figure 1 (A) Transaxial image to show the lines drawn to outline the left orbit for volume measurement (arrows). '1' is the region of interest, area = 5.84 cm². No fracture is visible in this image. (B) Same patient as (A), section through the orbital floor to show distortion caused by blowout fracture (arrow). (C) Same patient, oblique sagittal reformation along the line of the inferior rectus muscle. The fracture has produced downwards displacement of the muscle which is swollen in the midpart (arrow).

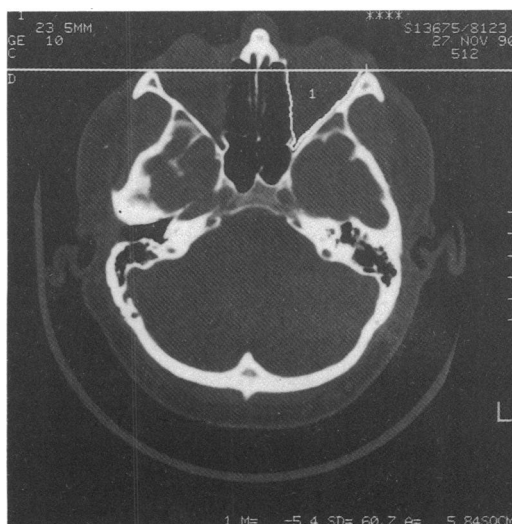

Fig 1A

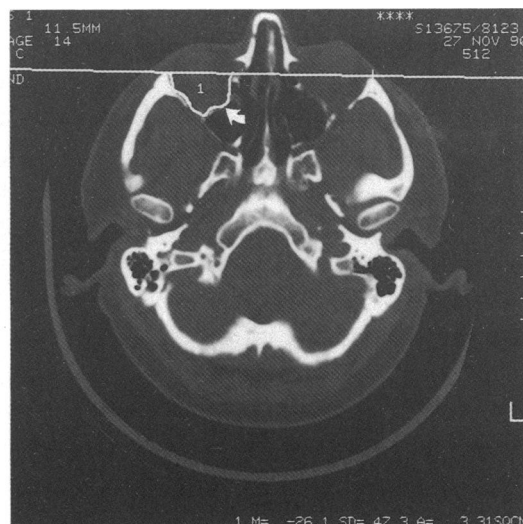


Fig 1B

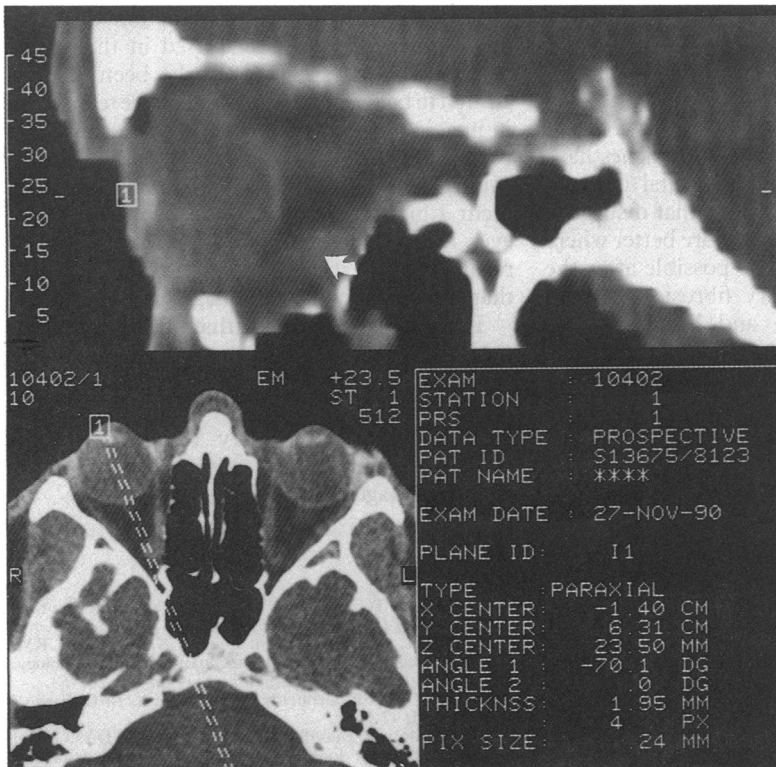


Fig 1C

factory results.^{4,8,9} The early identification of cases likely to have significant long term sequelae is therefore essential to the proper selection of cases for surgical intervention.

CT scanning has been demonstrated to be useful in the assessment of cases of blowout fracture which are at risk of developing late enophthalmos and troublesome diplopia¹⁰ and can therefore help in deciding which cases require surgical intervention. Furthermore it has been shown that orbital volume measurements from CT scans are significantly increased in post-traumatic enophthalmos¹¹ and are reversed by reconstruction of the bony orbit.¹² This study has analysed retrospectively orbital CT scans in patients with orbital blowout fractures to investigate the potential of orbital volume measurement to provide a quantitative measure of use in the assessment of the need for surgical intervention.

Materials and methods

PATIENTS

Thirty one patients with a pure blowout fracture of the orbital floor without medial wall involvement were included in the study. All patients had the diagnosis confirmed by CT scan. Initial assessment and subsequent clinic follow up of the patients routinely included Hess chart and assessment of field of binocular single vision.¹³ Indications for surgical exploration were as follows: (a) failure of the field of binocular single vision to improve and increasing diplopia as indicated in serial orthoptic assessment, (b) diplopia for more than 6 weeks with no or minimal signs of improvement, especially if the diplopia was in the primary or downgaze position, (c) symptoms which developed late after an initial symptom-free period, (d) presence of enophthalmos, especially during the early stage,

(e) CT appearance of an extensive area of comminuted and depressed fracture of the orbital floor or entrapment of inferior rectus muscle. The decision on surgical exploration was made after consideration of all these indications. Sixteen patients were managed conservatively and 15 had surgical exploration. A standard lower lid blepharoplasty incision was made; care was taken to avoid the lower lid retractors and the incision was deepened inferiorly to the level of the inferior orbital margin. The periosteum was divided below the inferior orbital margin and elevated, exposing the orbital floor. The fracture site was identified, any trapped tissue freed, and a silastic implant placed subperiosteally along the floor of the orbit behind the inferior orbital margin. The periosteum was carefully closed and the wound sutured.

CT SCANNING

CT scanning was carried out using a low dose technique previously described.¹⁴ Examinations were performed on an IGE 9800 scanner. Contiguous 3 mm axial sections were taken of the entire orbit using a dynamic scan protocol, 120 kVp, 40 mA, 2 second scan time and reformation in the coronal plane and an oblique sagittal plane parallel to the inferior rectus muscle was routinely employed. The skin entry dose for this examination was 11 mGy,¹⁵ resulting in an estimated lens dose of less than 10 mSv.

Orbital volume was measured by using a cursor to trace the orbital walls and the anterior orbital boundary as defined by a line joining the zygomaticofrontal process of each orbit (Fig 1). The volume was then calculated by summing the area of the orbit on each section and multiplying by section thickness.¹⁶ The measurement of orbital volume was carried out retrospectively and the discrepancy between the two orbits was not taken into account in the decision on surgical intervention. Statistical analysis was carried out using the non-parametric Mann Whitney U test to assess the relationship between the orbital volume discrepancy in the surgical and non-surgical groups.

Results

Of the 31 patients included in the study 15 had surgical exploration and repair and 16 were managed conservatively. In the group of patients treated surgically two had persistent and troublesome diplopia, seven others had mild residual diplopia in extreme upgaze which did not cause any significant problems. Residual enophthalmos was present in two patients treated surgically.

None of the patients in the group managed conservatively had troublesome diplopia attributable to the fracture, although seven had mild residual diplopia on extreme upgaze. Two patients in this group had residual enophthalmos.

The range of orbital volume discrepancy in the surgical group was from 0.2 to 8.2 ml with a mean of 4.01 ml (SD 2.22). In the non-surgical group the range of orbital volume discrepancy was from 0.7 to 4.3 ml with a mean of 2.22 ml (SD 1.16). There is a significant difference in

orbital volume discrepancy between the surgical and non-surgical groups ($p < 0.005$).

Discussion

Both surgical and non-surgical approaches have a place in the management of orbital blowout fractures.³⁻⁶ It is generally agreed that if surgical intervention is indicated, results are better where this is undertaken as early as possible after the injury to prevent secondary fibrosis and contracture of orbital fascia and ligaments and secondary involvement of extraocular muscles in the fracture.^{4,8,9} In the initial period following injury selection of patients for surgical management depends on a combination of factors including impaired ocular motility, enophthalmos, and size of fracture. Assessment of patients in this period is often hampered by orbital haemorrhage and oedema which can produce impaired motility which subsequently resolves, and can also mask enophthalmos which may develop at a later stage. Investigations which aid decision making on surgical intervention at an early stage are therefore likely to be of use in the management of patients with orbital blowout fractures. Orbital CT scanning has provided a means of reliably assessing the position and extent of fractures and the involvement of orbital tissues in the fracture.¹⁰ In this study we have demonstrated that accurate orbital volume measurement is possible on low dose CT scans of patients with blowout fractures and that there is a statistically significant difference in the orbital volume discrepancy between groups of patients managed surgically and conservatively. The additional refinement of volume measurement on orbital CT scans has the potential to help clinicians in deciding on surgical intervention in blowout fractures. There is, however, overlap in the ranges of orbital volume discrepancy between the two groups and no absolute value of volume discrepancy can be given as an indication for surgery. The potential of volume discrepancy measurement is to provide an additional parameter by which decisions on patient management can be made.

Orbital volume measurement can, in addition to aiding in the assessment of patients for early surgical intervention, provide information useful in planning volume replacement in late surgery for orbital trauma.^{11,12}

It is notable that a low radiation dose was employed in the CT scans used in this study. This technique has previously been demonstrated to be as effective as higher dose techniques in imaging orbital trauma¹⁴ and to be capable of providing orbital volume measurements.¹⁶ Multiplanar, high dose CT scanning protocols incur a high radiation dose to the globe,¹⁷ however the low dose protocol used in this study results in a surface radiation dose of only 25% of that of conventional axial images.¹⁵

This study suggests that orbital volume measurement from CT scans has a potential application in the assessment of patients with orbital blowout fractures. Further prospective analysis will be necessary to determine the clinical role of orbital volume assessment in patient management.

- 1 Cramer LM, Tooze FM, Lerman S. Blowout fractures of the orbit. *Br J Plastic Surg* 1965; 18: 171-9.
- 2 Weiss RA, Haik BG, Saint-Louis LA, Ellsworth RM. Advanced diagnostic imaging techniques in ophthalmology. *Ad Ophthalmic Plastic Reconstruct Surg* 1987; 6: 207-63.
- 3 Dullea B, Fells P. Orbital blowout fractures. *Br Orthoptic J* 1974; 31: 47-54.
- 4 Emery JM, von Noorden GK, Schlernitzauer DA. Orbital floor fractures: long term follow-up of cases with and without surgical repair. *Trans Am Acad Ophthalmol Otolaryngol* 1971; 75: 802-11.
- 5 Dutton JJ, Manson PN, Iliff N, Putterman AM. Management of blowout fractures of the orbital floor. *Surv Ophthalmol* 1991; 35: 279-98.
- 6 Wilkins RB, Havins WE. Current treatment of blowout fractures. *Ophthalmology* 1982; 89: 464-6.
- 7 Putterman AM, Stevens T, Urist MJ. Nonsurgical management of blowout fractures of the orbital floor. *Am J Ophthalmol* 1974; 77: 232-9.
- 8 Converse JM, Smith B, Obear MF, Wood-Smith D. Orbital blowout fractures: a ten-year survey. *Plastic Reconstruct Surg* 1967; 39: 20-36.
- 9 Converse JM, Smith B. On the treatment of blowout fractures of the orbit. *Plastic Reconstruct Surg* 1978; 62: 100-4.
- 10 Gilbard SM, Mafee MF, Lagouris PA, Langer BG. Orbital blowout fractures. The prognostic significance of computed tomography. *Ophthalmology* 1985; 92: 1523-8.
- 11 Bite U, Jackson IT, Forbes GS, Gehring DG. Orbital volume measurements in enophthalmos using three-dimensional CT imaging. *Plastic Reconstruct Surg* 1985; 75: 504-7.
- 12 Manson PN, Grivas A, Rosenbaum A, Vannier M, Zinreich J, Iliff N. Studies on enophthalmos: II. The measurement of orbital injuries and their treatment by quantitative computed tomography. *Plastic Reconstruct Surg* 1986; 77: 203-14.
- 13 Fitzsimmons R, White J. Functional scoring of the field of binocular single vision. *Ophthalmology* 1990; 97: 33-5.
- 14 Jackson A, Whitehouse RW. Low dose computed tomography in orbital trauma. *Eur Radiol* 1992 (submitted).
- 15 Gholkar A, Gillespie JE, Hart CW, Mott D. Dynamic low dose three dimensional computed tomography: a preliminary study. *Br J Radiol* 1988; 61: 1095-9.
- 16 Whitehouse RW, Jackson A. Measurement of orbital volumes following trauma using low dose computed tomography. *Eur Radiol* 1992 (submitted).
- 17 Ball JB. Direct oblique sagittal CT of orbital wall fractures. *Am J Roentgen* 1987; 148: 601-8.