

Clinical features of affected males with X linked ocular albinism

S J Charles, J S Green, J W Grant, J R W Yates, A T Moore

Abstract

Seventy four males affected by X linked ocular albinism (XLOA) from 19 pedigrees were examined to assess phenotypic variation and visual prognosis. Nystagmus was present in all cases except one. Best visual acuity ranged from 6/9 to 6/60; 79.7% could see 6/36 or better; most could read N5. Marked iris translucency and foveal hypoplasia were present in all cases. Posterior embryotoxon was present in 30% and dysplastic optic discs were often seen. Pigmentation of the posterior pole was associated with better visual acuity. XLOA is underdiagnosed: almost 20% of cases had been previously diagnosed as having congenital nystagmus until reviewed in this study.

(*Br J Ophthalmol* 1993; 77: 222-227)

Albinism is the term used to describe a heterogeneous group of inherited disorders characterised by skin hypopigmentation and ocular abnormalities such as reduced visual acuity and nystagmus. It may be divided broadly into two groups¹: oculocutaneous albinism characterised by hypomelanosis of the hair, skin, and eyes, with autosomal recessive inheritance; and ocular albinism where skin and hair pigmentation appear to be normal. Ocular albinism may occur in an autosomal recessive form (AROA)² or it may show X linked inheritance^{3,4} when it is known as Nettleship-Falls or X linked ocular albinism (XLOA).

The major effects of XLOA are nystagmus, reduced visual acuity, refractive errors, strabismus, iris translucency, fundus hypopigmentation, and foveal hypoplasia but other ocular abnormalities such as posterior embryotoxon, Axenfeld's anomaly,^{5,6} and optic disc hypoplasia⁷ have also been described. The effects of the XLOA mutation are not confined to the eye: visual evoked potentials (VEPs) show evidence of abnormal neuronal crossing at the optic chiasm⁸ and skin histology shows the presence of macromelanosomes in affected males and in the majority of female carriers.^{9,10}

XLOA is uncommon, with an estimated frequency of between 1:50 000¹¹ and 1:150 000.¹² The XLOA gene (OA1) has been mapped to the distal short arm of the X chromosome (Xp22.3)¹³⁻¹⁵ and first trimester prenatal diagnosis with linked DNA markers is now technically possible. Parents of affected children and women at risk of having an affected child need accurate and comprehensive information about visual prognosis in the condition. Although single large pedigrees have been reported^{9,16-19} there have been no studies of large collections of families so that there is little information upon the phenotypic variability or visual prognosis in

the condition. In this study we have examined a large number of families affected by XLOA to assess the phenotypic variation in affected men with particular reference to visual acuity, anterior segment changes, foveal and optic disc morphology.

Patient and methods

Eighteen families from the United Kingdom together with a large pedigree from Newfoundland previously described by Johnson *et al*¹⁸ were examined. Families were included in this study if affected males had reduced visual acuity, nystagmus, iris translucency, and hypopigmented fundi with foveal hypoplasia, and a family history consistent with X linked inheritance. In all families at least one woman had to have the 'mud-splattered' fundus characteristic of the carrier state and/or macromelanosomes on skin biopsy. Within each kindred a full ophthalmic examination was performed upon all available affected men including best corrected Snellen visual acuity, reading acuity at preferred reading distance, colour vision (Ishihara and City University plates), and binocular single vision (TNO stereotest). Strabismus and extraocular movements were assessed and nystagmus recorded as absent, horizontal, vertical rotary, or mixed.

Anterior segment examination included assessment of iris colour (classified as grey, blue, mixed blue/brown, or brown) and presence of posterior embryotoxon or Axenfeld's anomaly, and grading of iris translucency.¹⁰ After pupil dilatation, optic disc and foveal morphology were assessed, together with an examination of pigmentation and retinal vascular arrangement at the posterior pole. Fundus photographs and skin biopsies were obtained where possible. Skin biopsies, 4 mm in diameter, were taken from the inner aspect of the forearm under local anaesthesia. Sections were stained with haematoxylin and eosin and by the Masson-Hamperl method.

Results

Eighty one affected males from 19 pedigrees with XLOA (age range from 4 months to 77 years) have been seen. A comprehensive ophthalmic examination was possible in 74 individuals. All patients were Caucasian. Excluding the Newfoundland pedigree, which had previously been systematically assessed,¹⁸ 12 of the 62 affected males in British pedigrees were unaware of their correct diagnosis until reviewed in this study, 11 having previously been diagnosed as having congenital motor nystagmus. Although hair pigmentation in some patients was blond (13), ginger (two), or light brown (24), almost

Addenbrooke's Hospital,
Cambridge
Department of
Ophthalmology
S J Charles
A T Moore

Department of
Histopathology
J W Grant

Department of Clinical
Genetics
J R W Yates

Department of
Pathology, Cambridge
University
S J Charles
J R W Yates

Memorial University, St
John's, Newfoundland,
Canada
J S Green

Correspondence to:
Mr Stephen Charles,
FCOphth, Royal Eye
Hospital, Oxford Road,
Manchester.

Accepted for publication
12 January 1993

Figure 1 Best corrected distance visual acuity in affected males with XLOA; 79.7% could see 6/36 or better.

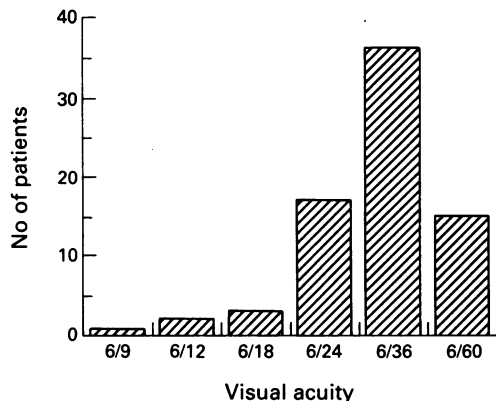
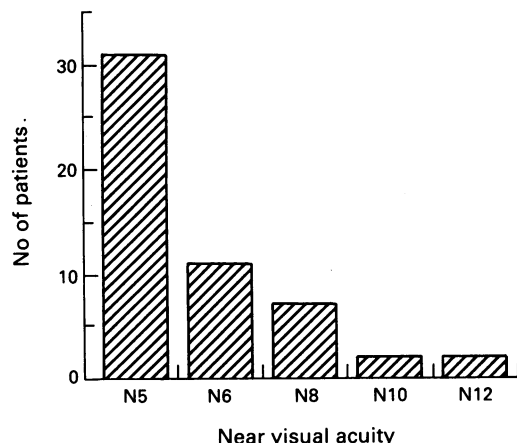


Figure 2 Best reading visual acuity in affected males with XLOA (without use of magnifiers).

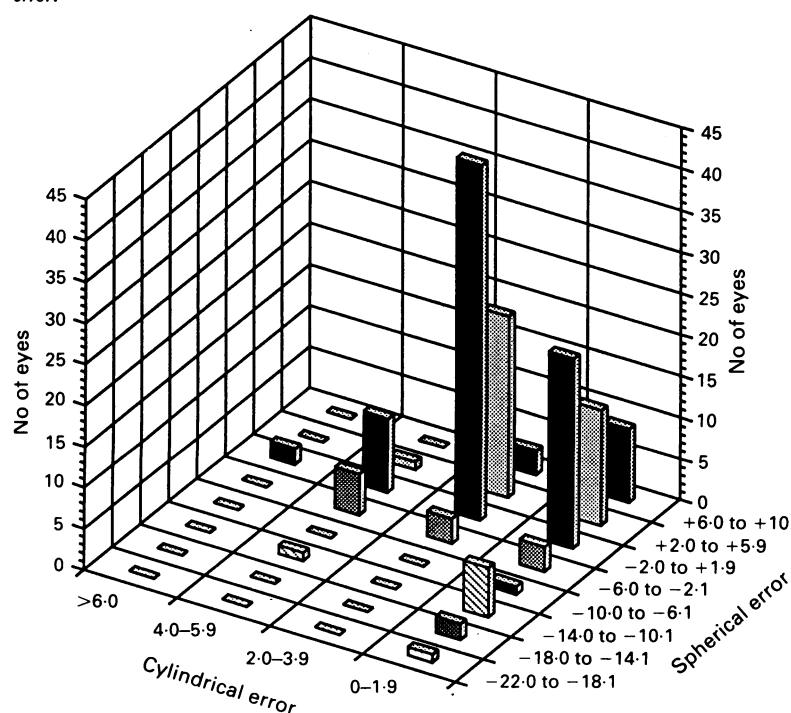


half the patients (35) had dark brown or black hair.

ACUITY

Best corrected Snellen visual acuity could be measured in 74 affected males (Fig 1) and ranged from 6/9 to 6/60; 79.7% had acuity of 6/36 or better. Reading vision was measured in 53 cases: 31 (58.5%) were able to read N5 either unaided

Figure 3 Refractive errors in affected males with XLOA. Cylindrical error is correlated with spherical error.



or with correction at their preferred reading distance (Fig 2). With the aid of a magnifier, if required, 90% could read N5 or N6. Acuity did not deteriorate with age. Visual acuity varied between affected males within families (the affected male that could see 6/9 had a nephew who could only see 6/60). There was no statistically significant difference in visual acuities between families (χ^2 109.45, 90 df, $p > 0.05$) or between different age groups (χ^2 26.97, 35 df, $p > 0.05$).

EXTRAOCULAR MOVEMENTS

Two of 74 patients did not have nystagmus in the primary position of gaze. One was seen for the first time aged 56 and denied ever having had nystagmus: his best visual acuity was 6/9 and there was exotropia, iris translucency, foveal hypoplasia, and macromelanosomes were demonstrated on skin biopsy. The other, aged 66, had horizontal nystagmus on lateral gaze but not in the primary position but admitted that his nystagmus had reduced with age. Older patients often reported reduced amplitude of nystagmus with time. Sixty five cases (88%) had purely horizontal nystagmus in all positions of gaze, five (7%) had combined horizontal and rotary nystagmus, and two had rotary nystagmus alone. Manifest strabismus was present in 56 cases (76%); 46% were exotropic and 30% were esotropic. Exophoria was present in four cases and esophoria in three. Eleven cases were orthotropic (two had had previous strabismus surgery).

REFRACTIVE ERRORS

Spherical errors ranged from -20.0 dioptres to +9.0 dioptres (Fig 3). Hypermetropia was more common than myopia but 78 of 148 eyes (52.7%) had a spherical error between -2.0 D and +2.0 D. Cylindrical error ranged from 0 to 6.0 D, and 60.1% of eyes had astigmatism of 2.0 D or more. Anisometropia (more than 1.5 DS) was present in 13 patients (17.6%). High ametropia, either myopic or hypermetropic, did not segregate in families. The most myopic patient (-13.5 DS OD, -20.0 DS OS) had an affected brother who had hypermetropic astigmatism (+1.75 DS/+3.0 DC x 100 OD, +2.25 DS/+1.75 DC x 80 OS) and, within the same pedigree, five of 11 affected males were hypermetropic.

STEREOPSIS, COLOUR VISION

No patient showed any stereopsis using the TNO stereoacuity test. Colour vision could be tested in 72 patients: seven patients had varying degrees of red-green deficiency, but this abnormality did not segregate with XLOA. Three affected males in one pedigree had deuteranomalous colour vision, but affected males in another branch of the same pedigree had normal colour vision.

ANTERIOR SEGMENT CHANGES

Fifty six patients (76%) had either grey or blue irides, but darker pigmentation (brown or mixed blue/brown) was found in the remainder (24%).

Table 1 Iridocorneal anomalies seen in XLOA affected males, carrier women, and normal individuals (including clinically unaffected males and females, at 50% risk of having inherited the abnormal gene, who had a normal examination and normal spouses)

Anomaly	Affected males n (%)	Carrier women n (%)	Normal individuals n (%)
None	51 (69)	113 (97)	25 (96)
Posterior embryotoxon	22 (30)	2 (2)	1 (4)
Axenfeld's anomaly	1 (1)	1 (1)	0
Total	74 (100)	116 (100)	26 (100)

Marked iris translucency (grade 3) such that the edge of the lens was visible around at least 180° was found in 73 cases (Fig 4). Grade 2 translucency (widespread translucency but edge of lens visible around less than 180°) was seen in the remaining patient. Results of slit-lamp assessment of the iridocorneal angle in affected males, carrier women, and normal individuals are shown in Table 1. Fifty one patients were normal but 22 (30%) had evidence of posterior embryotoxon and one had posterior embryotoxon and Axenfeld's anomaly. The number of patients with posterior embryotoxon was significantly more frequent in the affected males than either carrier women or normal individuals (χ^2 , $p < 0.001$). One patient had keratoconus. This was assumed to be a coincidental finding since he had three affected brothers all of whom had normal corneas.

OPTIC DISC MORPHOLOGY

Optic disc abnormalities were often seen

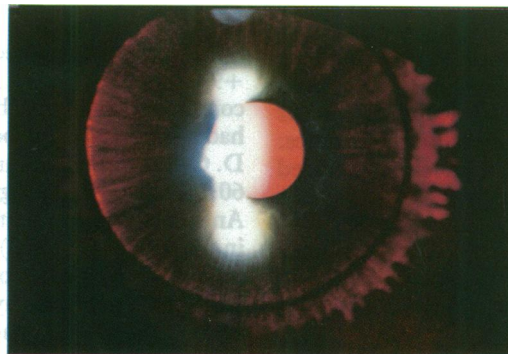

Figure 4 Marked iris translucency in affected males with XLOA.

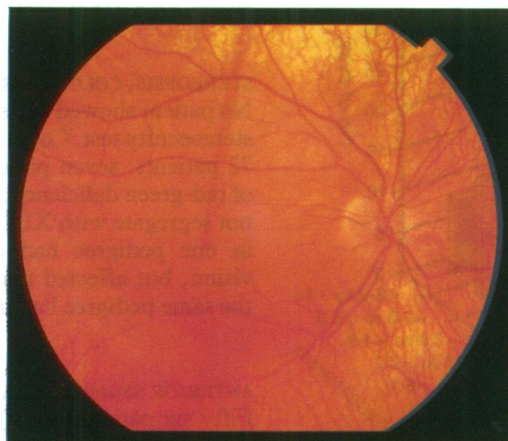


Fig 5A

Figure 5 Fundus photographs of affected males showing (A) pigmentation sufficient to mask choroidal vessels at posterior pole, but with peripheral hypopigmentation, contrasted with (B) another affected male with choroidal vessels visible at posterior pole.

including optic disc hypoplasia (29 of 148 eyes), tilted discs or dysplastic discs of normal size (seven), and optic disc coloboma (one). Fundus photography was possible in 40 eyes of 21 affected males. These photographs have been reviewed: seven discs were dysplastic and 12 were hypoplastic. Vascular distribution at the disc was often abnormal: all blood vessels entered through the nasal half of the disc in 19 eyes (50%).

MACULAR MORPHOLOGY

Foveal hypoplasia, as defined by absence of the foveal reflex and lack of foveal hyperpigmentation, was seen in all eyes. Some degree of pigmentation was often present at the posterior pole, but without any area of increased pigmentation to indicate a foveal zone. The presence or absence of pigment at the posterior pole was assessed in all patients on the basis of whether there was sufficient pigmentation to mask the underlying choroidal vasculature (Fig 5A, 5B). Of 148 eyes examined 117 (79%) had appreciable pigmentation at the posterior pole, masking choroidal vessels. Thirty five eyes were able to see 6/24 or better: 33 had pigmentation at the posterior pole, compared with only two eyes with hypopigmentation. This difference was statistically significant (χ^2 5.61, 1 df, $p < 0.025$). A normal foveal vascular 'wreath' was absent in all cases and in 16 eyes photographed a large non-cilioretinal vessel crossed the putative foveal zone in a horizontal direction (Fig 6A). After leaving the disc, branches of upper and lower temporal blood vessels respected the horizontal raphe.

SKIN BIOPSY

Skin biopsy was performed in 39 affected males and all except one have shown macromelanosomes. This patient was aged 60, had nystagmus, iris translucency, and foveal hypoplasia and had two daughters each with the 'mud-splattered' fundus appearance of the carrier state. Multiple sections were taken from a single biopsy, but macromelanosomes were not demonstrated.

Discussion

Linkage analysis of the families reported in this

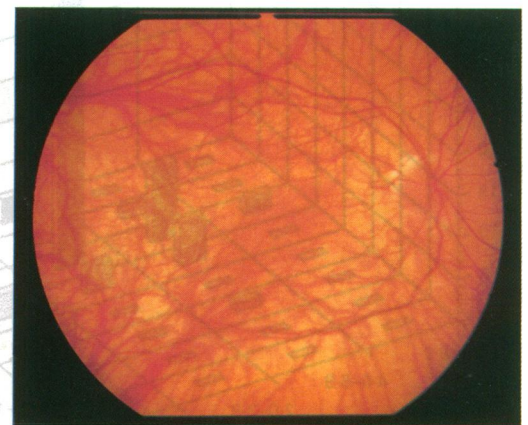


Fig 5B

study has not shown any genetic heterogeneity¹⁵ but we have found wide intrafamilial variation in the vision of affected males from 6/9 to 6/60 indicating variable expression of the XLOA gene. Most cases were able to see 6/36 or better. Visual acuity may occasionally be very good: three patients could see 6/12 or better and acuity of 6/6 has been reported.⁴⁷ There was no statistically significant difference between the distribution of visual acuities of affected males between different pedigrees. The condition is not progressive and we found no deterioration of visual acuity with age. Near vision is good: almost 60% could read N5 without an optical reading aid. Nystagmus was found in all cases except one, although there is the possibility that this case may have had nystagmus earlier in life. Marked iris translucency was seen in all cases and posterior embryotoxon was commonly found, indicating mild dysgenesis of the anterior segment. Refractive errors were common: 60% had astigmatism of 2 dioptres or more but although spherical errors ranged from -20 D to +9 D, just over half (53%) had a spherical error of between -2.0 D and +2.0 D. There was absence of the foveal reflex, lack of normal foveal hyperpigmentation, and abnormal foveal vascular architecture in all cases. Most eyes, and almost all those with visual acuity greater than 6/36, had sufficient pigment at the posterior pole to mask choroidal vasculature, but the typical hypopigmented albinoid fundus appearance with clearly visible choroidal vasculature was seen in the periphery in all cases (Figs 5A, 6B).

There are several mechanisms which may be responsible for the impaired vision in XLOA. Although nystagmus clearly limits vision, psychophysical testing indicates that visual resolution in albinos is limited by factors other than nystagmus alone.²⁰ Foveal hypoplasia is a critical sign for diagnosis of XLOA and may be the major cause of limited vision. It may be the only consistent ophthalmoscopic abnormality in XLOA in black patients.²¹ Normal foveal development involves peripheral migration of the inner retinal layers to form the foveal pit with central migration of cone photoreceptors, which continues after birth.²² At the same time each cone elongates and thins, increasing foveolar cell density fourfold. In the human albino retina no such migration occurs such that foveal cones

remain spaced apart.²³ This correlates with psychophysical testing in which the acuity deficit in albinism appears to be limited to the central visual field with normal peripheral acuity at eccentricities of 10° or more.²⁴ Albino central vision is superior to normal peripheral vision²⁵ consistent with the idea that the central retina of the albino is a spatially magnified (under-developed) version of the normal fovea. Foveal hypoplasia is not confined to XLOA. It may also be associated with aniridia,²⁶ Åland Island eye disease,²⁷ and other forms of albinism¹ and may occur as an isolated anomaly, when it may be sporadic²⁸ or dominantly inherited.²⁹

Abnormalities of perifoveal vascularisation have been described in albinism⁷ with retinal vessels located in and streaming across the putative macular area, although in a few cases of oculocutaneous albinism perifoveal vasculature appeared normal with fluorescein angiography.³⁰ Absence of the foveal avascular zone has also been described in isolated foveal hypoplasia.³¹ We found an absence of the normal foveal avascular zone in all patients. Large retinal vessels often crossed the putative foveal zone (Fig 6A), but upper and lower temporal vessels and their branches respected the horizontal raphe.

Other structural abnormalities may affect visual potential in the albino eye. Better visual acuity in this study was associated with more pigmentation of the posterior pole. In all forms of albinism reduced visual acuity may broadly be related to the degree of ocular hypopigmentation¹ although there may be exceptions: a case of oculocutaneous albinism has been reported³² with normal visual acuity (6/6) but where choroidal vessels were clearly seen in the macular zone. Dysplasia of the optic nerve head, which had been previously reported in ocular albinism,⁷ was often seen in this study and may also compromise vision.

Refractive errors are common in XLOA and, although marked high myopia or hypermetropia do occur, the commonest abnormality is astigmatism. It is not clear whether these high refractive errors are a direct effect of the underlying mutation or whether they reflect a failure of emmetropisation related to the poor acuity in infancy, as reported in other congenital ocular disorders.³³ Whatever the cause it is possible that

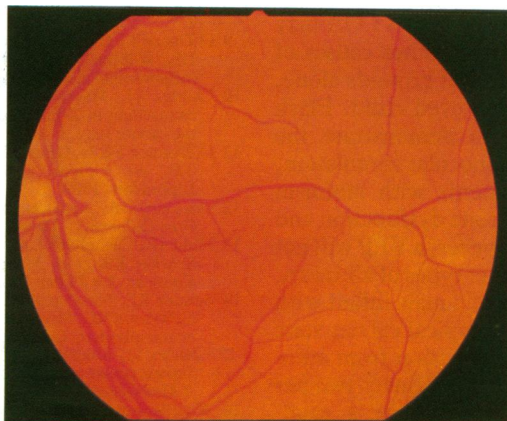


Fig 6A

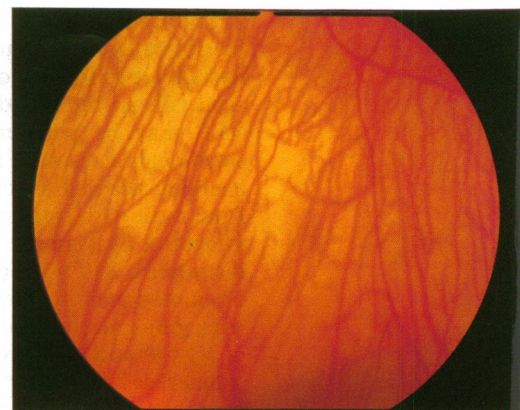


Fig 6B

Figure 6 Fundus photograph to show (A) large non-cilioretinal vessel crossing the putative foveal zone, with no clearly defined fovea. Posterior pole is well pigmented in contrast to peripheral fundus (B).

Table 2 Conditions associated with X linked inheritance and nystagmus (MIM numbers are given³⁹)

Condition	Onset	Clinical features	Investigations	Reference
XL congenital motor nystagmus (310700)	Infancy	No iris translucency Normal fundus	VEP: no asymmetry ERG: normal	40, 41
XL ocular albinism (300500)	Infancy	Iris translucency Foveal hypoplasia	VEP: asymmetry ERG: larger a-wave Skin biopsy: macromelanosomes Examination of mother	39
Congenital stationary night blindness (310500 (CSNB))	Infancy	No iris translucency Myopia; normal fundus	VEP: no asymmetry ERG: reduced scotopic b-wave	42, 43
Aland Island eye disease (300600) ? variant of CSNB	Infancy	Negative/equivocal iris translucency; myopia; protonomalous colour loss	VEP: no asymmetry ERG: reduced b-wave Skin biopsy: normal	27, 44
XL blue cone monochromatism (303700)	Infancy	No iris translucency Myopia: normal fundus Red-green colour blindness	VEP: no asymmetry ERG: absent photopic responses	45
XL complicated hereditary spastic paraparesis (a few reports) (312900)	Infancy/ childhood	Normal fundus Spasticity, ataxia Mental retardation	Little information MRI: paraventricular lesion described	46
Pelizaeus-Merzbacher disease (311601)	Infancy/ childhood	Optic atrophy Extrapyramidal signs Mental retardation	VEP: abnormal ERG: normal MRI: abnormalities of white matter	47, 48

VEP=visual evoked potentials; ERG=electroretinogram; MRI=magnetic resonance imaging.

some degree of amblyopia may be related to uncorrected refractive errors in early infancy. Therefore the early correction of refractive errors in affected infants should be considered to maximise visual potential. This study has confirmed the lack of stereopsis in XLOA and the high risk of strabismus. This is probably related to the misrouting of the optic pathways as reflected by VEP asymmetry to monocular stimulation.³ VEP abnormalities have been found to date in all our patients, and will be the subject of a subsequent publication. As well as the underlying anatomical abnormality, maturation of the visual pathways may be abnormal in XLOA and affected infants may be slow to see owing to delayed visual maturation.^{34 35}

XLOA is commonly misdiagnosed and the condition should be considered in all male infants presenting with nystagmus. Almost 20% of affected men from United Kingdom pedigrees had been previously misdiagnosed as having congenital nystagmus until reviewed in this study. Other X linked disorders may present with nystagmus in infancy (see Table 2) but XLOA is the most common and should always be considered in the differential diagnosis. The most useful clinical signs of XLOA are nystagmus, seen in all our patients except one, and marked iris translucency and foveal hypoplasia, seen in all patients. However, none of these signs is diagnostic alone. Marked iris translucency is seen in other types of albinism¹ and may be seen in normal individuals,^{10 36} and is more common with advancing age.³⁷

In the absence of a family history XLOA may be difficult to distinguish from other causes of nystagmus in infancy on clinical grounds alone, especially in the blond, blue eyed child. Flash VEP may be performed to demonstrate the asymmetrical response to monocular stimulation, enabling distinction of patients with albinism from those with congenital cone dysfunction and idiopathic nystagmus.³⁵ However, a VEP will not distinguish XLOA from other types of albinism. Examination of the mother of a male infant with nystagmus may indicate the typical carrier state of XLOA and enable differentiation from autosomal recessive ocular albinism. Ninety two per cent of obligate heterozygotes have a mud-splattered appearance of the fundus with hyper-

pigmented streaks in the periphery and in 74% this is associated with marked iris translucency.¹⁰ Macromelanosomes can be seen in almost all adult males with XLOA but not in oculocutaneous or recessive ocular albinism.² There are few data on the presence of macromelanosomes in infants with XLOA, although they have been described in fetal retinal pigment epithelium but not fetal skin.³⁸ At present the underlying molecular pathology is unknown, but we hope that advances in molecular genetics may allow characterisation of the XLOA gene such that a molecular genetic diagnosis will be possible.

SJC is in receipt of a Wellcome Trust Vision Research Fellowship. The authors thank clinicians who referred cases; Professor B Jay, Dr M Jay, Professor G J Johnson for help and advice; M Chiano for help with statistical analysis; and the families for cooperating so willingly in the study.

- Kinnear PE, Jay B, Witcop CJ Jr. Albinism. *Surv Ophthalmol* 1985; 30: 75-101.
- O'Donnell FE Jr, King RA, Green RW, Witcop CJ Jr. Autosomal recessively inherited ocular albinism. *Arch Ophthalmol* 1978; 96: 1621-5.
- Nettleship E. On some hereditary diseases of the eye. *Trans Ophthalmol Soc UK* 1909; 29: 57-198.
- Falls HF. Sex-linked ocular albinism displaying typical fundus changes in the female heterozygote. *Am J Ophthalmol* 1951; 34: 41-50.
- van Dorp DB, Delleman JW, Loewer-Sieger DH. Oculocutaneous albinism and anterior chamber cleavage malformations. *Clin Genet* 1984; 26: 440-4.
- Hayakawa M, Kato K, Nakajima A, Yoshiike T, Ogawa H. Nettleship-Falls X-linked ocular albinism with Axenfeld's anomaly. A case report. *Ophthalmol Paediatr Genet* 1986; 7: 109-14.
- Spedick MJ, Beauchamp GR. Retinal and optic nerve abnormalities in albinism. *J Ped Ophthalmol Strabismus* 1986; 23: 58-63.
- Creel D, O'Donnell FE Jr, Witcop CJ Jr. Visual system anomalies in human ocular albinos. *Science* 1978; 201: 931-3.
- O'Donnell FE Jr, Hambrick GW, Green WR, Iliff WJ, Stone DL. X-linked ocular albinism: an oculocutaneous macromelanosomal disorder. *Arch Ophthalmol* 1976; 94: 1883-92.
- Charles SJ, Moore AT, Grant JW, Yates JRW. Genetic counselling in X-linked ocular albinism: clinical features of the carrier state. *Eye* 1992; 6: 75-9.
- O'Donnell FE Jr, Green WR. The eye in albinism. In: Duane TD, ed. *Clinical ophthalmology*. Vol 4. Philadelphia: Lippincott, 1989.
- van Dorp DB. Shades of grey in human albinism. PhD Thesis, Free University, Amsterdam. Amsterdam: Elsevier, 1985.
- Kidd JR, Castiglione CM, Davies KE, Pakstis AJ, Gusella J, Sparkes RS, et al. Mapping the locus for X-linked ocular albinism. *Am J Hum Genet* 1985; 37 (Suppl): A161.
- Schnur RE, Nussbaum RL, Anson-Cartwright L, McDowell C, Worton RG, Musarella MA. Linkage analysis in X-linked ocular albinism. *Genomics* 1991; 9: 605-13.
- Charles SJ, Moore AT, Yates JRW. Genetic mapping of X-linked ocular albinism: linkage analysis in British families. *J Med Genet* 1992; 29: 552-4.
- Wardenburg PJ, van den Bosch J. X-chromosomal ocular albinism in a Dutch family. *Ann Hum Genet* 1956; 21: 101-22.

- 17 Gillespie FD, Covelli B. Carriers of ocular albinism with and without ocular changes. *Arch Ophthalmol* 1963; 70: 209-13.
- 18 Johnson GJ, Gillan JG, Pearce WG. Ocular albinism in Newfoundland. *Can J Ophthalmol* 1971; 6: 237-48.
- 19 Szymanski KA, Boughman JA, Nance WE, Olansky DC, Weinberg RS. Genetic studies of X-linked ocular albinism in a large Virginia kindred. *Ann Ophthalmol* 1984; 16: 183-96.
- 20 Abadi RV, Pascal E. Visual resolution limits in human albinism. *Vision Res* 1991; 31: 1445-7.
- 21 O'Donnell FE Jr, Green WR, Fleischman JA, Hambrick GW. X-linked ocular albinism in blacks: ocular albinism cum pigmento. *Arch Ophthalmol* 1978; 96: 1189-92.
- 22 Yuodelis C, Henrickson A. A qualitative and quantitative analysis of the human fovea during development. *Vision Res* 1986; 26: 847-55.
- 23 Fulton AB, Albert DM, Craft JL. Human albinism: light and electron microscopy study. *Arch Ophthalmol* 1978; 96: 305-10.
- 24 Wilson HR, Mets MB, Nagy SE, Kressel AB. Albino spatial vision as an instance of arrested visual development. *Vision Res* 1988; 28: 979-90.
- 25 Yo C, Wilson HR, Mets MB, Ritacco DG. Human albinos can discriminate spatial frequency and phase as accurately as normal subjects. *Vision Res* 1989; 29: 1561-74.
- 26 Hittner HM, Riccardi VM, Ferrell RE, Borda RR, Justice J. Variable expressivity in autosomal dominant aniridia by clinical, electrophysiologic, and angiographic criteria. *Am J Ophthalmol* 1980; 89: 531-9.
- 27 O'Donnell FE, Green WR, McKusick VA, Forsius H, Eriksson AW. Forsius-Eriksson syndrome; its relation to the Nettlehip-Falls X-linked ocular albinism. *Clin Genet* 1980; 17: 403-8.
- 28 Curran RE, Robb RM. Isolated foveal hypoplasia. *Arch Ophthalmol* 1976; 94: 48-50.
- 29 O'Donnell FE Jr, Pappas HR. Autosomal dominant foveal hypoplasia and pre-senile cataracts: a new syndrome. *Arch Ophthalmol* 1982; 100: 279-81.
- 30 Gregor Z. The perifoveal vasculature in albinism. *Br J Ophthalmol* 1978; 62: 554-7.
- 31 Oliver MD, Dotan SA, Chemke J, Abraham FA. Isolated foveal hypoplasia. *Br J Ophthalmol* 1987; 71: 926-30.
- 32 Summers CG, Creel D, Townsend D, King RA. Variable expression of vision in sibs with albinism. *Am J Med Genet* 1991; 40: 327-31.
- 33 Lambert L, Hoyt C. Postnatal growth of the eye. In: Taylor D, ed. *Paediatric ophthalmology*. Oxford: Blackwell, 1990; 28-31.
- 34 Tresidder J, Fielder AR, Nicholson J. Delayed visual maturation: ophthalmic and neurodevelopmental aspects. *Dev Med Child Neurol* 1990; 32: 872-81.
- 35 Russell-Eggitt I, Kriss A, Taylor DSI. Albinism in childhood: a flash VEP and ERG study. *Br J Ophthalmol* 1990; 74: 136-40.
- 36 Jay B, Carruthers J, Treplin MCW, Winder AF. Human albinism. *Birth Defects* 1976; 12: 415-26.
- 37 Norn MS. Iris pigment defects in normals. *Acta Ophthalmol* 1971; 49: 887-94.
- 38 Wong L, O'Donnell FE Jr, Green WR. Giant pigment granules in the retinal pigment epithelium of a fetus with X-linked ocular albinism. *Ophthalmol Paediatr Genet* 1983; 2: 47-66.
- 39 McKusick VA. *Mendelian inheritance in man*. 9th ed. Baltimore: Johns Hopkins University Press, 1990.
- 40 Pearce WG. Congenital nystagmus - genetic and environmental causes. *Can J Ophthalmol* 1978; 13: 1-9.
- 41 Gutman DH, Brooks ML, Emanuel BS, McDonald-McGinn DM, Zackai EH. Congenital nystagmus in a (46,XX/45,X) mosaic woman from a family with X-linked congenital nystagmus. *Am J Med Genet* 1991; 39: 167-9.
- 42 Krill AE. Congenital stationary night blindness. In: Krill AE, ed. *Krill's hereditary retinal and choroidal diseases*. Vol II. London: Harper and Row, 1977: 391-417.
- 43 Hittner HM, Borda RP, Justice J. X-linked recessive congenital stationary night blindness, myopia, and tilted discs. *J Pediatr Ophthalmol Strabismus* 1981; 18: 15-20.
- 44 Forsius H, Eriksson AW. Ein neues augensyndrom mit X-chromosomaler Transmission. Ein Sippe mit Fundus-albinismus, Fovealhypoplasie, Nystagmus, Myopie, Astigmatismus und Dyschromatopsie. *Klin Monatsbl Augenheilkd* 1964; 144: 447-57.
- 45 Spivey BE. The X-linked recessive inheritance of atypical monochromatism. *Arch Ophthalmol* 1965; 74: 327-33.
- 46 Gutman DH, Fischbeck KH, Kamholz J. Complicated hereditary spastic paraparesis with cerebral white matter lesions. *Am J Med Genet* 1990; 36: 251-7.
- 47 Taylor D. Ophthalmological features of some human hereditary disorders with demyelination. *Bull Soc Belge Ophthalmol* 1983; 208: 405-13.
- 48 Scheffer IE, Baraitser M, Wilson J, Harding B, Kendall B, Brett EM. Pelizaeus-Merzbacher disease: classical or connatal? *Neuropediatrics* 1991; 22: 71-8.