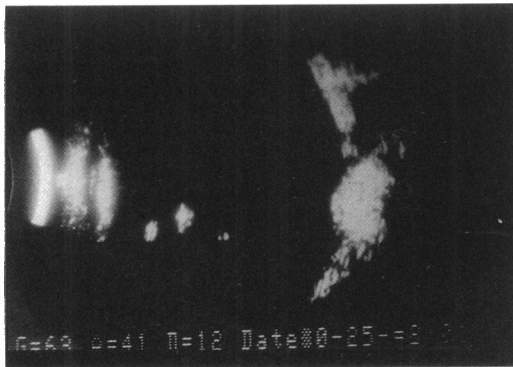


Figure 3 B scan ultrasonography 4½ years after the operation. Note the characteristic picture of the silastic sponge as well as the height of the chorioretinal indentation produced by the explant at the posterior pole. The location of the sponge seems to provide a barrier between the optic nerve pit and the macula.



macular hole leading to a rhegmatogenous retinal detachment, as happened in our case. This was probably due to a defect of the outer retinal layer and to the vitreous traction which was exerted in the macular area by the residual vitreous strands. The retina reattachment was achieved with the application of the macular buckling technique without the use of any kind of energy.<sup>8</sup> This technique, in addition to pneumatic retinopexy, vitrectomy plus fluid/air exchange, and vitrectomy plus silicone oil tamponade, constitutes the techniques currently recommended for the management of retinal detachment caused by macular holes.<sup>9-13</sup>

The fact that no serous macular detachment occurred within the 4½ years after the intervention should be attributed to the maintenance of the macular scleral buckle and to its extension right up to temporal margins of the optic nerve,

thus preventing the fluid flow from the optic pit to the submacular space (Fig 3).

This procedure should be an alternative solution for the management of secondary macular elevation caused by the pit of the optic disc.

- 1 Gass JDM. Serous detachment of the macula secondary to congenital pit of the optic nervehead. *Am J Ophthalmol* 1969; 67: 821-41.
- 2 Brown GC, Tasman WS. *Congenital abnormalities of the optic disc*. New York: Grune and Stratton, 1983: 97-126.
- 3 Lincoff H, Lope R, Kreissig I, Yanuzzi L, Cox M, Burton T. Retinoschisis associated with optic nerve pit. *Arch Ophthalmol* 1988; 106: 61-7.
- 4 Theodossiadis G. Evolution of congenital pit of the optic disc with macular detachment in photocoagulated and non-photocoagulated eyes. *Am J Ophthalmol* 1977; 840: 620-31.
- 5 Theodossiadis GP, Panopoulos M, Kollia AK, Georgopoulos G. Long-term study of patients with congenital pit of the optic nerve and persistent macular detachment. *Acta Ophthalmol (Kbh)* 1992; 70: 495-505.
- 6 Cox MS, Witherspoon CD, Morris RE, Flynn HW. Evolving techniques in the treatment of macular detachment caused by optic nerve pits. *Ophthalmology* 1988; 95: 889-96.
- 7 Schatz H, McDonald R. Treatment of sensory retinal detachment associated with optic nerve pit or coloboma. *Ophthalmology* 1988; 95: 178-86.
- 8 Theodossiadis G. Treatment of retinal detachment due to macular holes without chorioretinal lesions (a seven years follow-up). *Trans Ophthalmol Soc UK* 1982; 102: 198-203.
- 9 Convers M, Machefer R. A new approach to treating retinal detachment with macular hole. *Am J Ophthalmol* 1982; 94: 668-72.
- 10 Leaver PK, Clary PE. Macular hole and retinal detachment. *Trans Ophthalmol Soc UK* 1975; 95: 145-9.
- 11 Scot JD. Macular holes and retinal detachment. *Trans Ophthalmol Soc UK* 1974; 94: 319-24.
- 12 Haut J, Van Effenterre G, Flamand M. Treatment of macular hole and retinal detachment with silicone oil, with or without argon laser photocoagulation. *Ophthalmologica* 1983; 187: 25-39.
- 13 Chignell AH, Billington B. The treatment of macular holes by means of pars plana vitrectomy and internal air/SF6 exchange. *Graefes Arch Clin Exp Ophthalmol* 1986; 224: 67-72.

## *Aspergillus terreus* postoperative endophthalmitis

Taraprasad Das, Prateep Vyas, Savitri Sharma

*Aspergillus* endophthalmitis has been reported in drug abusers, in immunosuppressed hosts, following intraocular surgery, and after trauma. Usually *Aspergillus flavus*,<sup>1-4</sup> *Aspergillus fumigatus*,<sup>5</sup> and *Aspergillus nidulans*<sup>6,7</sup> are implicated as the offending organisms. Recently *Aspergillus terreus* endophthalmitis has been reported in a patient with chronic lymphocytic leukaemia.<sup>8</sup> We describe a case of postcataract surgery *Aspergillus terreus* endophthalmitis who was successfully treated by vitrectomy, and intraocular and systemic antifungal antibiotics. To our knowledge this is the first reported case of postoperative endophthalmitis caused by this species of *Aspergillus*.

### Case report

A 50-year-old man gave a history of uneventful intracapsular cataract extraction in left eye 4 weeks before presenting to us. His early post-

operative period was reported to be uneventful. Four weeks later he experienced pain, redness, and reduction in vision in the same eye. He was diagnosed to have postoperative endophthalmitis and referred for further management. On examination visual acuity in the operated eye was perception of light with accurate projection. The eye was relatively quiet with some hyperaemia of the conjunctiva. The cornea showed a small amount of stromal oedema with few keratic precipitates. The anterior chamber showed a moderate (2+) reaction. At the 6 o'clock position behind the iris in the anterior vitreous a white fluffy mass with feathery edges was seen (Fig 1A). A moderately good fundal glow was present with opacities in the mid vitreous and inferiorly. He was confirmed clinically to have postoperative endophthalmitis. After baseline renal function evaluation, intravenous gentamicin 80 mg three times a day and cefazolin 1 g four times a day was started. Topically 15% gentamicin and

LV Prasad Eye Institute and Hyderabad Eye Research Foundation, Hyderabad, India  
T Das  
P Vyas  
S Sharma

Correspondence to:  
Dr T Das, LV Prasad Eye Institute, Road No 2, Banjara Hills, Hyderabad - 500 034, India.

Accepted for publication  
26 January 1993

Figure 1(A) Preoperative photograph. Note white fluffy mass in anterior vitreous.

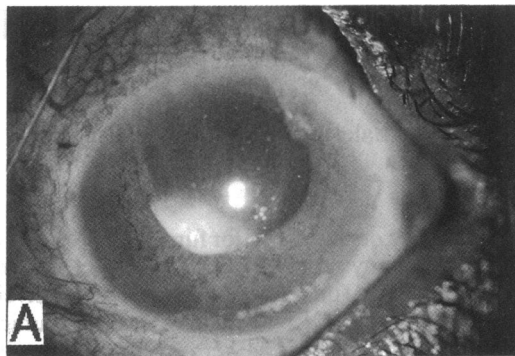


Figure 1(B) Lactophenol cotton blue mount of the culture showing hemispherical vesicle covered with biserial phialides bearing smooth conidia, characteristic of *A. terreus* ( $\times 110$ ).

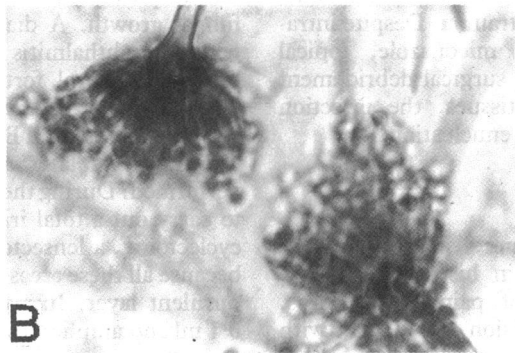
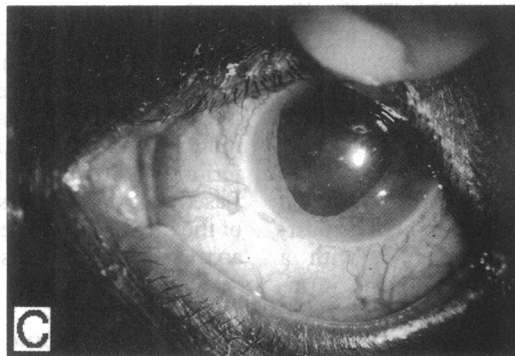


Figure 1(C) Postoperative photograph of the same eye.



50% cefazolin eye drops were instilled every hour alternately. Within 8 hours of presenting to us three port standard vitrectomy was performed and an undiluted vitreous biopsy specimen was sent for microbiological evaluation.

The wet mount, Giemsa, and Gram's stains were negative for bacteria and fungus. Intravitreal gentamicin 100  $\mu$ g with cefazolin 2.25 mg and dexamethasone 360  $\mu$ g were given at the end of surgery. A vitreous sample was cultured for aerobic and anaerobic bacteria and fungus on a number of media: blood agar, chocolate agar, Sabouraud's dextrose agar, brain heart infusion broth, and thioglycollate broth (supplemented with vitamin K and haemin). After 48 hours' incubation at 27°C Sabouraud's dextrose agar grew white fluffy colonies with central cinnamon brown pigmentation. Microscopic examination of the culture confirmed it to be *Aspergillus terreus* (Fig 1B). The same fungus was grown on several media and no bacteria were grown.

As soon as the microbiology report was obtained 5  $\mu$ g of amphotericin B was given

intravitreally. Oral ketoconazole 200 mg three times a day and topical natamycin every 2 hours were started. Intravenous and topical antibiotics were withdrawn. However, topical steroids were continued. The patient responded well with gradual recovery of a healthy fundal glow. The fundus details were visualised after 2 weeks and systemic ketoconazole was discontinued in view of its potential liver toxicity. When seen on the last follow up 4 months after vitrectomy the best corrected visual acuity was 6/18 and the vitreous was clear (Fig 1C).

#### Comment

*Aspergillus* endophthalmitis is a relatively rare condition encountered in clinical practice. Endogenous *Aspergillus* endophthalmitis is reported in immunocompromised individuals.<sup>1,2</sup> Exogenous *Aspergillus* endophthalmitis is reported following cataract surgery,<sup>3,4</sup> keratoplasty,<sup>6</sup> and eye trauma.<sup>4,5</sup> *Aspergillus flavus*,<sup>1-4</sup> *A. fumigatus*,<sup>5</sup> and *A. nidulans*<sup>6,7</sup> have been reported to be causative agents of exogenous and endogenous endophthalmitis.

Recently *Aspergillus terreus* was reported to cause endogenous endophthalmitis in a patient with chronic lymphocytic leukaemia.<sup>8</sup> This was the first report of *Aspergillus terreus* endophthalmitis. The reason for infrequent reporting could be because *Aspergillus terreus* is often considered a laboratory contaminant.

The presentation of our patient with ocular pain and reduction in vision 4 weeks after surgery with localised involvement of anterior and mid vitreous was characteristic of fungal endophthalmitis. However, the direct examination of undiluted vitreous specimen was negative. Forty eight hours later the culture was positive and at this time only intravitreal amphotericin B was given. This was supplemented with oral ketoconazole and topical natamycin.

Four months following vitrectomy the patient had useful vision with no recurrence of infection. Because of the changing microbiology pattern of endophthalmitis, any organism cultured from vitreous should not be dismissed either as normal conjunctival flora or a laboratory contaminant.

- 1 Doft BH, Clarkson JG, Rebell G, Forster RC. Endogenous *Aspergillus* endophthalmitis in drug abusers. *Arch Ophthalmol* 1980; **98**: 859-62.
- 2 Michelson JB, Freedman SD, Boyden DG. *Aspergillus* endophthalmitis in a drug abuser. *Ann Ophthalmol* 1982; **14**: 1051-4.
- 3 Driebe WT, Mandelbaum S, Forster RK, Schwartz LK, Culbertson WW. Pseudophakic endophthalmitis. Diagnosis and management. *Ophthalmology* 1986; **93**: 442-8.
- 4 Pflugfelder SC, Flynn HW, Zwickley TA, Forster RK, Tsiligianni A, Culbertson WW, et al. Exogenous fungal endophthalmitis. *Ophthalmology* 1988; **95**: 19-30.
- 5 Ho PC, Tolentino FI, Baker AS. Successful treatment of exogenous aspergillus endophthalmitis: a case report. *Br J Ophthalmol* 1984; **68**: 412-5.
- 6 Gandhi SS, Lamberts DW, Perry HD. Donor to host transmission of disease via corneal transplantation. *Surv Ophthalmol* 1981; **25**: 306-11.
- 7 Harish SJ, Perlutter JC, Boucher C, Bohigian G, Grand MG. Exogenous *Aspergillus* endophthalmitis. *Ann Ophthalmol* 1984; **16**: 417-9.
- 8 Kalina PH, Campbell RJ. *Aspergillus terreus* endophthalmitis in a patient with chronic lymphocytic leukemia. *Arch Ophthalmol* 1991; **109**: 102-3.