

CASE REPORTS

Penetrating keratoplasty in severe ocular graft versus host disease

J D Heath, J F Acheson, W E Schulenburg

We present a case of a large corneal perforation in severe ocular graft versus host disease (GVHD). Sequential penetrating keratoplasty has maintained a comfortable functioning eye followed up for 2 years.

Case report

A 27-year-old woman developed chronic myeloid leukaemia in 1985. She underwent a six locus HLA matched allogeneic bone marrow transplant in June 1989. Chronic gastrointestinal GVHD was diagnosed at 6 months which was treated with high dose prednisolone and cyclosporin A. She described no ocular symptoms at this time.

Following leukaemic relapse, she received an infusion of donor T lymphocytes 14 months after the original bone marrow transplant. One month later, she developed severe GVHD affecting the skin, oral mucosa, liver, and eyes. Ocular discomfort was managed symptomatically with topical methylcellulose drops, but after a period of 3 months she was referred to the ophthalmology department with severe left ulcerative keratitis and 1.5 mm hypopyon (Fig 1).

Examination of both eyes showed signs of active conjunctival GVHD with epithelial sloughing, pseudomembrane formation, and early scarring. The left visual acuity was hand movements with an absent corneal epithelium, a superior stromal melt, and generalised infiltrate. *Pseudomonas* species were cultured from corneal scrapes and the hypopyon and infiltrate resolved after treatment with topical antibiotics. The right eye had a corrected visual acuity of 6/12, a poor tear film with multiple punctate epithelial erosions, and keratinisation of the palpebral conjunctiva (Fig 2).

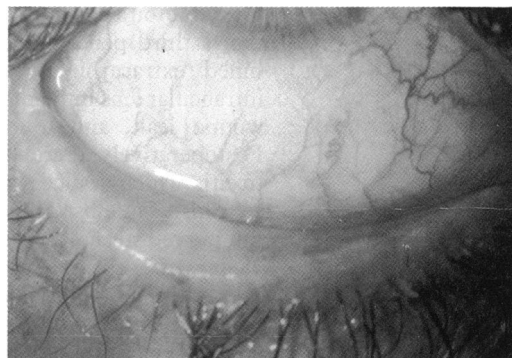

Figure 2 Right eye. Conjunctival keratinisation.

Three weeks later she was readmitted with a 6 mm perforation complicating a generalised progressive stromal melt (Fig 3), and underwent a corneoscleral graft. All four lacrimal puncta were occluded with cautery. Two weeks post-operatively she had 6/36 pinhole vision, a central corneal epithelial defect in a clear graft, and a quiet anterior chamber.

The corneal epithelial defect persisted and was accompanied by a gradual thinning of the underlying stroma, until after 4 months there only remained a central descemetocoele (Fig 4), which finally perforated after 5 months. A 7 mm penetrating keratoplasty was placed within the original graft (Fig 5).

Twelve months after the initial corneal graft, left visual acuity was perception of light with accurate projection due to a dense cataract. The systemic GVHD had responded to treatment with immunosuppressants with associated improvement in basal tear production and ocular lubrication. However, there was an aqueous leak at the inferior graft-graft interface and the

The Western Ophthalmic Hospital, Marylebone Road, London
J D Heath
J F Acheson
W E Schulenburg

Correspondence to:
Mr J D Heath, Department of Ophthalmology, University Hospital of Wales, Heath Park, Cardiff CF4 4XW.

Accepted for publication
19 March 1993

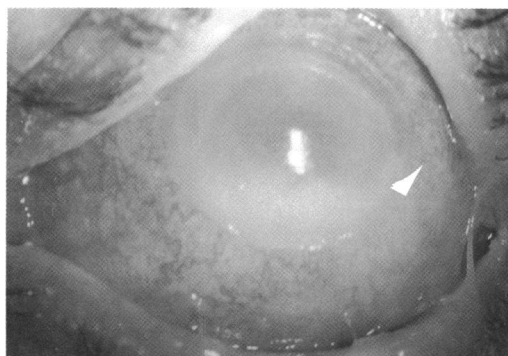


Figure 1 Left eye. Ulcerative keratitis with hypopyon.

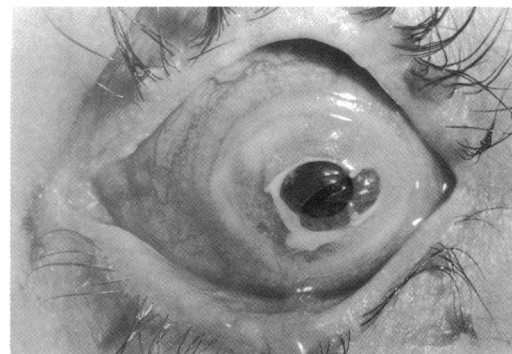
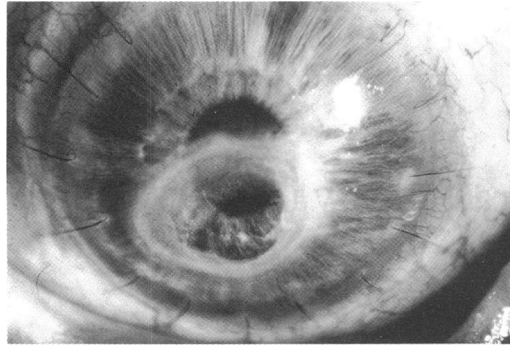


Figure 3 Left eye. Corneal perforation.

Figure 4 Left eye. Penetrating keratoplasty with descemetocele.



central corneal button became increasingly infiltrated. She was referred to Moorfields Eye Hospital for a second opinion, where it was felt that a third penetrating keratoplasty and combined extracapsular cataract extraction with intraocular lens implant was indicated to heal the wound leak, and to restore visual potential. Postoperatively there was a fibrinous anterior uveitis which settled with systemic and topical steroids. The host corneal button was cultured but proved sterile. Best corrected visual acuity at 18 days after the operation was 6/18.

A persistent epithelial defect in the donor cornea was treated initially with a silicon rubber contact lens, followed by a central tarsorrhaphy, and then a conjunctival flap, which broke down after a month. A cicatricial lower lid entropion resulted in trichiasis and exacerbated the epithelial defect. Correction of the entropion was combined with a mucous membrane graft and central tarsorrhaphy.

At 2 year follow up from original presentation, and 1 year after the most recent penetrating keratoplasty, the eye remains comfortable with a clear graft and a small central tarsorrhaphy.

Comment

Conjunctival involvement in GVHD has been reported to occur in 9% of 263 patients following allogeneic bone marrow transplant, with associated corneal epithelial loss in only 1.5%,¹ but the consequences may be disastrous for the eye. Ocular GVHD may present in the acute phase as a pseudomembranous conjunctivitis; in association with dermatitis, hepatitis, and mucositis; where there is a T cell mediated cytotoxic reaction to epidermal antigens; or in the chronic

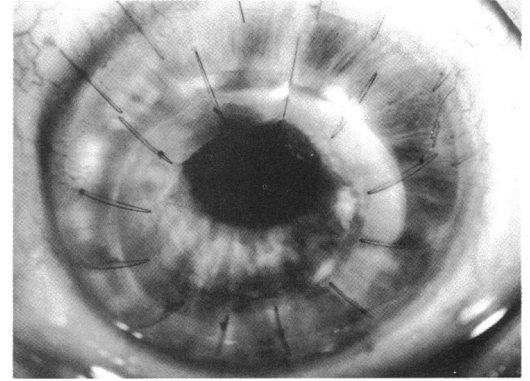


Figure 5 Left eye, following 7 mm keratoplasty within original graft.

phase as a Sjogren's-like syndrome resulting from lacrimal and other exocrine gland infiltration and destruction.² Sterile and infective corneal ulceration may develop leading rapidly to thinning and perforation. The adverse ocular environment retards corneal epithelial healing, although lubricants, bandage lenses, tarsorrhaphy, and conjunctival flap may help.³ Corneal grafting has a poor prognosis as the donor cornea is highly vulnerable to further ulceration and melting with or without sepsis. Conjunctival flaps or cyanoacrylate glue are sometimes suitable for small perforations, but massive perforations leave no alternative other than scleral or corneal grafting to achieve tectonic stability. Trimble⁴ reported one case where stable 1/60 vision was maintained for 6 months with a scleral graft and scleral contact lens.

We believe that our case is the longest surviving seeing eye 2 years after corneal perforation managed with sequential penetrating keratoplasty in severe ocular and generalised GVHD in a patient whose general health continues to improve.

The authors thank Mr J Dart and Mr R Collin and their staff at Moorfields Eye Hospital for help in the management of this case, and Sue Ford for help with the illustrations.

- 1 Jabs DA, Wingard J, Green WR, Farmer ER, Vogelsang G, Saral R. The eye in bone marrow transplantation. (III Conjunctival graft-vs-host disease.) *Arch Ophthalmol* 1989; 107: 1343-8.
- 2 Ferrara JLM, Deeg HJ. Graft-versus-host disease. *N Engl J Med* 1991; 324: 667-73.
- 3 Franklin RM, Kenyon KR, Tutschka PJ. Ocular manifestations of graft-vs-host disease. *Ophthalmology* 1983; 90: 4-13.
- 4 Trimble RB. *Research and clinical forums* 1982; 4: 93-5.