

ORIGINAL ARTICLES – Laboratory science

# Cancer-associated retinopathy with retinal phlebitis

Department of Ophthalmology, Faculty of Medicine, Kyushu University, Fukuoka, Japan  
 Y Ohnishi  
 S Ohara  
 T Sakamoto  
 T Kohno

Yoshitaka Ohnishi, Susumu Ohara, Taiji Sakamoto, Toshihiko Kohno, Fuminori Nakao

Hayashi Eye Hospital, Fukuoka, Japan  
 F Nakao

Correspondence to: Dr Yoshitaka Ohnishi, Department of Ophthalmology, Faculty of Medicine, Kyushu University, Fukuoka, 812, Japan.

Accepted for publication 29 June 1993

**Abstract**  
 A 50-year-old man with cancer-associated retinopathy was investigated using light and electron microscopy, immunofluorescence studies, and western blotting. He had visual disturbance, ring-like scotoma, and night blindness bilaterally. There were narrowed retinal arterioles and dilated retinal venules. Oral corticosteroid therapy had positive effects. Immunostaining using the patient's serum revealed a positive reaction in the gan-

glion cell layer of normal retina. Western blotting showed that the patient's serum antibody reacted with normal retinal proteins of 24 and 48 kDa. Multiple metastases were evident at autopsy.

(*Br J Ophthalmol* 1993; 77: 795-798)

Cancer-associated retinopathy (CAR) is an uncommon paraneoplastic event.<sup>1-9</sup> Since the first description by Sawyer<sup>1</sup> in 1976, data on about 25 such patients have been reported. Visual loss and ring-like scotoma are the presenting symptoms. The initial findings in our patient and which have not been reported in previous papers were retinal phlebitis and vitritis. In addition, immunofluorescence studies revealed that CAR antigen reacted with the ganglion cell layer of the normal retina. The CAR antigen was reported to be a recoverin-like protein.<sup>9</sup>

**Subject and methods**

**CASE REPORT**

A 50-year-old Japanese man who worked as a painter visited an ophthalmologist on 7 November 1990 with visual disturbance in the left eye. The corrected visual acuity of the right and left eye was 1.0 and 0.6, respectively. Two weeks later, visual acuity of the right and left eye was 0.2 and 0.4, respectively, and night blindness followed. Visual field defects were evident in both eyes (Fig 1). An oral corticosteroid was prescribed following the diagnosis of retrobulbar neuritis. Six days after drug initiation, visual acuity in the right and left eyes recovered to 0.7 and 0.6, respectively. On 29 December the drug was withdrawn. On 4 January 1991 bilateral visual acuity worsened, and he was sent to us for evaluation on 16 January. He had been smoking 30 cigarettes per day for more than 20 years. His and his family medical histories did not add any information.

**CLINICAL EXAMINATION AND MANAGEMENT**

Visual acuity in right and left eyes was 0.8 and 0.6, respectively, and ocular tension was within normal limits. In the left eye, there was a slight corneal precipitate and there were a few cells without flare in the anterior chamber and vitreous cavity of both eyes. There were narrowed retinal arterioles and dilated retinal venules with sheathing of venules in the periphery in both

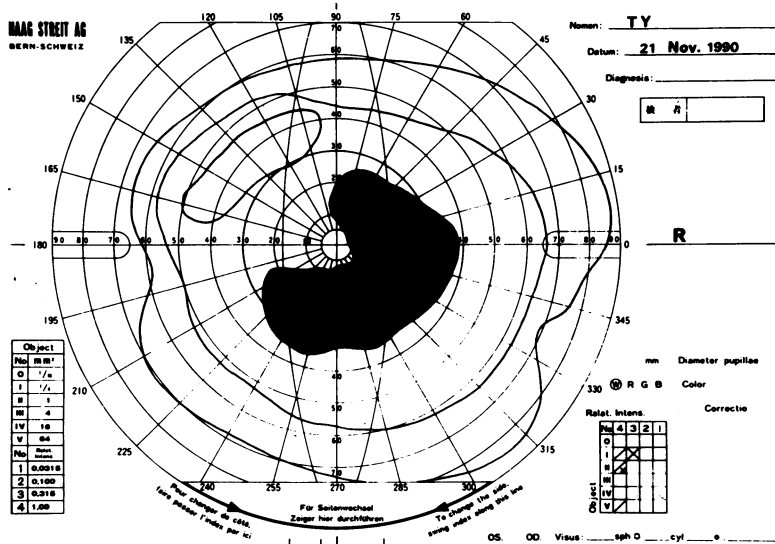


Fig 1A

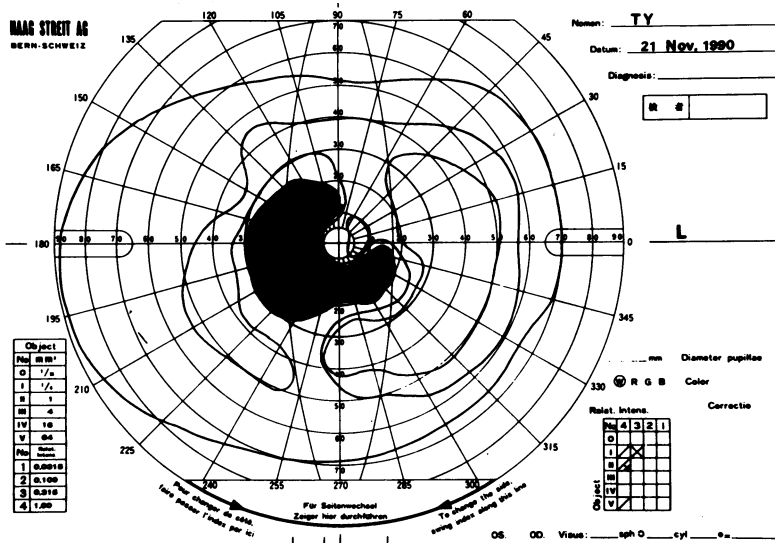


Fig 1B

Figure 1 Goldmann visual fields of the right (A) and left (B) eyes recorded on 21 November 1990.

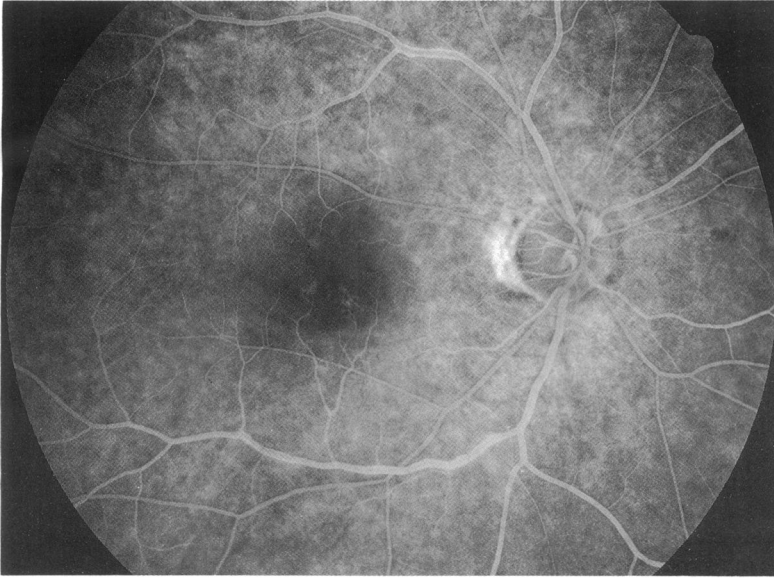


Fig 2A

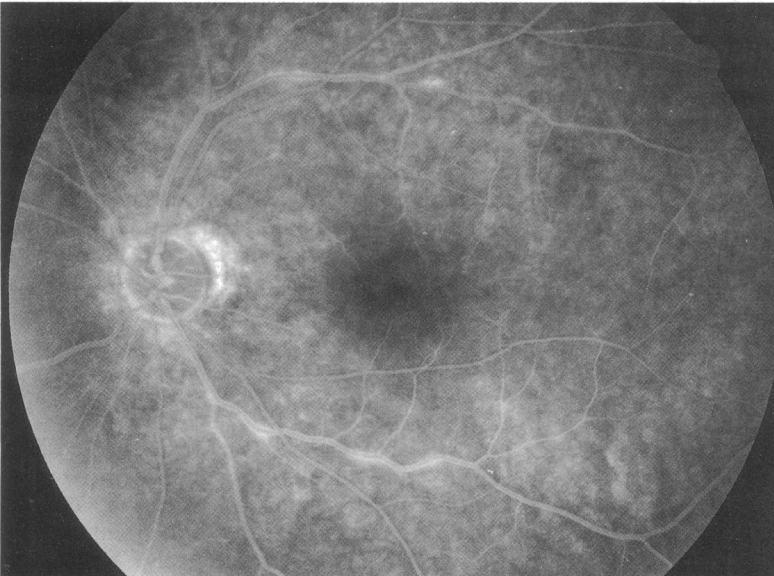
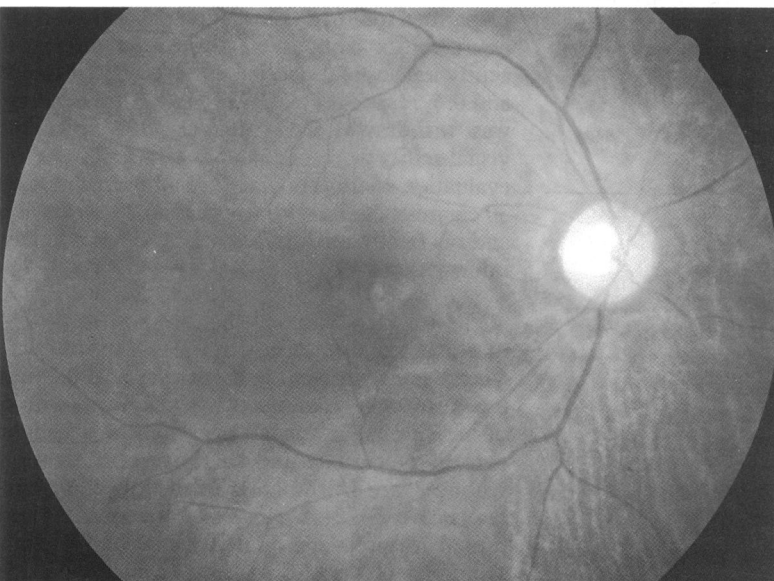


Fig 2B



*Figure 2 Fluorescein angiograms at venous phase of the right eye (A) and at late venous phase of the left eye (B) taken on 16 January 1991 showing narrowed arterioles and dilated venules with staining of the dye. Hyperfluorescein dots observed in both maculae are drusen, not microaneurysms. Sheathing of venules is not shown because this was present in the retinal periphery.*

eyes. There were several drusen in both maculae. Fluorescein angiography showed staining of the dye in the wall of the dilated venules (Figs 2A, B). Visual field examination by Goldmann perimetry revealed a ring-like scotoma in both eyes. The electroretinogram was non-recordable for both eyes.

On 21 January 1991, he was admitted to Kyushu University Hospital. Complete blood count was normal and the erythrocyte sedimentation rate was 51 mm/hour. A chest roentgenogram showed bilateral hilar lymph node swelling. Computed tomography and magnetic resonance imaging of the brain were normal. Intravenous prednisone, 50 mg/day, was initiated but loss of vision and visual field defects progressed.

On 14 February 1991 transbronchial lung biopsy confirmed the mass to be a small cell carcinoma. Neuron specific enolase of tumour markers by radioimmunoassay was 13 ng/ml (normal value was less than 10 ng/ml). On 25 February 1991, he was transferred to the department of respiratory medicine and anti-cancer therapy was begun. The central visual field became extremely narrow. Treatment with methylprednisone, 125 mg/day, was started and the visual field showed some recovery. On 26 April 1991, retinal venules became narrowed in diameter (Fig 3) and showed no staining of the dye in the wall by fluorescein angiography. Vision in both eyes was stable around 0.5. He died on 20 July 1991. Multiple metastases were evident at autopsy.

#### HISTOPATHOLOGICAL EXAMINATION

Both eyes, enucleated 8 hours after death, were fixed in 10% formaldehyde and then in 4% glutaraldehyde. Half of the eye was embedded in paraffin for light microscopic examination and the remainder was sectioned and embedded in epoxy resin for electron microscopy.

#### IMMUNOFLUORESCENCE STUDY

The 4  $\mu$ m frozen sections of control eyes obtained at autopsy were fixed with cold acetone and incubated with the patient's serum at dilutions of 1:100 to 1:10 000 in phosphate buffered saline (PBS) at 4°C for 8 hours. The serum dilution for good results was 1:1000. After three washings with PBS, fluorescein isothiocyanate conjugated rabbit anti-human immunoglobulin (EY Labs Inc, CA, USA) was applied for 1 hour at room temperature. The slides were mounted in 25% phenylenediamine glycerol in PBS and examined under a fluorescent microscope. Diluted serum from a healthy human (1:1000 in PBS) was used as a control.

*Figure 3 Fundus photograph of the right eye 2 months before death. Note the extremely narrowed arterioles.*

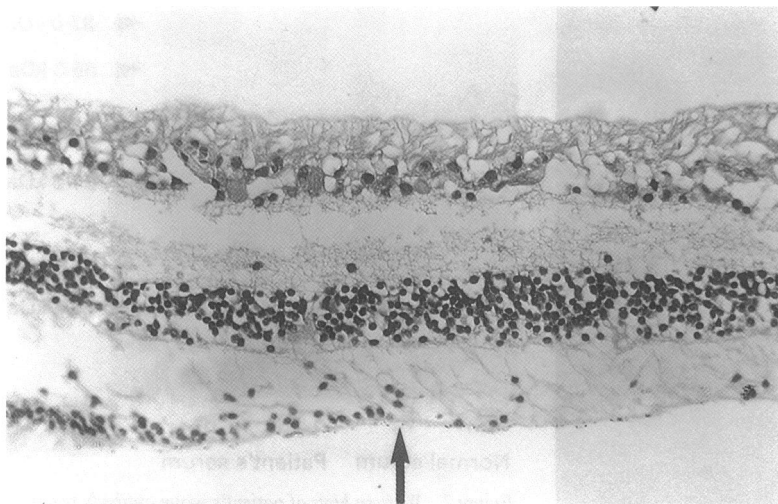


Figure 4 Light micrograph showing abrupt disappearance of the nuclei of the photoreceptor cells (arrow). The nuclei on the right of the arrow had disappeared.  $\times 220$ .

#### WESTERN BLOTTING

Fresh retina was obtained at autopsy on patients with no history of ocular disease. The retina was homogenised in 10 mM TRIS-HCl buffer (pH 7.4) containing 1 mM ethylenediaminetetraacetic acid and 1 mM phenylmethylsulphonyl fluoride for 20 minutes at 4°C. Unlysed cells and nuclei were removed by centrifugation at 500 g for 10 minutes. The solution obtained served as the retinal extract.

Electrophoresis was carried out according to Laemmli.<sup>10</sup> The retinal extracts were supplemented with sodium dodecyl sulphate (SDS) to give a final concentration of 1% and were electrophoresed under reduced conditions in 10% polyacrylamide gels containing 0.1% SDS (SDS-PAGE). Electrophoresed proteins in gels were transferred to nitrocellulose paper, the paper was

incubated with 1% bovine serum albumin, then with primary antibody (1:1000 diluted patient serum) overnight at 4°C, and finally with peroxidase conjugated anti-human IgG for 30 minutes. The paper was visualised with 4-chlor-1-naphthol and 0.01% hydrogen peroxide.

#### Results

Retinal degeneration was prominent in the paramacular and equatorial regions, morphologically. In some areas, the retina was normal. The number of ganglion cells and the nuclei in the outer nuclear layer appeared diminished. Pigment-laden macrophages were present in the outer nuclear layer. Outer segments of visual cells had disappeared in the retina posterior to the equator (Fig 4). The basal infoldings and melanosomes in the retinal pigment epithelium appeared diminished (Fig 5). There were no inflammatory cells in the wall of retinal vessels. The choroid appeared normal.

Immunostaining using the patient's serum showed a positive reaction in the ganglion cell layer of the retina and this was most prominent around the nucleus (Fig 6). The other parts of the retina, choroid, and sclera showed a negative reaction. Immunostaining using control serum showed no positive reaction in the ocular tissue.

In the western blots, two different proteins were recognised by immunoreaction with both the retina and choroid, using the patient's serum. One was 48 kDa and the other was 24 kDa (Fig 7). The immunoreaction was stronger for the retina than for the choroid. The control serum did not react positively with the examined samples.

#### Discussion

Cancer-associated retinopathy is a retinitis

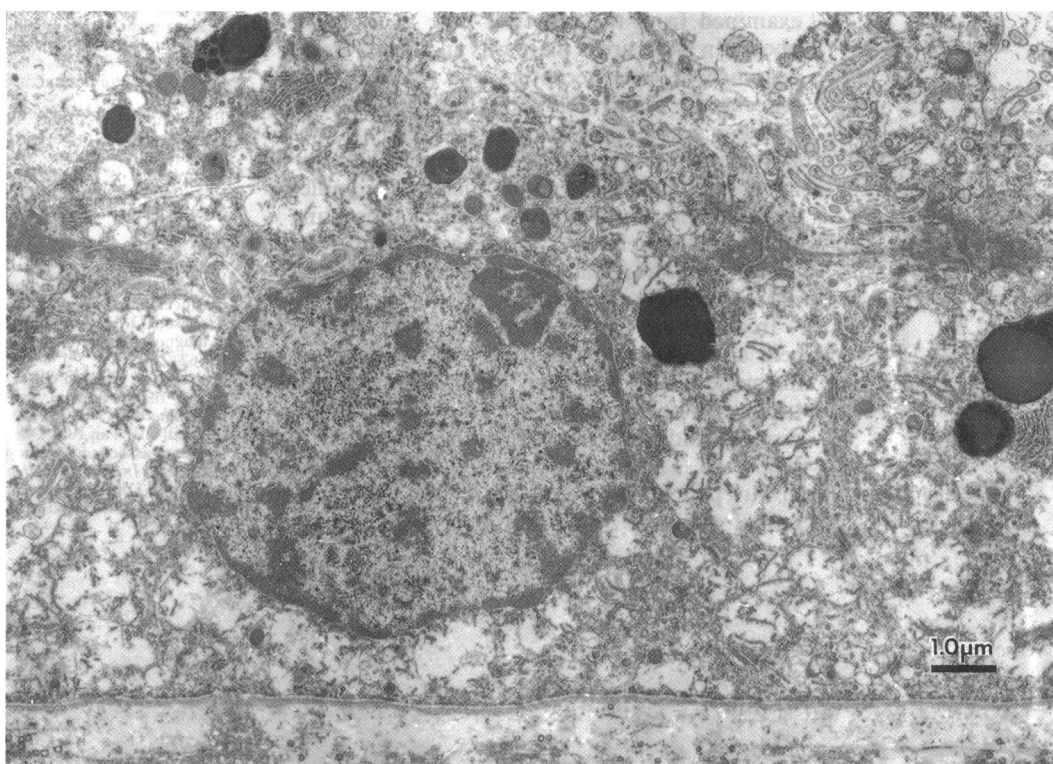


Figure 5 Electron micrograph showing a decrease in the number of melanin granules and little or no basal infolding in the retinal pigment epithelium.  $\times 8300$ .

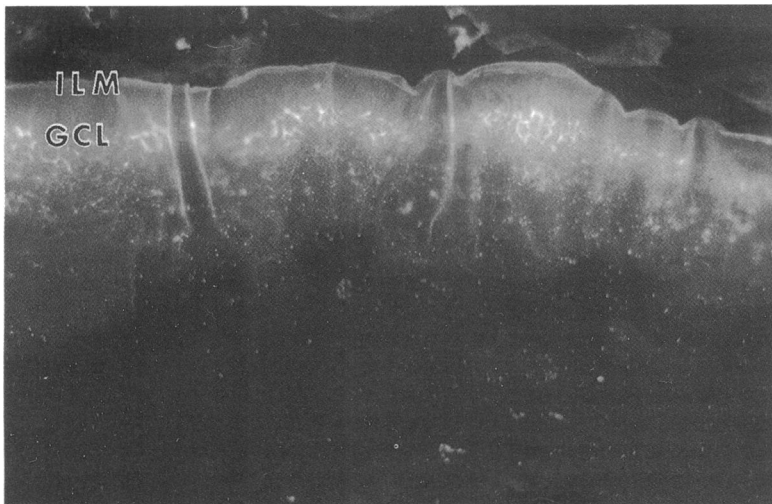


Figure 6 Immunohistochemistry of the patient's serum reacted on sectioned normal human retina. The antibody reactivity predominated in the ganglion cell layer. ILM=inner limiting membrane; GCL=ganglion cell layer.

pigmentosa-like disease.<sup>1-8</sup> A clinical triad of photosensitivity, ring scotomatous visual field loss, and attenuated retinal arteriole calibre leads to a correct diagnosis.<sup>7</sup> In our patient, there were nyctalopia, cells in the anterior chamber and vitreous cavity, and retinal phlebitis. The first tentative diagnosis was uveitis of unknown origin. Retinal phlebitis was demonstrated by fluorescein angiography but morphology revealed no cells in the retinal vessels. This discrepancy may be because retinal phlebitis was observed at the early stage of the disease. Retinal venules gradually narrowed in diameter and there was no staining of the dye, by fluorescein angiography, in the late stage of the disease. Therefore, we found no inflammatory cells in the wall of the venule in the autopsied eyes. This seems to be the first documented case of a concomitant CAR and retinal phlebitis.

Under the light microscope, the retina was examined from the posterior pole to the periphery. In some areas there was an abrupt disappearance of photoreceptor cells. This finding reflects the visual field defect in our patient. Electron microscopic studies performed by other workers revealed that the retinal pigment epithelium contained immature melanin granules within the melanolysosomes, thereby suggesting an abnormal melanin synthesis and resorption.<sup>4</sup> There were few melanin granules of the pigment retinal epithelium in our patient.

In almost all documented cases of CAR small cell carcinoma of the lung was present. A hormone-like substance produced by this tumour was thought to be the cause of the disease<sup>1</sup> and an autoimmune mechanism was suspected. The good response to systemic steroid in our patient supports this theory. The anti-retinal antibody in sera of our patient reacted

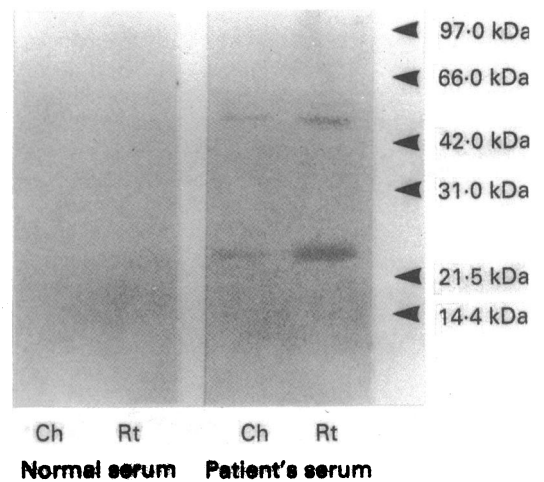


Figure 7 Western blots of patient's serum antibody reacting on normal human retina and choroid. Patient's antibody reacted mainly with retinal proteins of 24 and 48 kDa. Ch=choroid; Rt=retina.

with ganglion cells. Most of the previous reports suggested the existence of anti-photoreceptor cell antigens in this retinopathy. However, Kornguth *et al* reported the occurrence of anti-retinal ganglion cell antibodies in patients with small cell carcinoma of the lung.<sup>2,5</sup> The molecular weights of the anti-retinal ganglion or visual cells antigens in other patients were 205, 145, 65, 48, or 20–24 kDa, as determined by western blots. The molecular weights of the immunoglobulins in our patient were 48 and 24 kDa. The 48 kDa immunoglobulin is thought to be the retinal S antigen and the 24 kDa to be the recoverin-like protein.<sup>10</sup>

This case was presented at the 31st meeting of the European Ophthalmic Pathology Society at Strasbourg, France on 2 June 1992.

- 1 Sawyer RA, Shelhorst JB, Zimmerman LE, Hoyt WF. Blindness caused by photoreceptor degeneration as a remote effect of cancer. *Am J Ophthalmol* 1976; 81: 606–13.
- 2 Kornguth SE, Klein R, Appen R, Choate J. Occurrence of anti-retinal ganglion cell antibodies in patients with small cell carcinoma of the lung. *Cancer* 1982; 50: 1289–93.
- 3 Keltner JL, Roth AM, Chang S. Photoreceptor degeneration. Possible autoimmune disorder. *Arch Ophthalmol* 1983; 101: 564–9.
- 4 Buchanan TA, Gardiner TA, Archer DB. An ultrastructural study of retinal photoreceptor degeneration associated with bronchial carcinoma. *Am J Ophthalmol* 1984; 97: 277–87.
- 5 Grunwald GB, Klein R, Simmonds MA, Kornguth SE. Autoimmune basis for visual paraneoplastic syndrome in patients with small-cell lung carcinoma. *Lancet* 1985; i: 658–61.
- 6 Thirkill CE, Gerald PF, Sergott RC, Roth AM, Tyler NK, Keltner JL. Cancer-associated retinopathy (CAR syndrome) with antibodies reacting with retinal, optic-nerve, and cancer cells. *N Engl J Med* 1989; 321: 1589–94.
- 7 Jacobson DM, Thirkill CE, Tipping SJ. A clinical triad to diagnose paraneoplastic retinopathy. *Ann Neurol* 1990; 28: 162–7.
- 8 Keltner JL, Thirkill CE, Tyler NK, Roth AM. Management and monitoring of cancer-associated retinopathy. *Arch Ophthalmol* 1992; 110: 48–53.
- 9 Thirkill CE, Tait RC, Tyler NK, Roth AM, Keltner JL. The cancer-associated retinopathy antigen is a recoverin-like protein. *Invest Ophthalmol Vis Sci* 1992; 27: 68–72.
- 10 Laemmli UK. Cleavage of structural proteins during the assembly of the head of bacteriophage T4. *Nature* 1970; 227: 680–5.