

LETTERS TO THE EDITOR

Calcification-like echographic pattern in uveal melanomas treated with brachytherapy

EDITOR,—In a consecutive series of 1300 patients with uveal melanomas treated with brachytherapy ($^{106}\text{Ru}/^{106}\text{Rh}$ plaques),¹ three patients developed unusual echographic findings following radiation. Pretreatment echographic evaluation showed homogeneous tumour echoes with low inner reflectivity.

The patients were a 48-year-old woman, a 63-year-old man, and a 73-year-old woman. Before treatment the maximum tumour heights were 6.9 mm, 7.7 mm, and 6.2 mm respectively. The first patient received two courses of radiation with 1360 and 1000 Gy scleral contact dose within 15 months and an additional laser coagulation 6 months later. The other patients were treated once with scleral contact doses of 700 and 1000 Gy respectively. Highly reflective echoes with posterior shadowing were detected 5, 7, and 2 years after radiation in regressive residual tumours with a height of 2.7 mm, 1.2 mm, and 1.7 mm respectively (Figs 1, 2).

An increase of reflectivity usually occurs in melanomas following radiation therapy.^{2,3} However, very high reflectivity and marked posterior shadowing are very characteristic signs of calcification and have not been described previously. Histological findings following radiation therapy include tumour

necrosis, haemorrhages, and lymphocytic infiltration but calcifications have not been observed.^{4,5}

Two hypotheses may explain the unusual findings. Either the intraocular tumour in our patients was misdiagnosed or calcification may occur in regressive uveal melanomas. In all patients the ophthalmoscopic diagnosis of a uveal melanoma was consistent with the fluorescein angiography and echographic findings, which makes a misdiagnosis unlikely.⁶ Other ocular tumours presenting with calcification are retinoblastomas and osteomas, which can be excluded based on the age of the patients and clinical findings. Calcification typically occurs in necrotic areas for example, in retinoblastomas calcification most probably starts in the mitochondria of degenerating tumour cells.^{7,8} Although histological evidence cannot be presented in the successfully treated eyes of our patients, it is most likely that calcification has occurred in their necrotic residual tumours.

ULRICH KELLNER
MICHAEL H FOERSTER
*Freie Universität Berlin,
Klinikum Steglitz,
Augenklinik,
Berlin,
Germany*

NORBERT BORNFIELD
*Zentrum für Augenheilkunde,
Universität Essen,
Essen,
Germany*

- 1 Foerster MH, Bornfeld N, Schulz U, Wessing A, Meyer-Schwickerath G. Complications of local beta radiation of uveal melanomas. *Graefes Arch Clin Exp Ophthalmol* 1986; 230: 336–40.
- 2 Guthoff R, von Domarus D, Steinhorst U, Hallermann D. 10 Jahre Erfahrung mit der Ruthenium-106/Rhodium-106-Behandlung des malignen Melanoms der Aderhaut-Bericht über 264 bestrahlte Tumoren. *Klin Monatsbl Augenheilkd* 1986; 188: 576–83.
- 3 Eichler C, Hertel A, Lommatzsch P, Fuhrmann P. Echographische Befunde vor und nach β -Bestrahlung ($^{106}\text{Ru}/^{106}\text{Ru}$) von Aderhautmelanomen. *Klin Monatsbl Augenheilkd* 1987; 190: 17–20.
- 4 MacFaul PA, Morgan G. Histopathological changes in malignant melanomas of the choroid after cobalt plaque therapy. *Br J Ophthalmol* 1977; 61: 221–8.
- 5 Messmer E, Bornfeld N, Foerster MH, Schilling H, Wessing A. Histopathologic findings in eyes treated with a ruthenium plaque for uveal melanoma. *Graefes Arch Clin Exp Ophthalmol* 1992; 230: 391–6.
- 6 The Collaborative Ocular Melanoma Study Group. Accuracy of diagnosis of choroidal melanomas in the Collaborative Ocular Melanoma Study, COMS report No 1. *Arch Ophthalmol* 1990; 108: 1268–73.
- 7 Spencer WH, ed. *Ophthalmic pathology: an atlas and textbook*. 3rd ed. Philadelphia: Saunders, 1985: 14–5.
- 8 Lin CCL, Tso MOM. An electron microscopic study of calcification of retinoblastoma. *Am J Ophthalmol* 1983; 96: 765–74.

Herpetic corneal ulcers in Malawi

EDITOR,—There have been reports of large numbers of herpetic corneal ulcers in Tanzania,^{1,2} particularly in association with measles or a history of malaria. As with many of these reports, we also must rely on clinical appearance and response to therapy for diagnosis of herpetic ulcers and we also find that the majority of these are geographic or stromal. However, our experience in Malawi is that herpetic ulcers are relatively uncommon. Malawi has a good system of ophthalmic medical assistants, active in every district. They successfully treat many bacterial corneal ulcers and refer non-healing ulcers or those they suspect of being herpetic to the central

hospitals. Thus, we would expect to see a disproportionately large number of herpetic ulcers compared to bacterial ulcers in the central hospitals. In Malawi, febrile illnesses are common (malaria is holoendemic and measles epidemics still occur) and the seroprevalence of HIV is one of the highest in Africa. All these factors would be expected to contribute to a large number of herpetic ulcers, if herpes simplex were common in the population. None the less, at the Queen Elizabeth Central Hospital, which serves the population of five million in the southern region, fewer than 10% of the corneal ulcers are presumed to be herpetic. Among the 250 children admitted to the measles ward from March 1992 to January 1993 there were no patients with corneal ulceration or herpetic mouth ulcers. Similarly, among 350 children with cerebral malaria admitted to the Malaria Research Project over the past 6 years none has had corneal ulceration or herpetic mouth ulcers. (TE Taylor, ME Molyneux, personal communication.) Although these data are not population based, they suggest that herpes simplex is not common in this population.

There is good documentation of the high prevalence of herpetic corneal ulcers in Tanzania and Nigeria.³ However, the epidemiology of herpes simplex in Africa may still be too unclear to justify the assumption that it is a common cause of corneal blindness throughout the continent.

SUSAN LEWALLEN
M C CHIRAMBO
*Queen Elizabeth Central Hospital,
PO Box 2273,
Blantyre,
Malawi*

- 1 Foster A, Sommer A. Corneal ulceration, measles, and childhood blindness in Tanzania. *Br J Ophthalmol* 1987; 71: 331–43.
- 2 Yorston D, Foster A. Herpetic keratitis in Tanzania: association with malaria. *Br J Ophthalmol* 1992; 76: 582–5.
- 3 Sandford-Smith JH, Whittle HC. Corneal ulceration following measles in Nigerian children. *Br J Ophthalmol* 1979; 63: 720–4.

Glaucoma screening

EDITOR,—We were very pleased to see Mr Hitching's editorial on glaucoma screening in the June edition of the journal. Readers might like to know that the RNIB figures quoted were obtained from the *RNIB Survey into Blind and Partially Sighted Adults in Britain*, 1991 (HMSO) by Ian Bruce, Aubrey McKennell and Errol Walker. A second volume is also available on the blind and partially sighted children in Britain.

SUE GRINDEY
*RNIB Health Services Unit,
224 Great Portland Street,
London W1N 6AA*

Gillespie syndrome reported as bilateral congenital mydriasis

EDITOR,—Richardson and Schulenberg¹ reported a 2½-year-old girl with bilateral congenital mydriasis, developmental delay, and an atrophic vermis of the cerebellum. The family have recently consulted me and I would like to suggest that this child has Gillespie syndrome, which is characterised by the triad of cerebellar ataxia, partial aniridia, and developmental delay. Gillespie syndrome is distinct from reports of autosomal dominant congenital mydriasis without other complications.^{2,3}

The first report of this phenotype is usually attributed to Gillespie⁴ who described a brother and sister sib pair and suggested autosomal

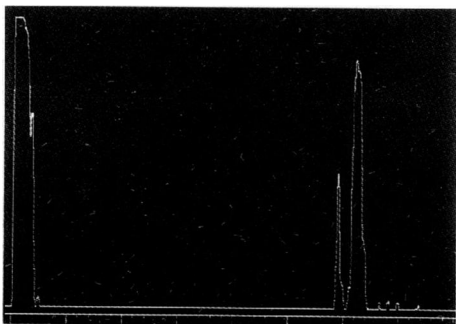


Figure 1 Echographic A-scan of regressive uveal melanoma 2 years after brachytherapy. The sensitivity is reduced to 35 dB (standard tissue sensitivity 61 dB). On the right the smaller first spike indicates the anterior surface of the residual tumour. The second spike indicates very high reflectivity within the tumour, the echoes of the sclera and orbita posterior to this signal are markedly diminished.

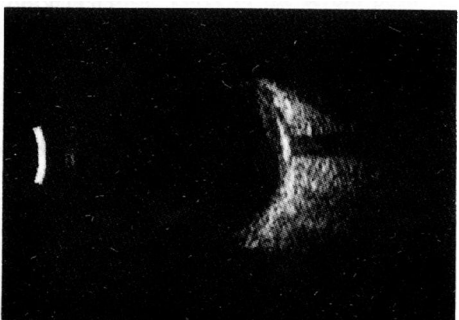

Figure 2 Echographic B-scan of the same eye at the same time as Figure 1. A highly reflective area can be seen within the residual tumour. Posterior to this area a marked shadowing is present.

recessive inheritance. The condition has been assigned the McKusick catalogue number 206700.⁵

Several authors have added single case reports to the literature.^{6,7,8} Sibling pairs have also been reported^{9,10}; in neither case was consanguinity noted. Crawford *et al*¹¹ reported a family with three affected members; a brother and sister had Gillespie syndrome; the sister later married an unrelated healthy male and had an affected son. The authors suggested that the sister had married a heterozygote carrier and that provisionally the disorder should still be regarded as autosomal recessive. An alternative explanation of autosomal dominant plus reduced penetrance, with most affected individuals not reproducing, cannot be totally excluded.¹⁰

In conclusion, parents of an affected child should still be advised of a one in four recurrence risk. Further cases should continue to be described in the literature.

O QUARRELL
North Trent Clinical Genetics Service,
Centre for Human Genetics,
117 Manchester Road,
Sheffield S10 5DN

- Richardson P, Schulenberg WE. Bilateral congenital mydriasis. *Br J Ophthalmol* 1992; 76: 632-3.
- White VW, Fulton MN. A rare pupillary defect inherited by identical twins. *J Hered* 1937; 28: 177-80.
- Caccamise WC, Townes PL. Bilateral congenital mydriasis. *Am J Ophthalmol* 1976; 81: 515-7.
- Gillespie FD. Aniridia, cerebellar ataxia and oligophrenia in siblings. *Arch Ophthalmol* 1965; 73: 388-91.
- McKusick VA. *Mendelian inheritance in man*. Baltimore: Johns Hopkins Press, 1991.
- Sarsfield JK. The syndrome of congenital cerebellar ataxia, aniridia and mental retardation. *Develop Med Child Neurol* 1971; 13: 508-11.
- Lechtenberg R, Ferretti C. Ataxia with aniridia of Gillespie: a case report. *Neurology* 1981; 31: 95-7.
- Nevin NC, Lin JHK. Syndrome of partial aniridia, cerebellar ataxia and mental retardation in Gillespie syndrome. *Am J Med Genet* 1990; 35: 468-9.
- Francois J, Lentine F, De Ronk F. Gillespie syndrome. *Ophthalmol Paediatr Genet* 1984; 1: 29-32.
- Wittig EO, Moreira CA, Friere-Moia N, Vianna-Morgante A. Partial aniridia, cerebellar ataxia and mental deficiency (Gillespie syndrome) in two brothers. *Am J Med Genet* 1988; 30: 703-8.
- Crawford M d'A, Harcourt RB, Shaw PA. Non-progressive cerebellar ataxia, aplasia or pupillary zone of iris, and mental subnormality (Gillespie's syndrome) affecting 3 members of a nonconsanguineous family in 2 generations. *J Med Genet* 1979; 16: 373-8.

Reply

EDITOR.—We are grateful to Dr Quarrell for suggesting a more specific diagnosis of Gillespie's syndrome in the case we reported. She presented with developmental delay, partial aniridia, and was late in achieving her motor milestones. Cerebellar ataxia was not confirmed on clinical examination and it was felt she did not fulfil the characteristic triad of Gillespie's syndrome. An atrophic vermis and dilated fourth ventricle was reported by Nevin and Lin¹ in a case of Gillespie's syndrome. These changes were present in our case, supporting Dr Quarrell's argument.

The syndrome is rare but should be considered in the differential diagnosis of cases presenting with congenital aniridia to allow genetic counselling.

W E SCHULENBURG
The Western Ophthalmic Hospital,
Marylebone Road,
London NW1 5YE

- Nevin NC, Lin JHK. Syndrome of partial aniridia, cerebellar ataxia and mental retardation in Gillespie syndrome. *Am J Med Genet* 1990; 35: 468-9.

An intralenticular foreign body and a clear lens

EDITOR.—We would like to draw your attention to the following case which we feel is of interest.

A 21-year-old mechanic presented with a red, uncomfortable eye and blurred vision, 3 days after noticing an object hit his left eye while working in a slate pit. There was a sealed, laceration of the central cornea, and a puncture wound of the overlying anterior lens capsule. A large intralenticular slate fragment was observed towards the lens equator (Fig 1). The

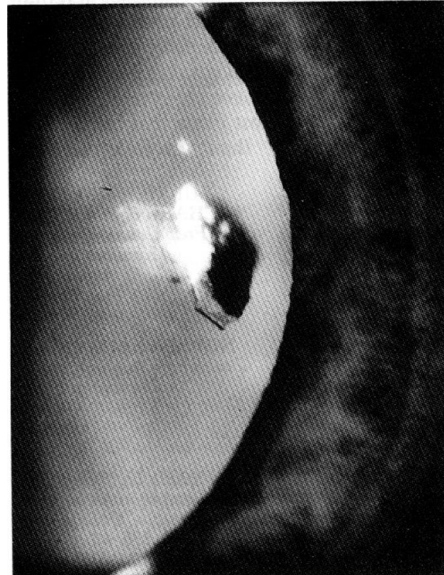

Figure 1 Slit image photograph demonstrating the intralenticular particle of slate at 1 year.

posterior capsule and the retina were unaffected. The fragment was left in situ, since slate is chemically inert.¹ At 1 year, his visual acuity was 6/6. The anterior capsule wound had healed (Fig 2), but the lens has not opacified (Fig 3).

In 5% of cases of perforating ocular injuries with retained intraocular foreign bodies, the foreign body lodges in the lens,² which usually becomes opaque and requires cataract extraction for visual rehabilitation.^{1,3} Documented

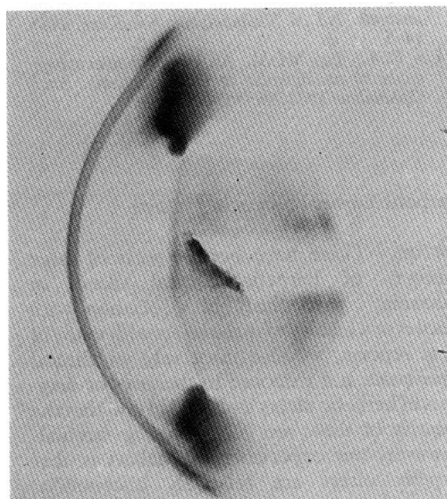


Figure 2 Scheimpflug photograph demonstrating the reformation of the anterior lens capsule with the intralenticular foreign body in the anterior cortex at 3 months.

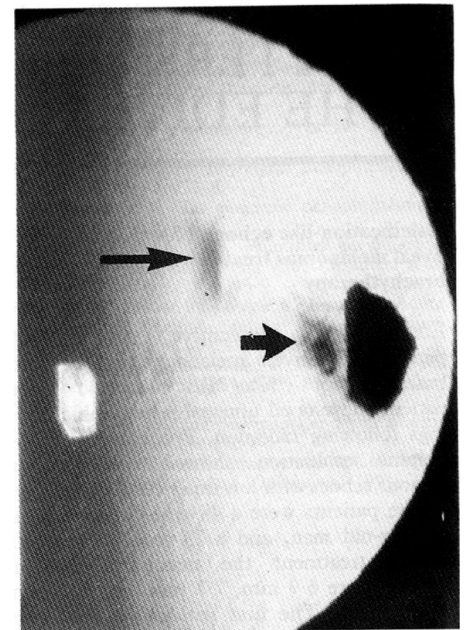


Figure 3 Retroillumination photograph showing the slate particle against the red reflex at 1 year. The thin arrow shows the corneal scar and the thick arrow shows the anterior capsule scar, but the red reflex is otherwise clear.

cases of retained intralenticular foreign bodies are either associated with mature cataracts, or localised lens opacities.⁴ Unprogressive, localised lenticular opacities, such as capsular scars, opacities along the track of the injury, or posterior subcapsular opacities have also been described following penetrating injuries with small sharp objects such as needles.¹ The healing capacity of the anterior lens capsule, in contrast to the posterior capsule, is well documented and is thought to be due to the presence of the subcapsular epithelium.^{1,5} Epithelial proliferation creates a plug which seals the wound. The plug reduces as new capsule is formed, and reconstituted lens fibres fill in the track. We believe that our patient did not develop a significant opacity because the posterior capsule was intact, and the entry site was small and linear, allowing the breached capsule to seal itself rapidly. We believe that this case is of interest since it is extremely rare to find reports of intralenticular foreign bodies with minimal opacification,⁶ and it is normal practice to remove such lenses. By electing to wait and observe the outcome, we have avoided surgery with the subsequent refractive problems that can occur in young patients.

We thank Mr Awdry and Mr Cheng for allowing us to report this case.

A J E FOSS
J E FORBES
J MORGAN
Oxford Eye Hospital,
Walton Street,
Oxford OX2 6HE

- Duke-Elder S, MacFaul PA. Injuries. Part 1: Mechanical. *System of Ophthalmology*. Vol 14. London: Kimpton, 1972: 352-502.
- Coleman DJ, Lucas BC, Rondeau MJ, Chang S. Management of intraocular foreign bodies. *Ophthalmology* 1987; 94: 1647-53.
- Fisher RF, Wakely J. Changes in lens fibres after damage to the lens capsule. *Trans Ophthalmol Soc UK* 1976; 96: 278-84.
- Blatt N. The tolerance of the crystalline lens to metallic foreign bodies. *Am J Ophthalmol* 1930; 13: 132-8.
- Uga S. Wound healing in the mouse lens. *Exp Eye Res* 1981; 32: 175-86.
- Keeney A. Intralenticular foreign bodies. *Arch Ophthalmol* 1971; 86: 499-501.