

193 nm excimer laser sclerostomy in pseudophakic patients with advanced open angle glaucoma

Bruce D S Allan, Paul P van Saarloos, Richard L Cooper, Ian J Constable

Abstract

A modified open mask system incorporating an en face air jet to dry the target area during ablation and a conjunctival plication mechanism, which allows ab externo delivery of the 193 nm excimer laser without prior conjunctival dissection, has been developed to form small bore sclerostomies accurately and atraumatically. Full thickness sclerostomies, and sclerostomies guarded by a smaller internal ostium can be created. A pilot therapeutic trial was conducted in pseudophakic patients with advanced open angle glaucoma. Six full thickness sclerostomies (200 μm and 400 μm diameter) and three guarded sclerostomies were created in nine patients by 193 nm excimer laser ablation (fluence per pulse 400 mJ/cm^2 , pulse rate 16 Hz, air jet pressure intraocular pressure +25 mm Hg). After 6 months' follow up, intraocular pressure was controlled (≤ 16 mm Hg) in eight of the nine patients (6/9 without medication). Early postoperative complications included hyphaema (trace – 2.5 mm) (6/9), temporary fibrinous sclerostomy occlusion (4/9), profound early hypotony (all patients without fibrinous occlusion), and suprachoroidal haemorrhage in one case. Conjunctival laser wounds were self sealing. Small bore laser sclerostomy procedures are functionally equivalent to conventional full thickness procedures, producing early postoperative hypotony, with an increased risk of suprachoroidal haemorrhage in association with this. Further research is required to improve control over internal guarding in excimer laser sclerostomy before clinical trials of this technique can safely proceed.

(*Br J Ophthalmol* 1994; 78: 199–205)

Conventional glaucoma filtration surgery has two principal areas of poor control: the reproducibility of fistular dimensions, and the extent of tissue trauma.¹ The argon fluoride excimer laser at 193 nm has been shown, in corneal excisions,^{2,3} to perform exceptionally well in both these areas removing less than 1 μm of tissue with each pulse and leaving virtually no adjacent tissue damage.

These qualities are underutilised in partial external trabeculectomy,^{4,5} in which a 2.0 \times 0.8 mm rectangular scleral fistula, guarded internally by a residual partial thickness layer of trabecular meshwork, is created by ab externo 193 nm excimer laser ablation. Formal preparatory conjunctival dissection and episcleral cautery are required to expose the sclera before ablation. This negates much of the theoretical advantage of using the 193 nm excimer laser to minimise

tissue trauma in the remainder of the procedure, and leaves the risk of conjunctival wound leakage undiminished. Swabs are used to dry the base of the scleral channel at the end of ablation. Ablation depth and the resultant resistance to aqueous outflow are thus variable. Iris prolapse, hypotony, and anterior chamber shallowing have been reported.^{6,7}

We have designed a new approach to the delivery of the 193 nm excimer laser for glaucoma filtration surgery, which eliminates preparatory conjunctival dissection. A modified open mask⁸ (Fig 1) is used to define a small bore sclerostomy created by ablation ab externo. The mask

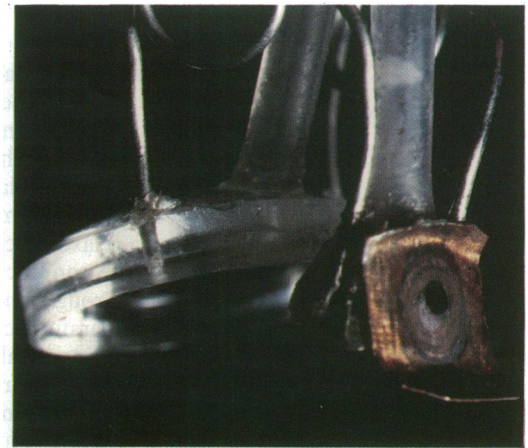


Figure 1A The modified open mask used in excimer laser sclerostomy viewed from the side. The mask is stabilised on the eye by a corneal vacuum ring (right) connected to the main component (left) by a spring steel hinge. The impression left by repeated ablations is seen on the outer shield of the main component surrounding the secondary aperture.

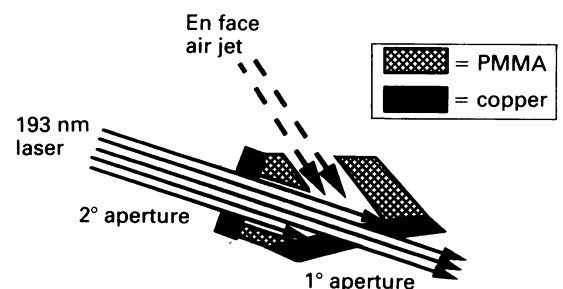


Figure 1B A schematic illustration of a midline section through the main component of the modified open mask used in 193 nm excimer laser sclerostomy. The laser is concentrically aligned through the (outer) secondary and (inner) primary apertures to control the angle of sclerostomy entry. The mask is designed to produce a sclerostomy entering the anterior chamber approximately in the coronal plane, locating the internal ostium in clear cornea well clear of the iris to minimise the likelihood of iris incarceration. Sclerostomy size is defined by the primary aperture. A jet of air (sterilised by passage through a 0.45 μm millipore filter (Millipore, Bedford, MA)) is directed en face into the primary aperture. This raises the ambient pressure in the target area during ablation, preserving haemostasis and preventing aqueous flooding. It also cools the mask during ablation.

The Lions Eye Institute,
Perth, Western Australia
B D S Allan
P P van Saarloos
R L Cooper
I J Constable

Correspondence to:
Bruce Allan, Moorfields Eye
Hospital, City Road, London
EC1V 2PD.

Accepted for publication
17 August 1993

Figure 2A In 193 nm excimer laser sclerostomy the conjunctiva is maintained in plication at the limbus by an open mask during through and through ablation *ab externo* (AC=anterior chamber). (From Allan et al¹² published by permission of Kugler publications.)

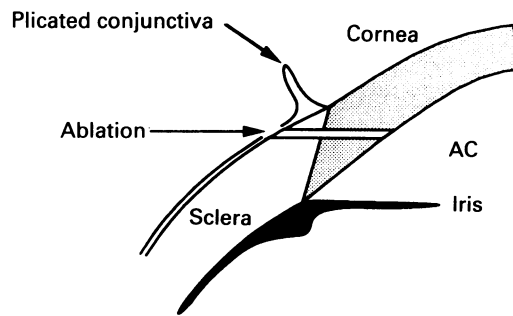
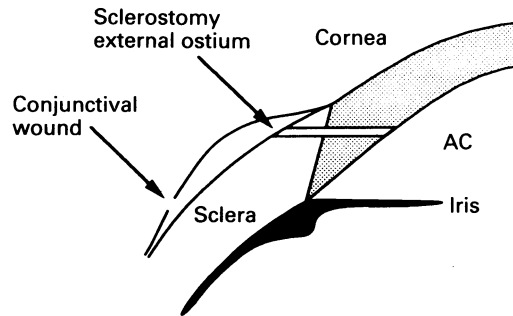


Figure 2B Removal of the mask at the end of ablation allows the conjunctiva to relax, separating the conjunctival wound from the sclerostomy. The small conjunctival wound is self-sealing, and a bleb forms (AC=anterior chamber). (From Allan et al¹² published by permission of Kugler publications.)



incorporates an en face air jet which raises ambient pressure in the target area. This acts to promote haemostasis and prevent aqueous flooding during ablation. The conjunctiva is plicated at the limbus before ablation (Fig 2A). At the end of the procedure the mask is removed and the conjunctiva relaxes back to its original position, separating the conjunctival and scleral wounds created by through and through ablation (Fig 2B). No preparatory conjunctival dissection is required. Conjunctival wounds produced by $\leq 500 \mu\text{m}$ mask apertures were found to be self-sealing in rhesus monkeys with experimental glaucoma.⁹ After encouraging results from 193 nm excimer laser sclerostomy (ELS) in this animal model, a pilot therapeutic trial in pseudophakic patients with advanced open angle glaucoma was commenced, and is described below.

Methods and materials

PATIENT SELECTION

Ethical approval for a human trial of 193 nm excimer laser sclerostomy was granted by the human rights committee of the University of Western Australia. Informed consent for excimer laser sclerostomy was obtained from pseudophakic patients with open angle glaucoma for whom filtration surgery was felt to be indicated because of progressive field loss or inadequate medical control of intraocular pressure (IOP). All patients had advanced glaucomatous optic nerve damage (cup/disc ratio ≥ 0.8 and an absolute scotoma). Additional selection criteria required that the conjunctiva was sufficiently mobile to permit plication at the proposed ablation site (that is, not fixed by cicatrization from previous surgery), and that the patient had retained good vision in the contralateral eye.

STUDY DESIGN

Clinical procedures were reviewed critically after each case, and updated where necessary. As this was a pilot trial involving a small number of patients, protocol modifications were determined by clinical judgment rather than inferential statistical analysis. Sclerostomy dimensions and the postoperative 5-fluorouracil regimen were modified during the trial on this basis.

BASELINE EXAMINATION

Automated perimetry (Humphrey (San Leandro, CA, USA) 24-2 or 10-2) and applanation tonometry were performed 1 week and 1 day before excimer laser sclerostomy. Baseline examination also included measurement of the anterior chamber depth with ultrasound pachymetry (Jedmed, St Louis, MO, USA) and anterior segment photography. Gonioscopy was performed to exclude vascular anomalies or peripheral anterior synechiae at the proposed ablation site. Phospholine iodide induced miosis in over half the patients treated precluded routine preoperative photographic optic disc measurement.

EXCIMER LASER SCLEROSTOMY (ELS)

Low volume retrobulbar anaesthesia (2.5 ml of 1% lignocaine) was supplemented with a van Lint orbicularis block and the 1 minute application of a cotton wool pledget soaked in 1% amethocaine, placed beneath the upper lid over the superior rectus insertion. With the patient positioned beneath the operating microscope (built into the laser delivery system) in an adjustable chair reclining at approximately 45° , the inclination of the head rest was adjusted to ensure that the path of the vertically delivered laser beam to the superior limbus would comfortably clear the patient's brow. The chair was then temporarily rotated away from beneath the laser to allow antiseptic preparation (5% povidone iodine), draping, the placement of a self-retaining speculum, and a superior rectus stay suture (5/0 silk) (Fig 3A). Sterile adhesive tape was used to hoist the brow as part of the draping procedure. The rectus suture was used to rotate the eye inferolaterally until the iris was approximately in the coronal plane. The patient was then repositioned beneath the laser, and a modified open mask was placed by the operator (Fig 3B), with the microscope graticule (indicating the beam centre), the secondary and the primary mask aperture concentrically aligned.

Using a Questek model 2820 ArF (193 nm) excimer laser with a delivery system¹⁰ configured to produce an even distribution of energy across a 1.5 mm rotating beam at the mask surface, ablation proceeded at a fluence per pulse of 400 mJ/cm^2 and a pulse repetition rate of 16 Hz, with an en face air jet pressure of IOP +25 mm Hg. Energy levels¹¹ and air jet pressure⁷ were checked before each procedure as previously described. Two masks were used throughout the trial, with ethylene oxide sterilisation between cases. The primary aperture sizes were 250 μm and 400 μm .

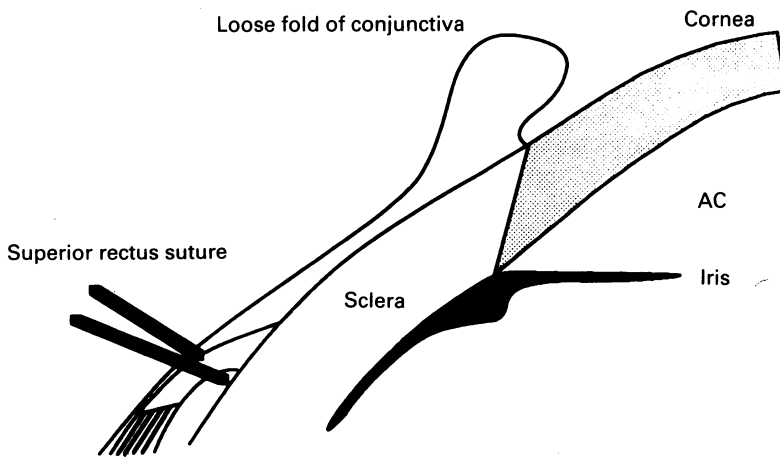
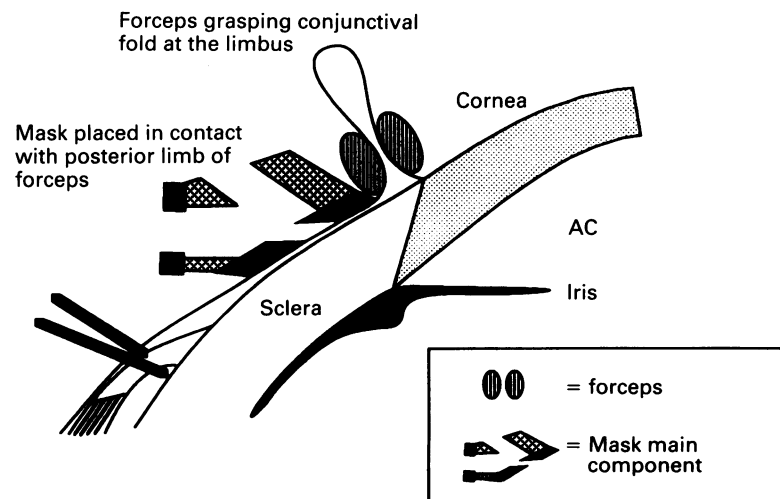


Figure 3A A fold of conjunctiva was grasped using non-toothed (Moorfields) forceps anterior to the superior rectus insertion before placement of the stay suture. A loose fold of conjunctiva was thus anchored, between the rectus insertion and the limbus, by the superior rectus suture (AC=anterior chamber).

Ablation was continued for 1000 pulses beyond initial perforation in the first six cases (two at 250 μm ; and four at 400 μm), aiming to create a full thickness penetration in which the internal ostium diameter matched the diameter of the main shaft of the sclerostomy.¹² In the last three cases, ablation (400 μm primary aperture) was stopped at the moment of perforation, leaving a smaller diameter internal ostium. Retroillumination through the cornea was used to provide the optimal view of the base of the forming sclerostomy through the operating microscope. Perforation was marked by a sudden change in the appearance of the base of the sclerostomy, sometimes accompanied by the appearance of an air bubble in the anterior chamber. En face air jet pressure was reduced slowly until aqueous welled up within the sclerostomy confirming perforation. In later cases, air jet pressure was then increased until the sclerostomy was free of fluid, and left to tamponade any transected blood vessels for an additional period (about 5 minutes) to promote haemostasis. Following this, air jet pressure was again reduced to approximately 10 mm Hg. The superior rectus suture was removed, and Kelman-MacPherson forceps were used to pull the conjunctiva posteriorly beneath the mask, clearing the conjunctival wound from the sclerostomy. Finally, the mask was removed by reversing the vacuum acting through the corneal suction ring.

Figure 3B The position of the external ostium with respect to the conjunctival insertion was standardised by placing the main component of the mask in contact with the posterior limb of Kelman-MacPherson forceps, which were used to grasp the conjunctival fold at its base (AC=anterior chamber).



POSTOPERATIVE MANAGEMENT

A large diameter bandage contact lens¹³ (Procornea, Amsterdam – 20.5 mm; or Flexlens, Denver – 19.5 mm), was placed immediately after mask removal, using irrigation with sterile balanced salt solution through a Bishop-Harman cannula to remove trapped air from beneath the lens. These large diameter lenses were left in situ between examinations until the IOP had risen above 5 mm Hg and choroidal detachments had resolved. If an epithelial defect was present at this stage, a conventional (12.5 mm diameter) therapeutic bandage contact lens was used until epithelial cover was complete.

Unpreserved prednisolone drops 0.5%, and chloramphenicol 0.5% were instilled each 5 minutes for half an hour, then each hour (while the patient was awake) for 24 hours, and four times a day 2–3 months postoperatively. Atropine drops 1% were instilled twice daily until the IOP exceeded 5 mm Hg.

5-Fluorouracil (5-FU) injections were administered according to one of two protocols. Each dose (2.5 mg/0.1 ml) was administered through a 30 gauge needle introduced adjacent to the filtration bleb, and massaged across the bleb area. After each injection, the fornices and cornea were irrigated with balanced salt solution before replacement of the large diameter bandage contact lens. In the first protocol, a total of six injections (15 mg)¹⁴ were administered in the first 2 weeks after ablation, beginning on the first postoperative day (day 1), with additional injections every 2 to 3 days thereafter. Injections were stopped if signs of corneal epithelial toxicity (punctate epithelial keratopathy, or an epithelial defect) were evident. In the second protocol, introduced with the aim of reducing the duration of early postoperative hypotony, the first injection was delayed¹⁵ until the intraocular pressure exceeded 10 mm Hg.

Tissue plasminogen activator (tPA) was used routinely where fibrinous occlusion of the internal ostium of the sclerostomy was evident (a clot seen gonioscopically in the internal portion of the sclerostomy) or inferred (from the disappearance of a bleb in the absence of iris prolapse) in the first postoperative week. Initially, tPA (25 $\mu\text{g}/0.1$ ml) was injected subconjunctivally¹⁶ as described above for 5-FU. If drainage had not re-established after 48 hours a second and final injection (25 $\mu\text{g}/0.1$ ml) was administered intracamerally.¹⁷

POSTOPERATIVE EXAMINATION

Patients were admitted for observation if a hyphaema was evident on examination 1 hour after the procedure. Otherwise patients were discharged, and examined on day 1, with regular outpatient examinations thereafter. In addition to applanation tonometry, slit-lamp examination of the anterior segment, gonioscopy, and indirect ophthalmoscopic examination of the posterior segment; ultrasound pachymetric assessment of anterior chamber depth was repeated wherever manifest shallowing of the anterior chamber was observed. Anterior segment photography, to document the evolution of bleb morphology, was performed on day 2, at

Table 1 Summary of results after 6 months

Case	5-FU	Hypotony	Complications	Outcome
1 400 µm 81 F (PXE) Meds 2	2.5 (1)	40	AC shallowing, epith erosions	Success, diffuse bleb
2 400 µm 65 M (PXE) Meds 3 2x Trab	10 (3-12)	0	Hyphaema, clot block	Qualified success, diffuse bleb, Meds 1
3 400 µm 78 F (OAG) Meds 3	12.5 (5-17)	5	Hyphaema, clot block, epith defect	Success, diffuse bleb
4 250 µm 80 F (PXE) Meds 4	10 (10-16)	6	Hyphaema, suprachor haem	Failure, flat bleb
5 250 µm 75 F (PTG) Meds 3	7.5 (8-17)	5	Hyphaema	Qualified success, flat bleb, Meds 2
6 400 µm 71 M (OAG) Meds 4 1x Trab	15 (1-14)	18	Hyphaema, conjunctival leak, AC shallowing, iris prolapse	Success, cystic bleb
7 400 (G) 75 F (OAG) Meds 3	10 (1-10)	0	Hyphaema, clot block, epith defect	Success, diffuse bleb
8 400 (G) 86 F (PTG) Meds 3	12.5 (1-14)	14	Clot block	Success, cystic bleb
9 400 (G) 77 F (OAG) Meds 3	12.5 (1-12)	14	Epith defect	Success, diffuse bleb

Key: column 1 *case* - case number, sclerostomy diameter (µm) (400 (G)=400 µm diameter sclerostomy with ablation stopped at the moment of perforation to produce a smaller internal ostium), age, and sex of patient, type of glaucoma (OAG=primary open angle glaucoma, PXE=pseudoexfoliation, PTG=post-traumatic glaucoma), Meds=number of antiglaucomatous medications; trab=previous failed trabeculectomy; column 2 *5-FU* - total dose of 5-FU (mg) (postoperative day of first dose-day of last dose); column 3 *Hypotony* - duration of early postoperative hypotony (IOP ≤5 mm Hg with choroidal detachment) in days; column 4 *Complications* - epith=corneal epithelial, clot block=temporary occlusion of the sclerostomy with clotted blood; suprachor haem=suprachoroidal haemorrhage; column 5 *Outcome* - success= IOP ≤21 mm Hg without medication; qualified success=IOP ≤21 mm Hg with less antiglaucomatous medication than preoperatively; failure=IOP ≥21 mm Hg with medication.

2 weeks, and at the end of each month post-operatively. Automated perimetry was repeated after 3 months.

Results

The results and complications of ELS in the nine patients treated are summarised in Table 1. Penetration was achieved after an average of 3404 pulses (range 1000-7800 pulses; about 1-8 minutes).

FILTRATION FUNCTION

Average preoperative IOP was 27.5 mm Hg (range 19-35 mm Hg). After 6 months' follow up IOP was controlled (≤16 mm Hg) without medication (success) in six patients at an average level of 10.5 mm Hg (range 6-14 mm Hg), and controlled with less medication than preoperatively (qualified success) in two patients. The remaining patient had no evidence of filtration after day 12, and the IOP remained uncontrolled thereafter despite the resumption of preoperative medication. This eye subsequently had a successful trabeculectomy. A pressure of 16 mm Hg was chosen as a target level of IOP control on the basis of evidence showing progression of field loss where IOP exceeds this level.¹⁸

VISUAL FUNCTION

Snellen visual acuity had returned to the pre-operative level in all patients after 3 months. Temporary decreases in visual acuity relating to corneal epithelial disturbance after 5-FU injections were seen in four patients. Preoperative and 3 months postoperative automated visual

field examinations were similar, with no significant change in the global indices in any of the cases.

COMPLICATIONS

Profound early postoperative hypotony (IOP ≤5 mm Hg) and annular choroidal detachments were seen in seven cases. Fibrinous occlusion of the sclerostomy on day 1 was seen in the remaining two cases (cases 2 and 7, Table 1) in which hypotony did not occur.

Hyphaemas (trace - 2.5 mm) were seen in six cases. Fibrinous occlusion of the sclerostomy occurred in four cases. In two cases (cases 2 and 7) occlusion was evident by day 1, and in two cases occlusion occurred as a result of secondary bleeding (case 3 on day 8; case 8 on day 4). Spontaneous resolution of fibrinous occlusion occurred in one case (case 8) after 24 hours. The response to tPA injection in the remaining cases was as follows: case 2 - subconjunctival injection (day 2) led to clot resolution after 12 hours but with active bleeding from the sclerostomy site resulting in a further occlusion, intracameral injection (day 5) then resulted in clot resolution, again with active bleeding from the sclerostomy but no further occlusion; case 3 - subconjunctival injection (day 4) led to clot resolution after 24 hours with an increased hyphaema but no further occlusion; case 7 - the clot remained after subconjunctival and intracameral injections but was dislodged successfully (day 10) by Nd:YAG laser (44 pulses at 4 mJ).

Conjunctival laser wounds were all self sealing by day 1 (Fig 4), and were displaced from the external ostium of the sclerostomy by approximately 4-8 mm. Seidel testing revealed conjunctival wound leakage at the site of the superior rectus suture in case 7. This persisted until shortly after 5-FU injections were terminated on day 14. Anterior chamber shallowing (minimum axial depth=2.0 mm; about 50% shallowing) occurred between day 3 and day 14 in this case, with iris prolapse on day 4. Iris prolapse was successfully reversed by pilocarpine drops 4%, followed 1 hour later by argon laser iridoplasty (40 pulses, spot size 100 µm, pulse duration 0.2 seconds, power 650 mW), and Nd:YAG laser (33 pulses; energy 6 mJ) applied directly to the incarcerated iris. Iris prolapse occurred in this case despite the presence of a pre-existing iridectomy.

Anterior chamber shallowing was only seen in one other case (case 1; minimum axial depth 2.5 mm; about 37% shallowing). This was precipitated by removal of the large diameter bandage contact lens on day 4, and reversed within 2 days by replacement of the lens on day 5.

Discussion

PATIENT SELECTION

Pseudophakic patients were chosen as a study group in this pilot trial of ELS because the results of trabeculectomy in this group are relatively poor,^{19,20} and iris prolapse has been reported as a frequent complication of laser

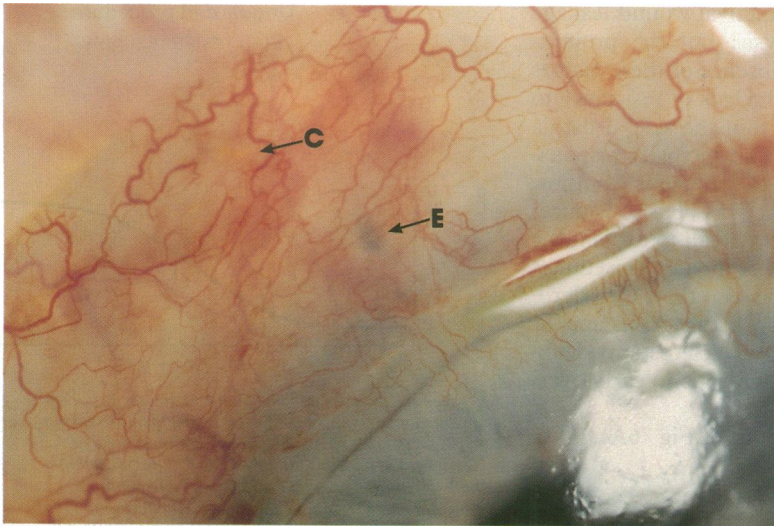


Figure 4A The appearance of the ablation site on day 1 (case 1). Free blood is seen beneath the conjunctiva around the external ostium (arrow E). The sealed conjunctival wound is virtually invisible (arrow C).

sclerostomy in phakic cases.²¹ All patients had advanced glaucomatous optic nerve damage, and may thus have stood to benefit from a lower IOP level than that normally attained in a conventional guarded filtration procedure. Patients with rubeotic or uveitic glaucoma were excluded in order to maintain a degree of homogeneity in the study group, and simplify comparison with other techniques.

FILTRATION FUNCTION

Excessive subconjunctival wound healing is the predominant cause of failure in glaucoma filtration surgery.¹⁹ Procedures which minimise subconjunctival tissue dissection and thermal necrosis may improve filtration function by attenuating the stimulus to subconjunctival cicatrization after surgery.²²⁻²⁴ Although a superior rectus suture is used, the surgical field should still be virtually devoid of necrotic tissue after ELS.^{2,4,12,25} This contrasts with holmium laser sclerostomy for which thermal damage zones of up to 1.6 mm²⁶ and thermally induced conjunctival, corneal, iris, and lens lesions have

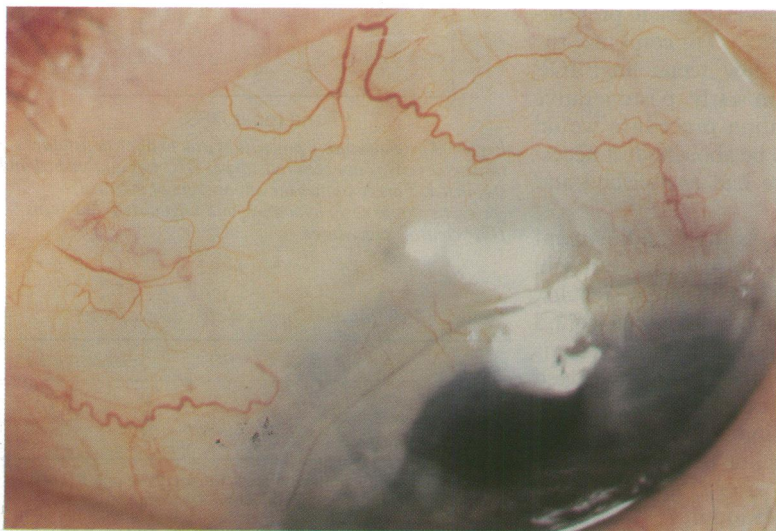


Figure 4B The same eye at 3 months showing a diffuse translucent bleb. Bleb morphology was variable (Table 1).

been reported.²¹ Thermal damage zones produced by 'hot wire' radiofrequency diathermy systems²⁷ of sclerostomy formation are no larger than those observed for the holmium laser with the current delivery system. Diathermy systems are relatively inexpensive, and produce no percussive damage.

Good IOP control was achieved in 8/9 of our patients at 6 months, although filtration in case 5 (qualified success at 6 months) has since failed. These early results are approximately equivalent to the human results from other techniques of laser sclerostomy^{1,21} and trabeculectomy^{19,20} in a similar patient group. A larger scale controlled trial would be required to evaluate the influence of minimising tissue trauma on filtration function, and improved control over haemostasis and hypotony would be required before this could proceed.

HAEMOSTASIS

The price for cutting without adjacent thermal tissue damage is the lack of any simultaneous cauterising effect. The holmium laser²¹ and hot wire systems^{27,28} of sclerostomy formation create sufficient surrounding thermal coagulation to largely prevent primary bleeding. This effect is totally absent for the 193 nm excimer laser. Other lasers with relatively confined thermal damage zones, including erbium²⁹ and picosecond YLF³⁰ lasers, are also non-haemostatic. Hyphaemas are seen in 18-53% of cases after trabeculectomy, depending upon the technique used.³¹ Haemostasis does appear to be improved significantly in ELS by pausing with the mask in situ and the air jet switched on, to maintain a period of positive pressure tamponade in a dry sclerostomy, after the completion of ablation. The total period of tamponade during the procedure (about 10 minutes) should then exceed the bleeding time for small vessels transected during ablation. This protocol modification was introduced for the last two patients in the series, neither of whom developed a hyphaema. Tissue plasminogen activator may be unnecessary in cases of temporary fibrinous occlusion. Provided that antimetabolites are successful in preventing fibroblasts invading and organising the clot, spontaneous resolution can be expected.

HYPOTONY

There is a relatively high incidence (6% - 10/162) of suprachoroidal haemorrhage complicating pseudophakic filtration procedures,³² and post-operative hypotony may increase the risk of this sight threatening complication.³³ A suprachoroidal haemorrhage occurred in one case in our series, and occurred in 14% (7/49) patients after holmium laser sclerostomy at another centre.³⁴ This evidence has led us to suspend human studies of ELS until control over internal guarding can be improved. Hypotony may also encourage filtration failure by promoting breakdown of the blood-aqueous barrier and increasing the aqueous concentration of high molecular weight, fibroblast stimulating proteins.^{35,36}

Early hypotony after full thickness filtration surgery might previously have been attributed,

at least partially, to conjunctival wound leakage or inadvertent cyclodialysis: but the prominence of hypotony in the absence of these factors after ELS confirms that the lack of resistance to aqueous outflow from within the scleral fistula itself (fistular resistance) is principally responsible. The resistance to aqueous outflow beneath the intact conjunctiva (bleb resistance) must also, initially, be very small to explain the observed early hypotony. Applying Poiseuille's formula³⁷ (Fig 5), it can be seen that, for sclerostomies $\geq 60 \mu\text{m}$ (approx), fistular resistance is negligible. All current laser sclerostomy techniques will thus be equally prone to early over-drainage.

In unguarded procedures (Fig 6A), IOP

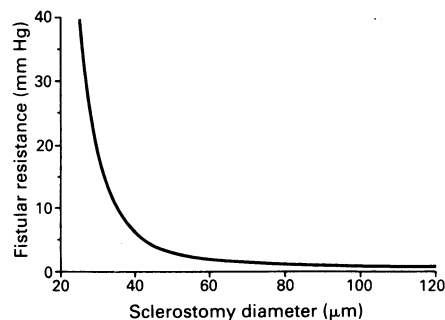


Figure 5 The relation between sclerostomy diameter and fistular resistance (expressed in terms of the pressure drop between the internal and external ostia) derived from applying Poiseuille's formula (pressure drop = $0.128 lQ/136 \pi d^4$ where l = sclerostomy length, Q = aqueous flow rate, and d = sclerostomy diameter)³⁶ to a tubular sclerostomy 1.2 mm in length at an aqueous flow rate of 2 $\mu\text{l}/\text{min}$. Sclerostomies $\geq 60 \mu\text{m}$ impart very little resistance to aqueous outflow. Hence all current laser sclerostomy procedures will produce a period of early postoperative hypotony.

typically rises to, and stabilises in, the 'low teens',¹⁹ as bleb resistance increases with limited subconjunctival wound healing and the formation of a definitive filtration bleb. This evolution, seen in a relatively pure form after ELS and other laser sclerostomy procedures in which wound leakage is absent and conjunctival dissection is minimal, is superimposed on a baseline level of fistular resistance in guarded procedures (Fig 6B), resulting typically in 'high teens' IOP control¹⁹ – which may be less effective in preventing progressive field loss.¹⁸ To combine the possible advantage of a low teens final IOP level and protection from early postoperative hypotony, the ideal filtration procedure would allow fistular resistance to be abolished, if necessary, once bleb resistance had established and stabilised (Fig 6C).

Trabeculectomy with suture adjustment (lysis/release) purports to do just this, but will inevitably fail to produce consistent results, because by the time subconjunctival wound healing has stabilised and bleb resistance is established, fibroblasts will already have fixed the scleral wound. Suturelysis at this point would make little impression, and earlier adjustment risks hypotony. Baseline fistular resistance is also poorly controlled after trabeculectomy. Early hypotony has been found in 76%²⁷ of cases using standard methods, and 25–64% (depending on the number of flap sutures placed initially)

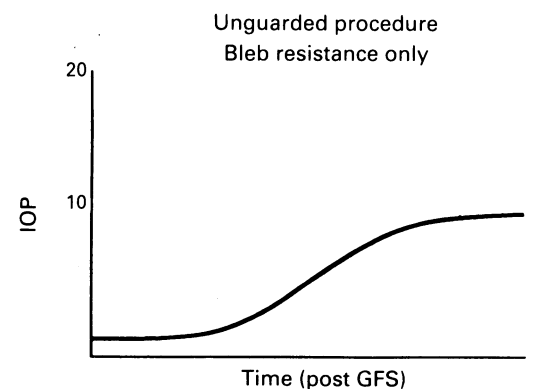


Figure 6A A notional curve illustrating the build up of intraocular pressure (IOP) after unguarded filtration surgery (GFS). Fistular resistance is, by definition, absent. Resistance to aqueous outflow beneath the conjunctiva (bleb resistance) rises to a stable level with limited subconjunctival wound healing, and the formation of a definitive filtration bleb. Intraocular pressure typically stabilises in the low teens after a period of early postoperative hypotony.

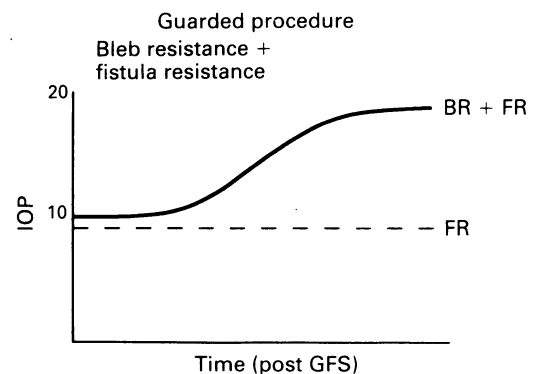


Figure 6B In guarded procedures, the evolution of bleb resistance (BR) is superimposed on a baseline level of fistular resistance (FR). Early postoperative hypotony is avoided; but intraocular pressure (IOP) typically stabilises in the high teens.

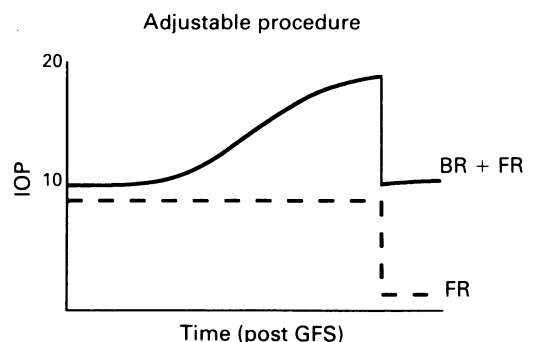


Figure 6C Adjustable procedures aim to abolish fistular resistance (FR) once bleb resistance (BR) has established and stabilised. This combines the advantages of guarded (protection from early hypotony) and unguarded (low teens IOP control) procedures.

Table 2 Poor filtration function after delayed 5-FU

Outcome	Delayed 5-FU	Standardised 5-FU
Failure	1	0
Qualified success	2	0
Success	1	5

After prolonged hypotony in case 1, the first dose of 5-FU was delayed until IOP ≥ 10 mm Hg. Results were inconsistent, however, and after case 5 a standardised low dose regimen, with injections commencing on postoperative day 1, was adhered to regardless of hypotony. The numbers of patients in each functional outcome group are given.

in the largest published series³⁸ in which laser suture lysis was routinely used.

In ELS, stopping ablation at the moment of perforation leaves the sclerostomy guarded by a smaller internal ostium.¹² Both human³⁹ and animal⁹ histological studies indicate that wound healing after laser sclerostomy is confined to the external, episcleral portion of the sclerostomy. Gonioscopy in case 4 showed the internal ostium had remained patent at least 2 months after filtration failure. Guarding internally should thus, in contrast to trabeculectomy, divorce the site of guarding from the site of wound healing, allowing effective late abolition of fistula resistance by Nd:YAG expansion of the internal ostium ab interno.

In our original protocol patients were randomised to receive either a 250 µm or a 400 µm full thickness sclerostomy, using large diameter 'filtration control' contact lenses routinely. It became apparent, however, that although large diameter bandage soft contact lenses may have afforded some protection against shallowing of the anterior chamber in these pseudophakic patients, profound hypotony remained. The smaller bore (250 µm) of sclerostomies in cases 4 and 5 may have contributed to filtration failure; and while delaying the first dose of 5-FU may have reduced the duration of postoperative hypotony, filtration failures occurred where 5-FU was not introduced on day 1 (Table 2). Sclerostomy dimensions were therefore modified after case 6, with cessation of ablation at the moment of perforation, aiming to produce an internally guarded 400 µm sclerostomy. A period of hypotony still occurred in two out of three cases, however (cases 8 and 9). Precise control over the initial internal ostium size is required to set the correct baseline level of fistular resistance in this approach. Simply arresting ablation at the moment of apparent perforation using the current ablation parameters in ELS does not provide this; but additional ablation is clearly unnecessary. Delivery of the 193 nm excimer laser can be modified to leave a thin layer of tissue in the base of a scleral fistula,⁴⁵ or to excise a small volume of tissue with fine dimensional control.⁴⁰ We are currently exploring the delivery system modifications required to produce consistent, reversible guarding in ELS.

Presented in part at the Royal Australian College of Ophthalmologists Annual Scientific Meeting, Sydney, November 1992, and at the Association for Research in Vision and Ophthalmology Annual Meeting, Sarasota, Florida, 1993.

Ian North FRACO and Philip House FRACO provided valuable advice and assistance in this project.

- Allan BDS, van Saarloos PP, Cooper RL, Constable IJ. Laser microsclerostomy for primary open angle glaucoma: a review of laser mechanisms and delivery systems. *Eye* 1992; 6: 257-63.
- Marshall J, Trokel S, Rothery S, Kruger RR. A comparative study of corneal incisions induced by diamond and steel knives and two ultraviolet radiations from an excimer laser. *Br J Ophthalmol* 1986; 70: 482-501.
- Marshall J, Trokel S, Rothery S, Schubert H. An ultrastructural study of corneal incisions induced by an excimer laser at 193 nm. *Ophthalmology* 1985; 57: 749-58.
- Seiler T, Kriegerowski M, Bende T, Wollensak J. Partielle externe trabekulektomie. *Klin Monatsbl Augenheilkd* 1989; 195: 216-20.
- Seiler T, Kriegerowski M, Patmore A, Marshall J. Partial external trabeculectomy with the excimer laser; an experimental investigation of a new treatment for glaucoma. *Laser Light Ophthalmol* 1990; 3: 97-109.
- Kuwayama Y, Takagi T, Tanaka M, Takeuchi R. 193 nm partial external trabeculectomy. *Invest Ophthalmol Vis Sci* 1992; 33 (ARVO suppl): 1635.
- Traverso CE, Murialdo U, Di Lorenzo G, Venzano D, De Palma G, Gandolfo E, et al. Photoablative filtration surgery with the excimer laser for primary open angle glaucoma: a pilot study. *Int Ophthalmol* 1992; 16: 363-5.
- Allan BDS, van Saarloos PP, Cooper RL, Constable IJ. Excimer laser sclerostomy: the in vitro development of a modified open mask delivery system. *Eye* 1993; 7: 47-52.
- Allan BDS, van Saarloos PP, Cooper RL, Keogh EJ, Constable IJ. 193 nm excimer laser sclerostomy using a modified open mask delivery system in rhesus monkeys with experimental glaucoma. *Graefes Arch Clin Exp Ophthalmol* 1993; 231: 662-6.
- van Saarloos PP, Constable IJ. An improved excimer laser photorefractive keratectomy system. *Lasers in Surgery and Medicine* 1993; 5: 121-30.
- Van Saarloos PP, Constable IJ. Bovine corneal stroma ablation rate with 193 nm excimer laser radiation: quantitative measurement. *Refractive and Corneal Surgery* 1990; 6: 424-9.
- Allan BDS, van Saarloos PP, Cooper RL, Constable IJ. Excimer laser sclerostomy: an in vitro study of dimensional reproducibility. *Lasers and Light in Ophthalmology* 1993; 5: 121-30.
- Blok MDW, Kok JHC, van Mil C, Greve E, Kijlstra A. Use of the megasoft bandage lens for the treatment of complications after trabeculectomy. *Am J Ophthalmol* 1990; 110: 264-8.
- Ziel CJ, Johnstone MA. Minidose 5-fluorouracil in primary trabeculectomy. *Invest Ophthalmol Vis Sci* 1992; 33 (ARVO suppl): 223.
- Krug JH, Melamed S. Adjunctive use of delayed and adjustable low-dose 5-fluorouracil in refractory glaucoma. *Am J Ophthalmol* 1990; 109: 412-8.
- Ortiz JR, Walker SD, McManus PE, Martinez LA, Brown RM, Jaffe GJ. Filtering bleb thrombolysis with tissue plasminogen activator. *Am J Ophthalmol* 1988; 106: 624-5.
- Tripathi RC, Tripathi BJ, Park JK, Quaranta L, Steinsaper K, Lehman E, et al. Intracameral tissue plasminogen activator for resolution of fibrin clots after glaucoma filtering procedures. *Am J Ophthalmol* 1991; 111: 247-8.
- Mao LK, Stewart WC, Shields MB. Correlation between intraocular pressure control and progressive glaucomatous damage in primary open angle glaucoma. *Am J Ophthalmol* 1991; 111: 51-5.
- Skuta GL, Parrish RK. Wound healing in glaucoma filtering surgery. *Surv Ophthalmol* 1987; 32: 149-70.
- The Fluorouracil Filtering Surgery Study Group. Fluorouracil filtering surgery one-year follow-up. *Am J Ophthalmol* 1989; 108: 625-32.
- Hoskins HD, Iwach AG, Drake MV, Dickens CJ. Subconjunctival THC:YAG ('Holmium') laser thermal sclerostomy ab externo. *Ophthalmology* 1993; 100: 356-66.
- Higginbotham EJ, Kao G, Peyman G. Internal sclerostomy with the Nd:YAG contact laser versus thermal sclerostomy in rabbits. *Ophthalmology* 1988; 95: 385-90.
- Hill RA, Ozler SA, Baerveldt G, Viscardi JJ, Keates RM, Lee M, et al. Ab interno neodymium:YAG versus erbium:YAG laser sclerostomies in a rabbit model. *Ophthalmic Surg* 1992; 23: 192-7.
- Allan BDS, Barrett GD. Combined small incision phacemulsification and trabeculectomy. *J Cataract Refract Surg* 1993; 19: 97-102.
- Marshall J. Lasers in ophthalmology: the basic principles. *Eye* 1988; 2 (suppl): 98-112.
- Perell HF, Patel AS, Rodrigues MM. Holmium laser scleral ostium size and thermal effect in relation to laser energy. *Invest Ophthalmol Vis Sci* 1992; 33 (ARVO suppl): 2862.
- Yue-Kong A, Reynolds MD, Chadalavada R, Misra RP. Bipolar cautery and internal thermal sclerostomy in a rabbit model. *Ophthalmic Surg* 1992; 23: 188-91.
- Preziosi CL. The electrocautery in the treatment of glaucoma. *Br J Ophthalmol* 1924; 8: 414-8.
- Ozler SA, Hill RA, Andrews JJ, Baerveldt G, Berns MW. Infrared laser sclerostomies. *Invest Ophthalmol Vis Sci* 1991; 32: 2498-503.
- Cooper HM, Schuman JS, Puliafito CA, McCarthy D, Woods WJ, Friedman N, et al. Picosecond Nd:YLF laser sclerectomy. *Am J Ophthalmol* 1993; 115: 221-4.
- Konstas AGP, Jay JL. Modification of trabeculectomy to avoid postoperative hyphaema. The guarded anterior fistula operation. *Br J Ophthalmol* 1992; 76: 353-7.
- The Fluorouracil Filtering Surgery Study Group. Risk factors for suprachoroidal haemorrhage after filtering surgery. *Am J Ophthalmol* 1992; 113: 501-7.
- Gressel MG, Parrish RK, Heuer DK. Delayed non-expulsive suprachoroidal haemorrhage. *Arch Ophthalmol* 1984; 102: 1757-61.
- Schuman JS, Stinson WG, Hutchinson T, Bellows AR, Puliafito CA, Lytle R. Holmium laser sclerostomy: success and complications. *Ophthalmology* 1993; 100: 1060-5.
- Joseph JP, Grierson IG, Hitchings RA. Chemotactic activity of aqueous humor. *Arch Ophthalmol* 1989; 107: 69-74.
- Addicks EM, Quigley HA, Green WR, Robin AL. Histologic characteristics of filtering blebs in glaucomatous eyes. *Arch Ophthalmol* 1983; 101: 795-8.
- Fleck BW. How large must an iridotomy be? *Br J Ophthalmol* 1990; 74: 583-8.
- Blok MDW, Greve EL, Dunneber EA, Muradin F, Kijlstra A. Scleral flap sutures and the development of shallow or flat anterior chambers after trabeculectomy. *Invest Ophthalmol Vis Sci* 1992; 33 (ARVO suppl): 2898.
- Shahinian L, Egbert PR, Williams AS. Histologic study of healing after ab interno laser sclerostomy. *Am J Ophthalmol* 1992; 114: 216-9.
- Lewis A, Palanker D, Hemo I, Pe'er J, Zauberman M. Microsurgery of the retina with a needle-guided 193 nm excimer laser. *Invest Ophthalmol Vis Sci* 1992; 33: 2377-81.