

Bungee jumping and intraocular haemorrhage

B K Jain, E M Talbot

Bungee jumping is becoming popular in the Western world. It originated in the South Pacific island of Pentecost. The designation of 'sport' began with the first jumps by the Dangerous Sports Club in Bristol, England, on April Fool's Day 1979.

As practised today bungee jumping usually involves wearing a vest that passes over the shoulders and between the legs and is attached to the bungee cord. When jumping head first, the load is distributed through the padded shoulder straps of the full body harness (inverted compression) or through both legs and hips (inverted traction) when using an ankle harness in conjunction with a body harness. The jumper dives off a platform suspended from a crane or hot air balloon 200 to 400 feet above the ground (see Fig 1). The jumper approaches but does not touch the ground, rebounds a significant distance, and falls once or twice again until the bounce is minimal. The jumper then is lowered to the ground or pulled back into the balloon. Bungee running and reverse bungee jumping are variations of bungee jumping.




Figure 1 Bungee jump.

Case report

A 22-year-old man presented with a history of blurred vision in the right eye immediately following a bungee jump on 28 August 1993. He jumped from a 200 foot high platform suspended from a crane (using an ankle harness in conjunction with a body harness). After coming to the ground he complained of blurred vision in the right eye. Before the jump he was very nervous following a loud cry and he held his breath as he jumped from the crane platform. He had not participated in a similar sport, or any other active sports. His general health has always been good.

On examination his best corrected visual acuity in the right eye (blurred vision) was 6/9 and 6/6 in the left eye. There was no relative afferent pupillary defect. Slit-lamp biomicroscopy showed anterior segments to be within normal limits; however, binocular indirect ophthalmoscopy showed subhyaloid haemorrhages nasal to the disc (see Fig 2A) and also in the inferior temporal quadrant below the inferior arcade which had ruptured through the internal

Figure 2 (A) Subhyaloid haemorrhage nasal to disc. (B) Intragel haemorrhage.

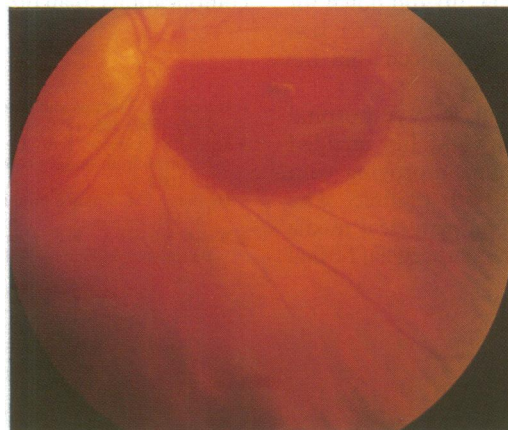


Fig 2A

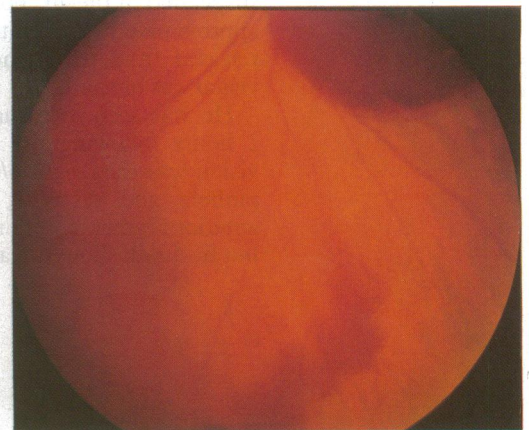


Fig 2B

Department of
Ophthalmology, Royal
Preston Hospital, Sharoe
Green Lane, Fulwood,
Preston PR2 4HT

B K Jain
E M Talbot

Correspondence to:
E M Talbot.

Accepted for publication
1 December 1993

Figure 3 (A) Resolving subhyaloid haemorrhage after 1 month. (B) Resolving intragel haemorrhage in the inferior quadrants after 1 month.

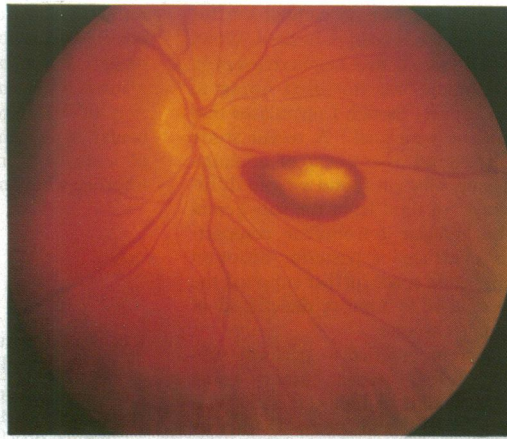


Fig 3A

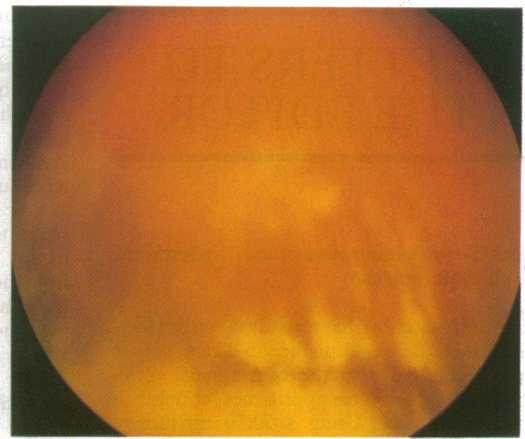


Fig 3B

limiting membrane into the vitreous gel inferiorly (Fig 2B). There was no other pathology (that is, retinal tear, dialysis) confirmed by 360 degree scleral depression examination. The intraocular pressure was 12 mm Hg on applanation tonometry. The patient was advised to rest in bed initially. When seen in the outpatient clinic a month later his blurred vision had resolved and he had visual acuity of 6/6, N6 in each eye. The subhyaloid and vitreous gel haemorrhages were resolving (Fig 3).

Comment

Intraocular haemorrhage caused by bungee jumping has not been reported before, although hormonal changes¹ and severe injuries like quadriplegia² from reverse bungee jumping and gluteal haematoma³ from bungee running have been reported.

It is well known that sudden increase in venous pressure can cause rupture of small capillaries and subhyaloid haemorrhage (Valsalva retinopathy). We suggest this young man's haemor-

rhage occurred by a similar mechanism – that is, a dive will increase, by gravity, venous return to the heart, and tense abdominal muscles against a closed glottis will increase venous pressure and reduce venous return from the head. This would cause retinal venous dilatation. The whole process would be aggravated during the terminal stage of the fall as the maximum tension in the bungee rope countered the effect of gravity on the body resulting in a maximal constricting effect of the body by the body harness.

Furthermore, during acute deceleration the kinetic energy of the liver may act as a headward plunger on the diaphragm, compressing the thoracic contents and so increasing the thoracic venous pressure further, and this would be transmitted to the head and neck veins. Considering the forces involved, it is surprising that ocular injuries have not been reported before.

- 1 Zimmerman U, Loew T, Wildt L. Stress hormones and bungee jumping. *Lancet* 1992; 340: 428.
- 2 Hite PR, Greene KA, Levy DI, Jackimczyk K. Injuries resulting from bungee-cord jumping. *Ann Emerg Med* 1993; 22: 1060–3.
- 3 Hallen MH. Bungee runner's buttock. *BMJ* 1992; 305: 1587.