

Oculocutaneous manifestations in xeroderma pigmentosa

J L Goyal, Vasudev Anand Rao, Renuka Srinivasan, Karoon Agrawal

Abstract

Xeroderma pigmentosum (XP) is a rare genetic disease characterised by defective DNA repair leading to clinical and cellular hypersensitivity to ultraviolet radiation. The oculocutaneous features of 10 patients with XP were studied retrospectively. General features included parental consanguinity (40%), familiarity (60%), onset of symptoms in first 2 years (50%), malignant skin neoplasms (60%), and carcinoma of the tongue (20%). Among the ocular features, 50% of patients presented with photophobia. Lid freckles or atrophic skin lesions were seen in all patients. Lower lid tumours were seen in 30%, chronic conjunctival congestion in 40%, corneal opacification in 40%, squamous cell carcinoma of limbus in 20%, bilateral pterygium in 40%, and visual impairment in 50%. The clinical features (ocular and cutaneous) of the cases are discussed.

(*Br J Ophthalmol* 1994; 78: 295-297)

Xeroderma pigmentosum (XP), a condition described by Hebra and Kaposi,¹ is a rare autosomal recessive genetic disorder which starts in early childhood and is characterised clinically by cutaneous photosensitivity, pigmentary changes, photophobia, and propensity for early development of malignancy in sun exposed mucocutaneous and ocular structures.^{2,3} The ocular changes include severe photophobia, conjunctivitis, corneal opacification, conjunctival

naevi, epibulbar and lid neoplasms. As this condition is rare, only isolated case reports of XP are found in the literature. From 1874 to 1982 – that is, in a span of 108 years, only 830 cases have been reported,² which means that an average of only eight cases are added to the literature each year world wide.

This study presents ocular and dermatological features of 10 cases of XP which presented to us during the past 8 years. The features have been compared with the largest world review of XP (830 cases) by Kraemer *et al.*²

Patients and methods

The case records of 10 patients with XP seen in the department of ophthalmology and plastic surgery between 1983 and 1990 have been reviewed with particular reference to the systemic and ocular features. The age and sex distribution, visual acuity, and clinical features have been studied.

Results

General features of XP with respect to the distribution of age, sex, family history, consanguinity, and age of onset of symptoms are given in Table 1. The presentation age varied from 2 to 40 years, the majority (80%) being less than 20 years. The age of onset of the first symptom varied from as early as 1 week to 20 years. Out of the 10 patients studied, seven were males and three were females. Consanguinity was seen in four and the family history was positive in six cases. The distribution of ocular features, cutaneous lesions, internal malignancy, and neurological abnormalities has been given in the table.

Discussion

To date the precise pathomechanism of XP is not known. In 1968, Cleaver was first to report that skin cells from patients with XP have an impaired ability to repair ultraviolet radiation-induced DNA damage.⁴ Defective repair replication was later reported in dermal fibroblasts, lymphocytes in the peripheral blood, and conjunctival cells.⁵ Ultraviolet radiation induces the formation of pyrimidine-pyrimidine dimers of two juxtaposed thymidines in the same strand. Normal DNA replication can subsequently take place only if such dimers are excised and the DNA strand repaired by a series of enzymatic reactions.⁶ This can be done either by excision repair or by photoactivation.⁷ Cells cultured from patients with XP exhibit low activity for the photoreactivation (photoactivated thymidine dimer cleavage process).⁷ The DNA excision

Departments of Ophthalmology and Plastic Surgery, Jawaharlal Institute of Postgraduate Medical Education and Research (JIPMER), Pondicherry-605 006, India

J L Goyal
V A Rao
R Srinivasan
K Agrawal

Correspondence to: Dr J L Goyal, Associate Professor of Ophthalmology, JIPMER, Pondicherry-605 006, India.

Accepted for publication 8 October 1993

Table 1 Oculocutaneous manifestations in xeroderma pigmentosa

Features	Patients									
	1	2	3	4	5	6	7	8	9	10
Age (years)	20	15	5	37	7	2	3	18	40	12
Sex	F	M	F	M	M	M	M	F	M	M
Age of onset of symptoms (years)	7	1.5	9/12	5	11/12	7/365	8/12	6	20	8
Family history*	-	-	+	+	+	+	-	+	+	-
Consanguinity	+	+	-	-	-	+	-	+	-	-
Ocular features:										
Impaired vision	-	+	+	-	+	+	-	-	+	+
Lid freckles	+	+	+	+	+	+	+	+	+	+
Lower lid tumours	-	+	+	-	+	-	-	-	-	-
Lower lid ectropion	-	+	+	-	+	-	-	-	-	-
Photophobia	+	+	-	-	+	+	-	-	+	-
Conjunctival congestion or pigmentation	-	-	-	-	+	+	-	-	+	+
Limbal tumour	+	-	+	-	-	-	-	-	-	-
Corneal opacity with vascularisation	-	-	+	-	+	+	-	-	+	+
Pterygium	+	-	-	-	-	-	-	+	+	+
Cutaneous features:										
Atrophic skin changes and pigmented freckles	+	+	+	+	+	+	+	+	+	+
Squamous cell carcinoma	+	+	+	-	+	+	-	-	-	-
Basal cell carcinoma	+	-	+	+	+	-	-	-	-	-
Malignant melanoma	-	-	-	-	+	-	-	-	-	-
Other lesions:										
Carcinoma of tongue	-	-	+	-	+	-	-	-	-	-
Internal malignancy	-	-	-	-	-	-	-	-	-	-
Neurological abnormalities	-	-	-	-	-	-	+	-	-	-

- = Absent; + = present.

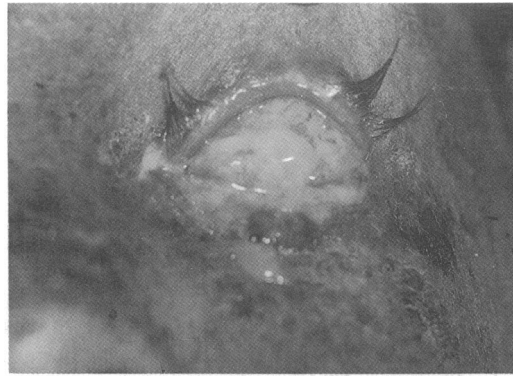

Figure 1 Xeroderma pigmentosum case with extensive growth of epibulbar squamous cell carcinoma eroding the cornea, conjunctiva, and the lower lid.

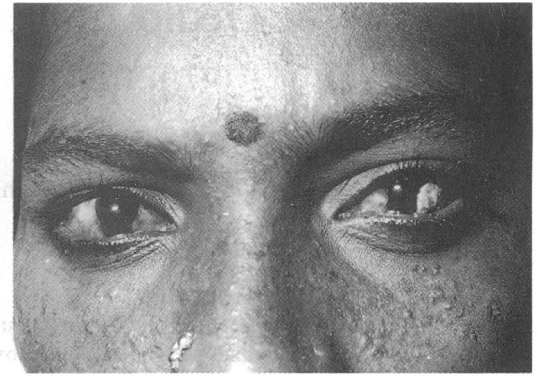


Figure 2 Case showing minimal xeroderma pigmentosum changes of the lower lid, bilateral nasal pterygium, and limbal tumour in the left eye.

repair process in XP is quite complex. There are 10 genetic complementation groups, out of which nine are deficient in excision repair (xeroderma pigmentosum group A to I) while one group exhibits defective post-replication repair (xeroderma pigmentosum variant).² Owing to impaired ability to repair, defective or damaged DNA is retained. Retention of this damaged DNA leads to heritable chromosomal mutations and cell death which possibly cause neoplastic and atrophic clinical abnormalities in XP.^{3,8}

Xeroderma pigmentosum has a prevalence rate of 1:250 000.^{2,3} XP being an autosomal recessive disease, the heterozygous parents are clinically normal and both sexes are equally affected. Parents of all our cases were clinically normal and seven out of 10 patients were males. Not much significance can be attached to this sex distribution because the number is small. Parental consanguinity which is important in any autosomal recessive disorder was noted in 40% of our XP patients compared with 31% reported in Kraemer's series.² The symptoms and signs are usually evident by the end of the first year or the beginning of the second year of age.⁹ In our study only half the patients had onset of symptoms in the first 2 years of life. One case presented with the onset of symptoms at the age of 20 years, which is rare (case 9).

Cutaneous changes in XP include increased photosensitivity, pigmentation, malignant and atrophic skin lesions. The reason for increased ultraviolet sensitivity has remained unexplained. A similar type of sun sensitivity has been observed in porphyrias and aminoaciduria (for example, Hartnup disease, tryptophanuria, and hydroxykynureninaemia) wherein, because of loss of porphyrins and essential amino acids, a pellagrous disorder results. However, in XP no such humoral substances have been demonstrated consistently.¹⁰ Malignant skin neoplasms have been reported in 45% of XP patients,² however in our study they were seen in 60%. All except one of our patients with malignancy (case 4) were under 20 years of age. Skin neoplasms included squamous cell carcinoma, basal cell carcinoma, and malignant melanoma (Table 1). Carcinoma of the tongue which is supposed to be due to a significant amount of ultraviolet radiation from sunlight reaching the tip of the tongue, has been reported in 13 out of 830 cases (1.6%) by Kraemer *et al.*,² and in our study it was seen in two out of 10 patients (cases 3 and 5). Although the incidence of internal neoplasms is said to be

10 to 20 times higher in XP than in the normal population,⁸ none of our patients had any internal malignancy. XP patients are generally free from neurological abnormalities,² but in our series there was one patient who presented with mental retardation and microcephaly in association with XP (case 7).

Among the ocular tissues the lids, conjunctiva, and cornea are predominantly affected because they are exposed to ultraviolet radiation from sunlight. Sparing of iris, lens, and posterior segment was attributed to shielding of these structures from ultraviolet radiation by the eyelids, cornea, and lens.²

The earliest ocular symptom of XP is photophobia which has been reported in 21% of patients,² and was seen in 50% of our cases. It has been observed that photophobia is more commonly seen in younger individuals than in adults.³ The reason for this is not known. The mechanism of photophobia in XP also is not clearly understood. In general, photophobia is a feature of keratitis but in these patients photophobia is seen even without any obvious corneal lesions.

The skin of the eyelids, like skin elsewhere in the body, shows pigmentation, atrophy, loss of lashes, ectropion, and loss of lids (Fig 1). The involvement of the lids is seen in more than 80% of reported cases¹¹ and in our study lid freckles and atrophic skin changes of eyelids were seen in all patients. Cutaneous freckles and hyperpigmented spots represent clones of individual melanocytes altered by mutations induced by ultraviolet radiation.¹² Three of our patients

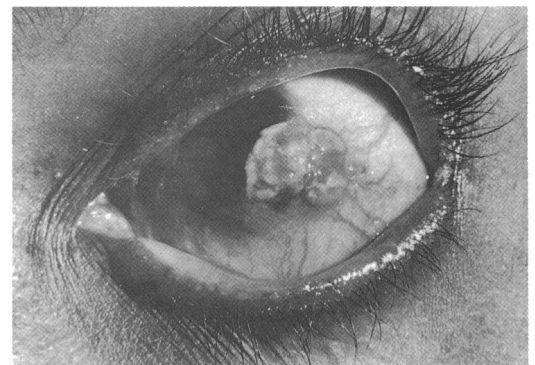


Figure 3 Same case (Fig 2) showing vascularised limbal growth encroaching on to the cornea and conjunctiva.

developed squamous and basal cell carcinomas of the lower lid (cases 1, 3, and 5). The upper lid changes were either absent or much less compared with the lower lid (Fig 2). This we feel may be due to the relative protection of the upper lid from ultraviolet radiation from sunlight by the overhanging superior orbital margin.

Conjunctival involvement which includes telangiectasia, xerosis, chronic conjunctival congestion, and pigmentation are most prominently seen in sun exposed interpalpebral fissure and have been reported in 18% of patients.² In our study these features were found in four out of 10 patients (40%).

The cornea in XP may show dryness, exposure keratitis, hazyness, band-like nodular keratopathy, scarring, ulceration, and even perforation resulting in corneal opacities and vascularisation.² This has been reported in 17% of the patients by Kraemer.² In our study they were seen in four out of 10 patients (40%). According to Applegate and Ley, DNA damage is involved in the induction of opacification and neovascularisation of the cornea by ultraviolet rays.¹³ They reported that the effect of photoreactivation (removal of pyrimidine dimers by exposure) on both opacification and neovascularisation in the opossum was found to be protective when used within a few days of ultraviolet exposure. This suggested a direct role of pyrimidine dimers in the corneal opacification and neovascularisation by chronic ultraviolet damage as in XP. Corneal transplants in these patients will have limited success in view of corneal vascularisation, xerosis, and in some patients, inadequate lid coverage.

Pterygium (Fig 2) was a common finding in our XP patients (40%). The significance of ultraviolet radiation in the pathogenesis of pterygium has already been emphasised.¹⁴ Hence, it is possible that the risk of developing pterygium in an already ultraviolet radiation prone XP eye is increased.

Ocular surface neoplasms, including squamous cell carcinoma (most frequent), basal cell carcinoma, and melanoma, occur with a predilection for the limbal area.² In our series epibulbar neoplasms (Figs 1, 2, and 3) were seen in two patients (20%) while Kraemer *et al* have reported an incidence of 11% in their survey.² In both our patients (cases 1 and 3) the tumour extended to the cornea and conjunctiva (Figs 1 and 3). In one of these, exenteration was also done because of the extensive growth of the tumour.

Iris involvement in XP is uncommon. It includes stromal atrophy, especially of the inferior half,¹⁵ pigment alteration, iritis, and iris melanoma.¹⁶ The superior one third of the iris is generally shielded by the upper lid.¹⁶ Although the normal cornea is virtually opaque to electromagnetic radiation with wavelengths of less than 300 nm, it readily transmits ultraviolet radiation longer than 300 nm^{17,18} which will reach the iris and can cause iris melanoma.¹⁶ The crystalline lens further prevents near ultraviolet radiation (300–400 nm) from reaching the fundus, hence the posterior segment is protected.¹⁸ Among our patients none had any iris involvement.

Visual impairment in XP patients is attribut-

able to several causes such as corneal opacities, pterygium, tumour invasion from the limbus, and corneal vascularisation. The incidence of visual impairment has been reported to be 12%² but in our study significant visual loss (visual acuity of less than 6/36) was seen in half the patients.

General management of XP patients includes protection from ultraviolet radiation, early excision of neoplasms, and genetic counselling. Eye care consists of sunglasses, artificial tears, steroid drops, and bland ointment at night. Surgical treatment includes excision of neoplasms, release of symblepharon, and keratoplasty for corneal opacification.^{19,20} Photophobia and ocular irritation in patients exposed to ultraviolet irradiation are relieved with eye drops containing quinoline derivatives.²¹ Ultraviolet absorbing contact lenses have been shown to offer protection for light induced retinopathy.²² Their use can also be possibly extended to patients with XP to protect them from ultraviolet damage to the cornea and iris. Oral retinoic acid has also been claimed to be helpful in these patients.²

As XP patients have potential blinding complications, an ophthalmologist must be involved from the beginning in the care of these patients.

- 1 Hebra F, Kaposi M. On diseases of the skin including exanthemata. *New Sydenham Soc* 1874; 61: 252–8.
- 2 Kraemer KH, Lee MM, Scotto J. Xeroderma pigmentosum – cutaneous, ocular and neurologic abnormalities in 830 published cases. *Arch Dermatol* 1987; 123: 241–50.
- 3 Robbins JH, Kraemer KH, Lutzner MA, Festoff BW, Coon HG. Xeroderma pigmentosum. *Ann Intern Med* 1974; 80: 221–48.
- 4 Cleaver JE. Defective repair replication of DNA in XP. *Nature* 1968; 218: 652–6.
- 5 Newsome DA, Kraemer KH, Robbins JH. Repair of DNA in xeroderma pigmentosum conjunctiva. *Arch Ophthalmol* 1975; 93: 660–2.
- 6 Watson JD. *Molecular biology of the gene*. 3rd ed. Menlo Park, CA: Benjamin Cummings, 1976: 244–5.
- 7 Murray RK, Granner DK, Mayes PA, Rodwell VW. DNA organisation and replications. In: *Harper's biochemistry*. 21st ed. Norwalk, CA: Appleton & Lange, 1988: 401–2.
- 8 Robbins JH. Xeroderma pigmentosum: defective DNA repair causes skin cancer and neurodegeneration. *JAMA* 1988; 260: 384–8.
- 9 Andrade R, Gumport SL, Popkin GI. Cancer of the skin. In: *Xeroderma pigmentosum*. Philadelphia: Saunders, 1976: 573–95.
- 10 Reed WB, Landing B, Sugarman G, Cleaver JE, Melnyk J. Xeroderma pigmentosum, clinical and laboratory investigations of its basic defect. *JAMA* 1969; 207: 2073–9.
- 11 Duke-Elder S. Diseases of the outer eye. In: *System of ophthalmology*. St Louis: Mosby, 1965; Vol 8: 551.
- 12 Robbins JH. Significance of repair of human DNA: evidence from studies of xeroderma pigmentosum. *J Natl Cancer Inst* 1978; 61: 645–55.
- 13 Applegate LA, Ley RD. DNA damages involved in the induction of opacification and neovascularisation of the cornea by ultraviolet light. *Exp Eye Res* 1991; 52: 493–7.
- 14 Duke-Elder S. Diseases of the outer eye. In: *System of ophthalmology*. St Louis: Mosby, 1965; Vol 8: 575.
- 15 Fischer E, Thielmann HW, Neundorfer B, Rentsch FJ, Edler L, Jung EG. Xeroderma pigmentosum patients from Germany; clinical symptoms and DNA repair characteristics. *Arch Dermatol Res* 1982; 274: 229–47.
- 16 Johnson MW, Skuta GL, Kincaid MC, Nelson CC, Wolter JR. Malignant melanoma of the iris in xeroderma pigmentosum. *Arch Ophthalmol* 1989; 107: 402–7.
- 17 Lerman S. Ocular phototoxicity. In: Davidson SI, Fraunfelder FT, eds. *Recent advances in ophthalmology*. New York: Churchill Livingstone, 1985: 109–36.
- 18 Boettner EA, Wolter JR. Transmission of the ocular media. *Invest Ophthalmol Vis Sci* 1962; 1: 776–83.
- 19 Jung EG. Xeroderma pigmentosum. *Int J Dermatol* 1986; 25: 629–33.
- 20 Hertle RW, Durso F, Metzler JP, Varsa EW. Epibulbar squamous cell carcinomas in brothers with xeroderma pigmentosa. *J Pediatr Ophthalmol Strabismus* 1991; 28: 350–3.
- 21 Florani M, Malaguti C, Boero A, Germogli R. The treatment of photophobia and ocular irritations caused by intense light. *Ann Otolomol Clin Oculist* 1990; 116: 85–9.
- 22 Lao GU, Chuanoico RU. Ophthalmic instruments; their ultraviolet hazards. *Philipp J Ophthalmol* 1990; 19: 142–7.