

patient 2 reported by Eckstein *et al.* This could also be the case for patient 1 if, as we presume, she had received corticotherapy. This represents an alternative explanation for the occurrence of CSR in patients with SLE.

EVRYDIKI A BOUZAS
Ophthalmology Department,
Red Cross Hospital,
Erythrou Stavrou Street,
Athens, Greece

GEORGE MASTORAKOS
Developmental Endocrinology Branch,
National Institute of Child Health and
Human Development,
National Institutes of Health,
Bethesda, MD, USA

- 1 Eckstein MB, Spalton DJ, Holder G. Visual loss from central serous retinopathy in systemic lupus erythematosus. *Br J Ophthalmol* 1993; 77: 607-9.
- 2 Bouzas EA, Scott MH, Mastorakos G, Chrousos GP, Kaiser-Kupfer MI. Central serous chorioretinopathy in endogenous hypercortisolism. *Arch Ophthalmol* 1993; 111: 1229-33.

Reply

EDITOR,—I would like to thank E A Bouzas and G Mastorakos for their interest in our paper. In the September issue of the *Archives of Ophthalmology* they described three out of 60 patients with Cushing's syndrome who developed a central serous retinopathy during the course of their illness and quoted other circumstantial evidence that steroids may have a role in the aetiology of central serous retinopathy. However, in view of the vast number of patients who are on steroids for one reason or another this risk must be extremely low and a proper epidemiological study is required. Our paper pointed out that central serous retinopathy is in fact rare in systemic lupus erythematosus (although large numbers of patients are treated with steroids) and, furthermore, our patients were unusual in that although they developed the typical angiographic features of central serous retinopathy they both failed to get visual improvement with resolution of the retinopathy. In our view, the association between central serous retinopathy and steroid therapy is an interesting point which remains unproved.

D J SPALTON
St Thomas's Hospital,
Lambeth Palace Road,
London SE1 7EH

Pterygium excision with conjunctival autografting

EDITOR,—The excellent article by Allan *et al*¹ on pterygium excision with conjunctival autografting drew attention to the relative slowness of the procedure. They advocated spreading the free graft out on the cornea and transferring it to the donor site without lifting it clear at any point. However, once the donor conjunctiva is completely excised, it often develops a tendency to roll up into a ball. This has to be unravelled on the cornea to ensure that the donor conjunctiva is correctly oriented before moving it to the donor site.

It is possible to simplify this technique and, in the process, to quicken the transfer and ensure the correct orientation of the graft every time. The limbal side of the conjunctival graft is freed first. Next, the nasal end of the incision is extended radially for the required distance. The area beneath the graft can now be freed by using blunt dissection, while elevating the free edge of the graft. Once the underside of the

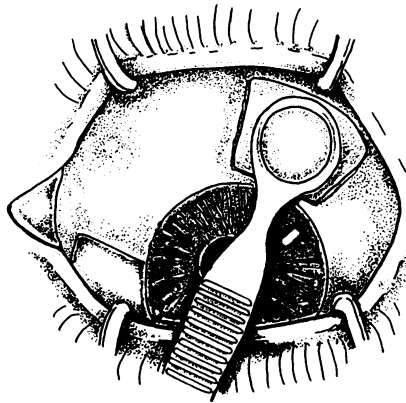


Figure 1 The conjunctival autograft is gently immobilised using a small chalazion clamp. Once dissected free, the clamp is rotated to the donor site. The autograft is automatically in the correct position for suturing at the host site.

graft is free, a small chalazion clamp is introduced, with the solid blade beneath the graft. Light pressure is then applied (with no need to tighten the screw) thus immobilising the flap. Tension is then gently exerted on the flap, and the remaining sides of the trapezoid can be quickly completed (Fig 1). The clamp is then simply swung round to the prepared recipient site. The limbal edges of the autograft are next secured with a 10/0 nylon suture (the suture is passed and cut, but not tied, so allowing the surgeon to position both limbal sutures without releasing the clamp). The clamp is then gently removed and the sutures tied. The autograft is then secured at the nasal side of the donor site. Care must be exercised throughout in exerting only light pressure on the chalazion clamp to avoid crushing the autograft. However, once the technique is familiar, the autograft transfer is much quicker.

CHRIS McLEAN
Department of Ophthalmology,
North Middlesex Hospital,
Sterling Way, London N18 1QX

- 1 Allan BDS, Short P, Crawford GJ, Barrett GD, Constable IJ. Pterygium excision with conjunctival autografting: an effective and safe technique. *Br J Ophthalmol* 1993; 77: 698-701.

Reply

EDITOR,—The variation in autograft transfer technique suggested by C McLean would certainly help to ensure the correct graft orientation; but the correct orientation can usually be maintained without difficulty by ensuring that the graft is not lifted clear of the ocular surface during excision.

Lifting the free graft clear of the ocular surface causes it to shrivel and twist dramatically. As the graft has no rigidity, the forces of surface tension acting through the fluid film coating the graft are not neutralised until the minimal volume is assumed and the graft has rolled up into a ball. So long as the graft is in contact with the eye, however, the fluid film coating the graft remains in continuity with that coating the ocular surface. Surface tension then acts to flatten the graft onto the eye. Spreading the graft out on the cornea immediately after excision, allows it to be slid into position at the excision site in the correct orientation.

Graft transfer with this technique is relatively quick. Overall, the procedure can be expedited somewhat using a continuous 10/0 nylon suture (running around three sides of the graft between the two principal points of

fixation at the limbus) to secure the graft. This suture can be removed at 3 weeks and inspires less postoperative inflammation than degradable sutures. Our clinical impression is that pterygium recurrences are more likely to occur in the context of continued postoperative inflammation.

BRUCE ALLAN
Moorfields Eye Hospital,
City Road, London EC1V 2PD

Causes of visual handicap in the Royal Blind School, Edinburgh, 1991-2

EDITOR,—We have performed a follow up study to that done in 1985 by Phillips *et al* at the Royal Blind School, Edinburgh¹ in order to detect trends in the causes of childhood blindness in the school. During the academic year 1991-2 all 93 children at the school were examined by one consultant ophthalmologist (BWF). The main cause of blindness was ocular in 46 children and neurological in 47 children. Thirty children were blind due to a recognised genetic syndrome. Five of these were autosomal dominant with a positive family history. The remaining cases were autosomal recessive or sporadic. Twenty seven had structural abnormalities of the eye or brain of unknown aetiology - 'developmental'. Sixteen children were blind due to retinopathy of prematurity (ROP) and a further three children were blind because of central nervous system complications of prematurity. Eight children had blindness associated with birth asphyxia and in eight blindness followed meningitis or encephalitis. Three cases were due to trauma.

While many of our findings are similar to those of Phillips *et al* some trends were evident. The number of congenital cataract cases has fallen from 12 to four, possibly because of improved early surgical management. The number of cases of ROP has risen from 11 to 16. This may be related to improved survival of very low birthweight infants.² It remains to be seen whether the advent of cryotherapy or laser treatment for acute ROP will reduce the incidence of blindness due to this cause.³

A recent population based survey in Ireland reported the causes of blindness in 172 children.⁴ The proportion of conditions associated with neurological handicap, such as cortical blindness and ROP, was higher in the Royal Blind School (26% v 16% and 17% v 11% respectively). Conditions causing less severe forms of visual handicap, such as some cases of optic nerve hypoplasia, were relatively under-represented in the Royal Blind School (3% v 22%). This may be because of the trend towards 'mainstream' education for less handicapped children.

BRIAN W FLECK
Department of Ophthalmology,
Royal Infirmary of Edinburgh,
Chalmers Street,
Edinburgh EH3 9HA

Y DANGATA
Department of Anatomy,
Medical School,
Teviot Place,
Edinburgh

- 1 Phillips CI, Levy AM, Newton M, Stokoe NL. Blindness in school children: importance of heredity, congenital cataract, and prematurity. *Br J Ophthalmol* 1987; 71: 578-84.
- 2 Phelps DL. Retinopathy of prematurity: an estimate of vision loss in the United States - 1979. *Pediatrics* 1981; 67: 924-5.
- 3 CRYO-ROP group. Multicentre trial of cryotherapy for retinopathy of prematurity. *Arch Ophthalmol* 1990; 108: 195-204.
- 4 Goggin M, O'Keefe M. Childhood blindness in the Republic of Ireland: a national survey. *Br J Ophthalmol* 1991; 75: 425-9.