

Exogenous *Helminthosporium* endophthalmitis

Taraprasad Das, Usha Gopinathan, Savitri Sharma

Exogenous fungal endophthalmitis caused by species of *Aspergillus*, *Fusarium*, *Candida*, and *Acremonium* is often reported.¹⁻³ Infections by other fungal species are occasionally reported. We report a case of exogenous *Helminthosporium* endophthalmitis in a pseudophakic eye that developed infection following trauma. To our knowledge this is the first report of *Helminthosporium* endophthalmitis.

Case report

A 60-year-old non-insulin dependent diabetic man gave a history of uneventful left eye extracapsular cataract extraction and intraocular lens (IOL) implantation in the middle of December 1992. Four months earlier, he had undergone IOL surgery in the right eye. He had recovered well, when he accidentally injured his left eye with a branch of a tree 6 weeks after surgery. He reported to his ophthalmologist with pain, redness, and reduction in vision. Examination revealed prolapse of the iris at 11 o'clock limbus with 1 mm hyphaema. The prolapsed iris was repositioned and the corneoscleral wound was sutured. He was put on topical ciprofloxacin, betamethasone, and cyclopentolate.

He was apparently comfortable for 3 weeks when he complained of renewed pain with gross reduction in vision and was referred to us for further management. On examination, the left eye visual acuity was perception of light with accurate projection. The applanation pressure was 7 mm Hg. Slit-lamp examination showed lid oedema, congested conjunctiva, 3×2 mm posterior corneal abscess corresponding to previous area of corneoscleral dehiscence, and exudates over the pupillary area occluding the view of the IOL, vitreous, and the retina (Fig 1). Contact ultrasonography showed medium amplitude mid and posterior vitreous opacities.

A clinical diagnosis of exogenous endophthalmitis was made. After baseline renal function tests he was put on intensive systemic and topical medications (intravenous gentamicin 80 mg every 8 hours; intravenous cefazoline 1 g every

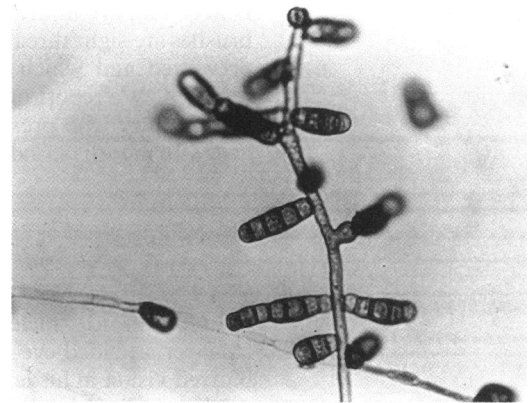


Figure 2 Lactophenol cotton blue mount of the culture showing long straight conidiophores swollen at the points of conidia production. The septae are transverse and dematiaceous conidia are oblong, characteristic of *Helminthosporium*.

6 hours; topical gentamicin 15 mg/ml, cefazoline 33 mg/ml, and betamethasone every hour; topical atropine sulphate every 6 hours). Explanation of the IOL with standard three port core vitrectomy was performed, and intraocular antibiotics without steroid (gentamicin 100 g/0.1 ml, cefazoline 2.25 mg/0.1 ml) were given.

Microscopic examination of the undiluted vitreous biopsy specimen (wet film, Gram's, Giemsa) was negative for bacteria and fungi, but showed plenty of polymorphs and red blood cells. The explanted IOL and vitreous biopsy specimen were inoculated onto a number of media: blood, chocolate, Sabouraud's and potato dextrose agar, brain heart infusion broth, and thioglycollate broth (supplemented with vitamin K and haemin). After 72 hours of incubation at 27°C significant growth of fungal colonies with a grey centre was detected on chocolate and potato dextrose agar. On further incubation of the potato dextrose agar, the fungus developed a raised velvety greyish green surface. The reverse of the medium was black in colour. No bacteria or fungus was grown in the remaining media after 14 days of incubation.

Soon after the culture report was available

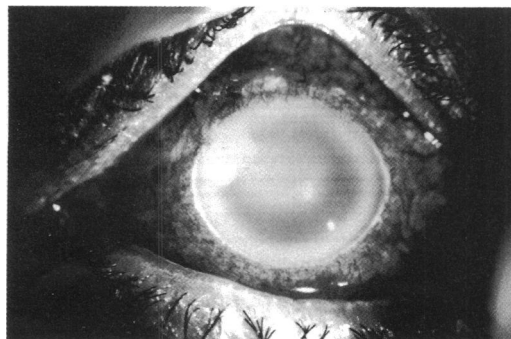


Figure 1 Preoperative photograph. Note oedematous cornea, exudates over pupillary area and posterior corneal abscess at 10 o'clock position.

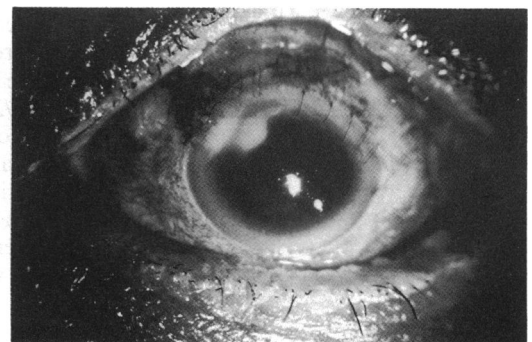


Figure 3 Postoperative photograph - 2 weeks. Note clearer cornea and shrinking posterior corneal abscess.

L V Prasad Eye Institute
and Hyderabad Eye
Research Foundation,
Hyderabad, India
T Das
U Gopinathan
S Sharma

Correspondence to:
Dr T Das, L V Prasad Eye
Institute, Road No 2, Banjara
Hills, Hyderabad - 500 034,
India.

Accepted for publication
26 January 1994

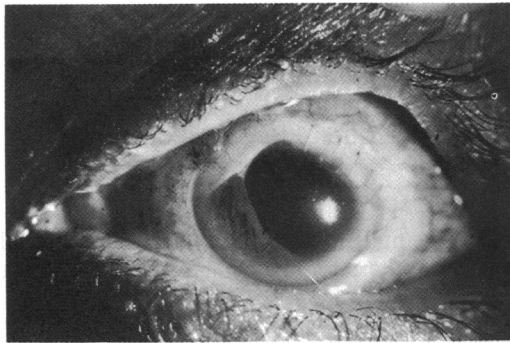


Figure 4 Postoperative photograph – 6 weeks. Note quiet conjunctiva, clear cornea, and peripheral anterior synechiae in place of earlier posterior corneal abscess.

intravitreal amphotericin B 5 g was injected into the left eye. Systemic and topical antibacterial antibiotics were injected into the left eye. Systemic and topical antibacterial antibiotics were replaced by oral ketoconazole 200 mg every 8 hours, topical 5% natamycin every hour, and topical 1% miconazole every 4 hours. Hourly betamethasone and 6 hourly atropine were continued topically. Lactophenol cotton blue mount of the slide culture preparation revealed long straight conidiophores swollen at the points of conidia production. Transverse septae and oblong dematiaceous conidia, borne laterally (pleurogenous manner) and terminally on the conidiophore (Fig 2), helped us identify the isolate as *Helminthosporium* species.

Over the next 4 days, the clinical picture remained unchanged. After 2 weeks the patient was comfortable with subsided lid oedema, quiet conjunctiva, and a shrunken posterior corneal abscess (Fig 3). There was no fundus view owing to vitreous haemorrhage. Ultrasonically, however, the vitreous was sonolucent. Three weeks following vitrectomy oral ketoconazole was discontinued in view of its potential hepatotoxicity. Topical antifungal medications (natamycin and miconazole) alone with steroid and cycloplegics were continued for 6 weeks. By then, the corneal abscess has shrunk totally and was replaced by peripheral anterior synechiae (Fig 4); the ocular medium was clear and fundus examination showed internal limiting membrane (ILM) striae over the macular area. The corrected aphakic

visual acuity was 6/60 and at 6 months' follow up, there was no recurrence of infection.

Comment

Dematiaceous fungi are ubiquitous opportunistic pathogens normally associated with soil and plants. These fungi have darkly pigmented hyphae and conidia owing to the presence of dihydroxynaphthalene melanin. *Helminthosporium* species has been confused in the past with other dematiaceous fungi such as *Drechslera*, *Bipolaris* and *Exserohilum*. Recent taxonomic studies have established useful criteria for its recognition.⁴ The only ocular infection reportedly caused by *Helminthosporium* species is corneal ulcer.⁵ A Medline search for intraocular infection by *Helminthosporium* species has failed to show any report in the past 10 years.

It appears from the case history that the patient was infected by the branch of a tree which caused wound dehiscence and iris prolapse. However, it apparently took 3 weeks to manifest clinically. The response to vitrectomy, and combined intraocular and systemic antimycotic therapy was slow but satisfactory. Probably 3 weeks of infection was partly responsible for ILM striae. An earlier intervention might have salvaged better postoperative vision.

Interestingly, the organism grew in potato dextrose agar and chocolate agar, but not in the Sabouraud's dextrose agar even after 2 weeks of incubation. This calls for inoculation in multiple media for detection of fungi as is the practice for bacteria. It is particularly necessary wherever history of injury with vegetable or plant material exists.

- 1 Pflugfelder SC, Flynn HW Jr, Zwickey TA, Forster RK, Tsiligianni A, Culbertson WW, et al. Exogenous fungal endophthalmitis. *Ophthalmology* 1988; 95: 19–30.
- 2 Driebe WT, Mandelbaum S, Forster RK, Schwartz LK, Culbertson WW. Pseudophakic endophthalmitis. Diagnosis and management. *Ophthalmology* 1986; 93: 442–8.
- 3 Affeldt JC, Flynn HW Jr, Forster RK, Mandelbaum S, Clarkson JG, Jarus GD. Microbial endophthalmitis resulting from ocular trauma. *Ophthalmology* 1987; 94: 407–13.
- 4 McGinnis MR, Rinaldi MG, Winn RE. Emerging agents of phaeohyphomycosis: pathogenic species of *Bipolaris* and *Exserohilum*. *J Clin Microbiol* 1988; 24: 250–8.
- 5 Krachmer JH, Anderson RL, Binder PS, Waring GO, Rowsey JJ, Meek ES. *Helminthosporium* corneal ulcers. *Am J Ophthalmol* 1978; 85: 666–70.