

# Carrier detection in X linked ocular albinism using linked DNA polymorphisms

S J Charles, A T Moore, Y Zhang, R McMahon, D E Barton, J R W Yates

## Abstract

Sixty two females at 50% carrier risk were assessed from 19 families affected by X linked ocular albinism (OA1). Twenty nine (47%) had definite fundus changes of the carrier state with a mud splattered fundus appearance and 23 (37%) had a normal ophthalmic examination. Ten (16%) had mild peripheral retinal pigmentary changes so that it was difficult to exclude the carrier state; six of these females were shown to be at low risk and only one at high risk of being a carrier by DNA analysis using linked DNA polymorphisms, including a highly informative dinucleotide repeat at the Kallmann locus. Mild peripheral retinal pigmentary changes are not a definite indication of carrier status and in 45 age matched female controls five (11%) had similar changes. No female with a clinically normal fundus was found to be at high risk by DNA analysis. Molecular genetic analysis improves the accuracy of carrier detection in OA1 families and should be considered if the clinical findings are equivocal.

(*Br J Ophthalmol* 1994; 78: 539-541)

X linked ocular albinism (OA1) is a cause of reduced visual acuity nystagmus in males.<sup>1</sup> Other ocular features include refractive errors, strabismus, iris translucency, fundus hypopigmentation, and foveal hypoplasia.<sup>2</sup> Carrier females have normal vision but may be identified by iris translucency and a characteristic mud splattered fundus appearance.<sup>3</sup> A recent study<sup>4</sup> found 95% of obligate heterozygotes to have a mud splattered appearance of the fundus with linear hyperpigmented streaks in the periphery and in 74% this was associated with iris translucency. Although it can be very easy to diagnose the carrier state in females at risk it may be more difficult definitely to exclude a female from being a carrier. In a group of at risk females, 28% were found to have mild retinal pigment epithelial (RPE) abnormalities, often with iris transillumination defects of uncertain significance, so that the carrier state could not definitely be excluded.<sup>5</sup> Skin histology in affected males and 86% of obligate carriers shows abnormal giant melanin granules termed macromelanosomes.<sup>4,6</sup> OA1 has been mapped to distal Xp with linkage reported to DXS143<sup>7</sup> and other markers in Xp22.3.<sup>8,9</sup> Carrier detection using linked DNA markers is now possible although, since many restriction fragment length polymorphisms (RFLPs) are diallelic, some families are found to be non-informative. A dinucleotide repeat polymorphism at the Kallmann locus (KAL) has recently been identified which is highly informative.<sup>10</sup> We have reported linkage data in OA1 families with this polymorphism<sup>11</sup> and, using the

recombinant fractions derived, it has been possible to allocate carrier risks to at risk females in our study.

Some pedigrees are more suitable for carrier risk estimation than others. In the ideal situation, DNA is available from an affected maternal grandfather (Fig 1) or obligate carrier maternal grandmother so that the marker pattern(s) linked to the disease allele (the phase) can be determined. Alternatively, brothers of an at risk female, whether normal or affected, may be used to assign phase in the mother, but it must be remembered that the marker pattern in such individuals may have resulted from recombination.

In this paper we present results of clinical examination and skin histology of females at 50% risk of inheriting the OA1 gene and compare this

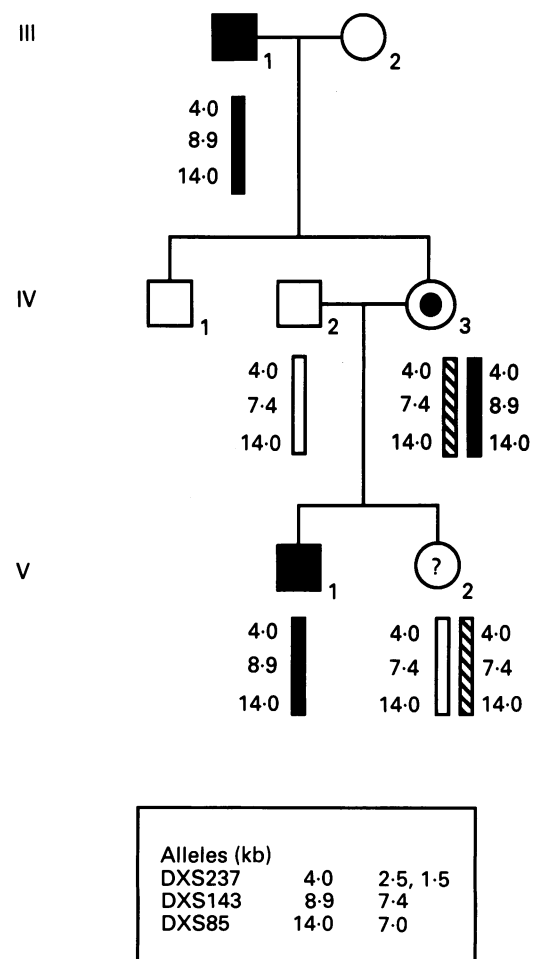


Figure 1 Part of pedigree 4216 as an example of a pedigree structure allowing carrier risk estimation. Obligate carrier IV-3 has inherited the 8.9 kb fragment for the marker DXS143 from her affected father along with the OA1 disease allele and has passed this pattern on to her affected son. Her daughter V-2 has not inherited this marker pattern and is therefore at low risk of being a carrier. The markers DXS237 and DXS85 are not informative.

The Royal Eye Hospital,  
Manchester  
S J Charles

Addenbrooke's Hospital,  
Cambridge

Department of  
Ophthalmology  
A T Moore  
D E Barton

Department of Clinical  
Genetics  
J R W Yates

Molecular Genetics  
Laboratory  
Y Zhang  
R McMahon

Cambridge University  
Department of Pathology  
J R W Yates

Correspondence to:  
Mr Stephen Charles, The  
Royal Eye Hospital, Oxford  
Road, Manchester.

Accepted for publication  
15 March 1994

with results of carrier risk estimation using RFLPs from Xp22.3 (DXS237, DXS143, DXS85) and the KAL CA repeat.

### Patients and methods

Eighteen British families and a large Newfoundland pedigree affected by OA1 have been examined as part of a linkage study previously reported.<sup>7,11,12</sup> Within each kindred a full ophthalmic examination was performed on all family members by a single observer (SJC). Iris translucency and fundus changes were graded as described previously.<sup>5</sup> Females at risk of having inherited the OA1 gene were diagnosed as carriers if the mud splattered fundus appearance with linear peripheral hyperpigmented streaks was present (grade 2 fundus). At risk females with an entirely normal ophthalmic examination (grade 0) were diagnosed as unaffected but if ophthalmoscopy revealed mild RPE changes only (grade 1) they were classified as uncertain status.

Skin biopsies, 4 mm in diameter, were taken where possible from the inner aspect of the forearm under local anaesthesia. Sections were stained with haematoxylin and eosin and by the Masson-Hamperl method and examined to assess whether macromelanosomes were present.

The DNA polymorphisms DXS237, DXS143, DXS85, and KAL CA repeat were typed as described previously.<sup>7,11</sup> Carrier risks were calculated with the computer program MLINK<sup>13</sup> using recombination fractions derived from our previous studies (Table 1). OA1 gene frequency was estimated at 0.0001. OA1 shows complete penetrance in affected males. Definite fundus changes are present in 95% of obligate carrier females.

### Results

Sixty two at risk females were daughters of obligate carriers and therefore had a prior risk of 50% of being a carrier; 29 of this group (46.8%) had the grade 2 fundus appearance on ophthalmoscopy, 10 (16.1%) had the grade 1 fundus appearance, and 23 (37.1%) had a normal fundus (grade 0). Slit-lamp examination and ophthalmoscopy was possible in 28 patients in this group who had definite signs of the carrier state (grade 2 fundus): 25 had grade 3 iris translucency (89.3%), one had grade 2 iris translucency, and two had no iris translucency. In 10 cases mild peripheral RPE abnormalities were noted, associated in two cases with mild (grade 1) and in one case with marked (grade 3) iris translucency. Forty five normal age matched female controls have been examined in a routine ophthalmic clinic: 40 had entirely normal fundi but five had

Table 1 Two point linkage data between OA1 and DXS237, DXS143, DXS85, and Kallmann locus (KAL) CA repeat from previous studies<sup>11</sup>

Locus	Lod score ( $Z_{max}$ )	Recombination fraction ( $\theta_{max}$ )	Confidence interval for $\theta$
DXS237	15.20	0.08	0.03-0.15
KAL	30.14	0.06	0.03-0.10
DXS143	21.96	0.01	0.0005-0.05
DXS85	17.60	0.07	0.02-0.13

Table 2 Observed and expected number of individuals with different fundus changes in the group of 62 females at 50% prior risk of being a carrier

62 at risk females				
Expected division	31 carriers		31 normal females	
Expected fundus changes by status	Grade 2 (94.9%) =29.4	Grade 1 (5.1%) =1.6	Grade 1 (11.1%) =3.4	Grade 0 (88.9%) =27.6
Expected fundus changes overall	29.4 grade 2	5.0 grade 1	27.6 grade 0	
Observed numbers	29 grade 2	10 grade 1	23 grade 0	

peripheral hypopigmentation and/or granular peripheral fundus pigmentation which would be classified as grade 1 fundi.

Table 2 shows the expected and observed number of females with the different fundus changes. Expected numbers are calculated from the data derived from examination of the obligate carriers and normal female controls.<sup>4</sup> The expected and observed number of females with grade 2 fundus changes correlate very well, but more at risk females were thought to have a grade 1 fundus, and were therefore classified as uncertain status, than would be expected. However, there was no statistically significant difference between the expected and observed values ( $\chi^2=2.09$ , 2 df).

DNA analysis and carrier risk estimation were possible in nine of the 10 females whose status was uncertain after clinical examination (Table 3). The RFLPs DXS237, DXS143, and DXS85 were informative in four females who were all shown to be at low risk. Using the KAL CA repeat two more were found to be at low risk and another at high risk of being a carrier. One female (4896; VI-26) of uncertain status after ophthalmoscopy had blue irides and marked iris translucency (grade 3) such that the edge of the lens could be visualised: she was found to be at low risk of being a carrier by DNA analysis (<1%). No female with a clinically normal fundus was found to be at high risk by DNA analysis.

Skin biopsies were performed in four uncertain status females but none showed macromelanosomes.

### Discussion

The majority of carriers of the OA1 gene may be detected on the basis of ophthalmic examination,

Table 3 Results of carrier risk estimation by molecular genetic analysis in females of uncertain status following ophthalmic examination

Family No	Individual	Macromelanosomes on skin biopsy	Calculated carrier risk using	
			RFLPs alone	RFLPs + KAL CA repeat
3126	V-3	absent	NI	4%
3239	IV-6	absent	1%	1%
3928	IV-2	absent	8%	6%
4216	V-2	absent	1%	1%
4896	VI-22	NP	NI	94%
4896	VI-19	NP	NI	NI
4896	VI-20	NP	NI	NI
4896	VI-26	NP	<1%	<1%
4896	VI-43	NP	NI	19%

NP=not performed; NI=non-informative. RFLPs=DXS237, DXS143, DXS85.

including funduscopy through dilated pupils, to detect the characteristic mud splattered fundus appearance. However, some at risk females may have only mild RPE abnormalities, not typical of the carrier state but also not entirely normal, and it is difficult to give decisive genetic counselling to these patients. It is just as important to be able definitely to exclude the carrier state, and therefore the risk of having an affected child, as it is to confirm the carrier state in the at risk female. Assessment of the fundi of normal female controls using the same fundus grading system showed that mild RPE abnormalities may be seen in a small proportion of the normal population, suggesting that these abnormalities can be part of the spectrum of the normal phenotype, rather than a specific manifestation of the carrier state. Although marked iris translucency often occurs as part of the carrier phenotype, it may also occur in normal individuals<sup>14</sup> and particularly in those with blue irides. Therefore in isolation iris translucency cannot be used to assign carrier status.

In this group of females known to be at 50% prior risk of having inherited the abnormal gene, the percentage of patients with typical grade 2 fundus changes (47%) was as expected from the findings in obligate carriers. Ten patients (16%) had grade 1 fundus changes and were therefore classified as of uncertain status.

DNA analysis was possible in nine of these females of uncertain status and carrier risk could be estimated in seven. The KAL CA repeat was found to be informative in seven cases and only one was found to be at high carrier risk. This confirms that mild variations in fundus pigmentation are rarely a manifestation of the carrier state. Skin biopsy demonstrating macromelanosomes may be a useful confirmatory test of the carrier state in some cases. It was negative in four of the patients shown to be at low risk by DNA analysis.

Ophthalmic examination of females at risk of being carriers of OA1 may enable definitive

genetic counselling in those cases with definite carrier signs. The exclusion of carrier risk by clinical means alone is more difficult. Molecular genetic analysis improves the accuracy of carrier detection and should be considered if the clinical findings are equivocal. With the availability of highly informative dinucleotide repeats such as that at the Kallmann locus used in this study it should be possible to determine the carrier status of most at risk females. Isolation of the OA1 gene itself and the characterisation of its mutations may in the future make direct molecular genetic diagnosis possible.

SJC was in receipt of a Wellcome Trust vision research fellowship during this study. YZ was funded by a scholarship from Kunming Medical College, Kunming, China.

- 1 Kinnear PE, Jay B, Witcop CJ Jr. Albinism. *Surv Ophthalmol* 1985; 30: 75-101.
- 2 Charles SJ, Green JS, Grant JW, Yates JRW, Moore AT. Clinical features of affected males with X linked ocular albinism. *Br J Ophthalmol* 1993; 77: 222-7.
- 3 Falls HF. Sex-linked ocular albinism displaying typical fundus changes in the female heterozygote. *Am J Ophthalmol* 1951; 34: 41-50.
- 4 Charles SJ. Clinical and molecular genetic features of X-linked ocular albinism. MD thesis, University of London, 1992.
- 5 Charles SJ, Moore AT, Grant JW, Yates JRW. Genetic counselling in X-linked ocular albinism: clinical features of the carrier state. *Eye* 1992; 6: 75-9.
- 6 O'Donnell FE Jr, Hambrick GW, Green WR, Iliff WJ, Stone DL. X-linked ocular albinism: an oculocutaneous macromelanosomal disorder. *Arch Ophthalmol* 1976; 94: 1883-92.
- 7 Charles SJ, Green JS, Moore AT, Barton DE, Yates JRW. Genetic mapping of X-linked ocular albinism: linkage analysis in large Newfoundland kindred. *Genomics* 1993; 16: 259-61.
- 8 Kidd JR, Castiglione CM, Davies KE, Pakstis AJ, Gusella J, Sparkes RS, et al. Mapping the locus for X-linked ocular albinism. *Am J Hum Genet* 1985; 37 (suppl): A161.
- 9 Schnur RE, Nussbaum RL, Anson-Cartwright L, McDowell C, Worton RG, Musarella MA. Linkage analysis in X-linked ocular albinism. *Genomics* 1991; 9: 605-13.
- 10 Bouloux PM, Hardelin JP, Munroe P, Kirk JM, Legouis R, Levilliers J, et al. A dinucleotide repeat polymorphism at the Kallmann locus (Xp22.3). *Nucleic Acids Res* 1991; 19: 5453.
- 11 Zhang Y, McMahon R, Charles SJ, Moore AT, Barton DE, Yates JRW. Genetic mapping of the Kallmann syndrome and X-linked ocular albinism gene loci. *J Med Genet* 1993; 30: 923-5.
- 12 Charles SJ, Moore AT, Yates JRW. Genetic mapping of X-linked ocular albinism: linkage analysis in British families. *J Med Genet* 1992; 29: 552-4.
- 13 Lathrop GM, Lalouel JM, Julier C, Ott J. Multilocus linkage analysis in humans: detection of linkage and estimation of recombination. *Am J Hum Genet* 1985; 37: 482-98.
- 14 Jay B, Carruthers J, Treplin MCW, Winder AF. Human albinism. *Birth Defects* 1976; 12: 415-26.