

Treatment of cytomegalovirus retinitis with intravitreal injection of liposome encapsulated ganciclovir in a patient with AIDS

Shiva K Akula, Patrick E Ma, Gholam A Peyman, Mohamad H Rahimy, Newton E Hyslop Jr, Aileen Janney, Paul Ashton

Abstract

To study its safety and efficacy in treating cytomegalovirus (CMV) retinitis, an AIDS patient received an intravitreal injection of liposome encapsulated ganciclovir in the right eye. The left eye served as a control, receiving intravitreal free ganciclovir. The right eye showed no retinal haemorrhages or detachment; however, vision declined initially, stabilising later. Weekly examination showed neither progression of the CMV retinitis nor new lesions in the right eye. The left eye showed reactivation of old CMV retinitis. Liposome encapsulated ganciclovir reduced the number of intravitreal injections, stabilising CMV retinitis, and warrants further study.

(*Br J Ophthalmol* 1994; 78: 677-680)

Cytomegalovirus (CMV) retinitis is the most common cause of visual loss in AIDS. Approximately 30% of patients with AIDS are expected to develop CMV retinitis at some time during their illness.¹ Ganciclovir (Cytovene, Syntex Laboratories Inc, Palo Alto, CA, USA) has been available since 1989 in intravenous form. Because intravenous ganciclovir causes myelosuppression and thrombocytopenia, thus predisposing to line cannula sepsis and preventing concomitant use of zidovudine, intravitreal ganciclovir was given. The half life of intravitreal ganciclovir has been estimated at 13.3 hours²; therefore, induction therapy with intravitreal ganciclovir generally consists of two to three

injections per week for 2 to 3 weeks. Maintenance therapy consists of lifetime weekly injections. Repeated intravitreal injections increase the risk of endophthalmitis, damage to lens, and retinal detachment, and may be poorly tolerated by end stage patients. To prevent these problems, ganciclovir was encapsulated in liposomes to increase the intravitreal retention of the drug, thereby decreasing the frequency of injections.

Case report

A 32-year-old white man, HIV positive since 1987, had a clinical diagnosis of CMV retinitis in August 1990 at ophthalmic evaluation for blurred vision (Fig 1). Initial visual acuity was 20/20 -2 in the right eye and 20/25 +2 in the left eye. Zone III lesions and zone I/II lesions were noted in the right and left eyes, respectively. Intravenous ganciclovir therapy at 300 mg twice daily was initiated but later complicated by neutropenia and *Staphylococcus aureus* endocarditis. After adequate treatment for both these complications, intravenous ganciclovir was restarted. Subsequent interruption of intravenous ganciclovir for recurrent neutropenia and cannula sepsis prompted removal of the cannula and the use of intravitreal ganciclovir. On 18 September 1991, twice weekly 200 µg doses of intravitreal ganciclovir were started in the right eye. Vision in the right eye was 20/25 +3 and in the left eye was counting fingers temporal vision. On 27 September 1991, intravitreal ganciclovir was increased to 400 µg and maintained at 400 µg weekly in the right eye. On 12 October 1991, vision in the right eye decreased to 20/400 one day after an intravitreal ganciclovir injection. The patient noticed pain, photophobia in the right eye, and endophthalmitis was diagnosed. He was admitted for vitreal needle biopsy and intravitreal ganciclovir injection was given along with intravitreal gentamicin and clindamycin. Subsequently, the vitreous cultures grew *Staphylococcus epidermidis* and intravitreal vancomycin and clindamycin were reinjected. The intravitreal injections were stopped and intravenous ganciclovir started with a visual acuity improvement to 20/400 with moderate vitreous haze.

In light of the recurrent neutropenia, several episodes of cannula sepsis, and peripheral intravenous access intolerance the patient was given an intravitreal injection of liposome encapsulated ganciclovir in the right eye on 10 February 1992 (Figs 2 and 3). Liposome encapsulation was used for slow release in the vitreous. Before the

Department of Medicine,
Tulane University
Medical Center, New
Orleans, USA

S K Akula
N E Hyslop

LSU Eye Center, New
Orleans, USA

P E Ma
G A Peyman
M H Rahimy

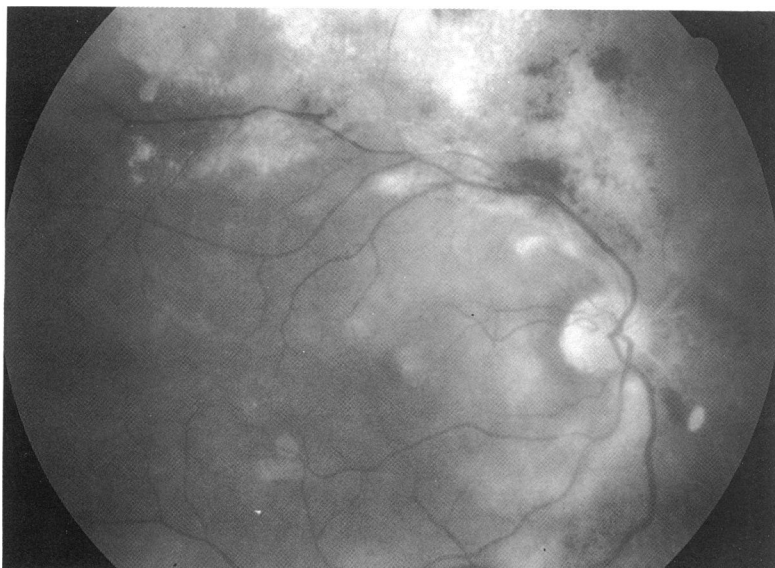
Department of
Microbiology, Medical
Center of Louisiana at
New Orleans, USA
A Janney

Department of
Ophthalmology,
University of Kentucky
at Lexington, USA
P Ashton

Correspondence to:
Dr Gholam A Peyman, LSU
Eye Center, 2020 Gravier
Street, Suite B, New Orleans,
LA 70112-2234, USA.

Accepted for publication
11 April 1994

Figure 1 Right eye on initial visit before intravitreal ganciclovir.



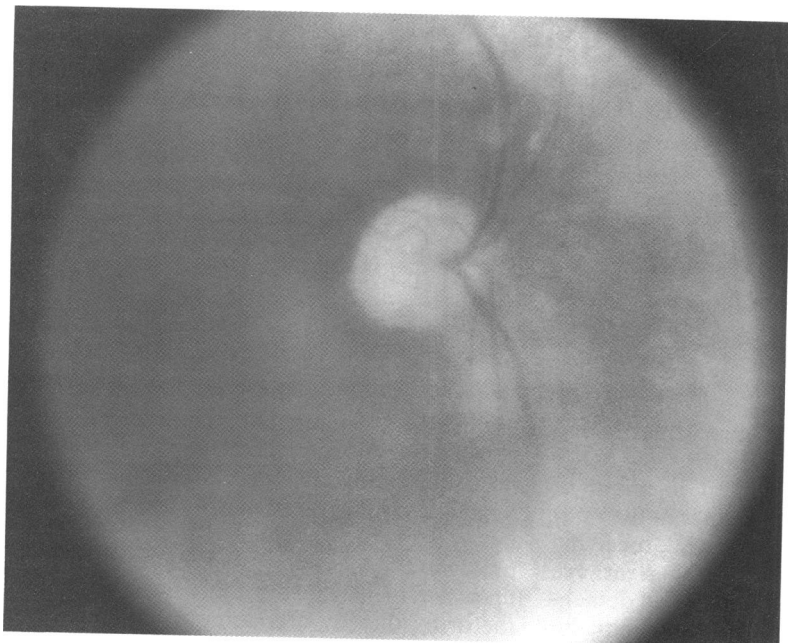


Figure 2 Right eye 1 hour before the intravitreal injection of liposome encapsulated ganciclovir.

liposome encapsulated ganciclovir injection, the patient's informed consent was obtained, along with the approval of human subjects committee at Tulane University School of Medicine. The left eye was given regular intravitreal ganciclovir twice weekly. Three days later, visual acuity was reduced to hand movements and 2+ vitreous haze was noted in the right eye. Vitreal taps of the right eye were done 7, 14, and 24 days after the single intravitreal liposome encapsulated ganciclovir injection. Follow up of the patient was interrupted because of multiple opportunistic infections, including *Mycobacterium avium* intracellular complex and disseminated Kaposi's sarcoma, leading to worsening physical condition. The family and the patient decided to discontinue further intravitreal therapy, and vision deteriorated to bilateral blindness. The patient died on 21 June 1992.

Materials and methods

A reverse phase evaporation method of liposome

preparation was used for encapsulation of ganciclovir. The lipid composition for this formulation was a 4:1 molar ratio of phosphatidylcholine and phosphatidylglycerol from Avanti Polar Lipids, Inc (Alabaster, AL, USA). The lipids were dissolved in an organic solvent (ether and chloroform, 2:4, v:v). The organic phase was then combined with an aqueous phase containing the drug ganciclovir to be encapsulated. The organic phase was three times the aqueous phase initially. The two phase mixture was then sonicated for 5 minutes to form a milky, homogeneous emulsion. This emulsion contained reverse micelles and was evaporated to remove the organic solvent under vacuum by a rotary evaporator. This method allows for preparation of large unilamellar vesicles with relatively high encapsulation efficiency. After completion of liposome formation, the encapsulated drug was separated from unencapsulated material by subjecting the preparation to dialysis for 24 hours.

STERILISATION

All equipment and glassware were sterilised before liposome drug preparation. Furthermore, after liposome formulation, the liposome ganciclovir preparation was filtered using a 0.2 µm filter, and an aliquot was placed on blood agar and brain heart infusion medium to test for possible contamination. No bacteria or fungi were detected by culture.

SAMPLE COLLECTION

The right eye was irrigated with sterile saline solution. Retrobulbar anaesthesia was used. A cotton pledget was applied to the cornea scleral surface with topical anaesthesia. Vitreal samples were collected with a No 30 1/2 inch tuberculin syringe. A 200 µl sample of vitreous was removed at 0 (baseline), 7, 14, and 24 days after a single intravitreal injection of 0.25 ml (1 mg) of the liposome encapsulated ganciclovir. The samples were immediately stored frozen at -20°C until ganciclovir analysis.

GANCICLOVIR ASSAY

The vitreous samples were analysed for ganciclovir by the high performance liquid chromatography (HPLC) method using a 25 cm × 5 µm C18 reverse phase column. The mobile phase was 2% acetonitrile/ionised water (v/v) and 0.02% acetic acid; pH 4.0 with a flow rate of 1 ml/min. The detection wavelength was 254 nm. Under these conditions, the retention time of ganciclovir was 7.8 minutes and the detection limit 0.02 µg/l.

Results

Ophthalmoscopic examination of the right eye showed no progression of old CMV retinitis and no new lesions were noted. There was no evidence of retinal haemorrhages or detachment, but vision declined initially owing to vitreous clouding. Because the visual acuity is not always easy to determine in patients with poor overall condition,³ it was not used as a criterion for

Figure 3 Right eye 1 day after intravitreal injection of liposome encapsulated ganciclovir.

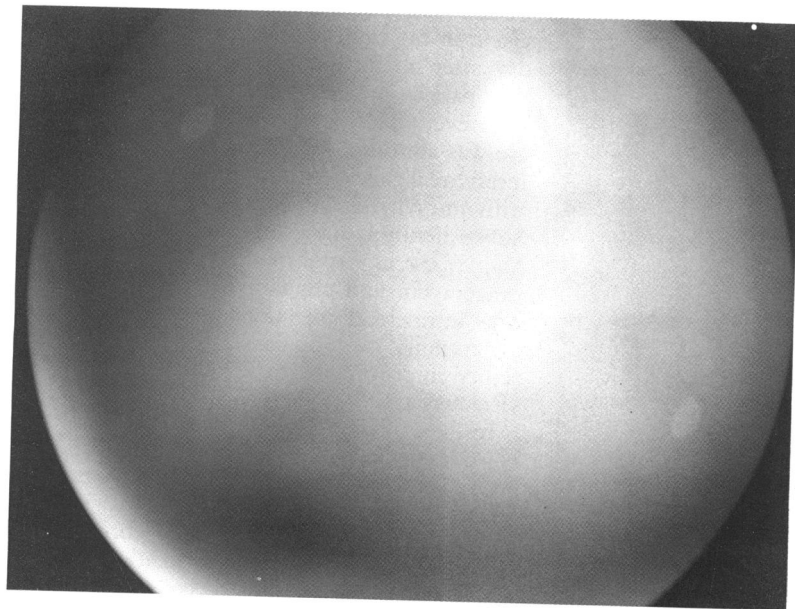


Table 1 Clearance of an intravitreal injection of liposome encapsulated ganciclovir in the right eye

Days after injection	Concentration ($\mu\text{g/ml}$)
0	2.5
7	11.6
14	4.2
24	6.6

treatment evaluation.⁴ Furthermore, visual acuity is dependent upon the location of the lesions but not on their activity. The intravitreally injected liposome encapsulated ganciclovir appeared as a whitish suspension located in the inferior part of the vitreous. The clouding disappeared gradually over 2 weeks. The left eye showed reactivation of old CMV in the first week, requiring twice weekly intravitreal injections of ganciclovir.

PHARMACOKINETICS OF LIPOSOME ENCAPSULATED GANCICLOVIR

Vitreous ganciclovir concentration was 2.5 $\mu\text{g/ml}$ before the injection of liposome ganciclovir. The liposome encapsulated ganciclovir preparation achieved a vitreous drug level of 11.6 $\mu\text{g/ml}$ at 7 days after treatment. Ganciclovir levels remained at 4.2 and 6.6 $\mu\text{g/ml}$ 14 and 24 days after treatment, respectively (Table 1).

Discussion

CMV retinitis is the most frequent ocular opportunistic infection of the retina in AIDS, with prevalence ranging from 15% to 40%.¹⁵ Because CMV is a multisystem disease, the systemic route of treatment is often used. Intravenous ganciclovir causes neutropenia in 16–75% of treated patients,^{16–8} precluding the concomitant use of zidovudine, the drug known to prolong survival in AIDS. Systemic foscarnet^{9,10} is nephrotoxic in 30% of patients and can cause metabolic abnormalities of calcium and magnesium. Seizures have also been reported. Both ganciclovir and foscarnet require a long term indwelling central venous cannula for administration. Although substantially lower health costs are associated with daily home infusion through a central venous cannula, the patients have increased risk of cannula related infection, sepsis, or thrombosis.^{6,10}

The pharmacokinetics of intravenous ganciclovir revealed comparable levels in subretinal fluid and in blood (7.16 and 8.16 mmol/l respectively). The subretinal fluid levels decreased to 0.8 mmol/l 21 hours after intravenous administration of the ganciclovir.¹¹

The advantages of intravenous ganciclovir therapy include the ability to treat bilateral disease and possible prevention or control of CMV infections at other sites. Because the role of intravenous ganciclovir in survival is unclear and systemic toxicities are associated with intravenous ganciclovir and foscarnet, the intravitreal route of administration is being studied.^{3,4,12–15} In rabbit eyes,¹⁶ 200–400 μg doses of ganciclovir showed no evidence of adverse electrophysiological or histopathological effect. However, high doses (155 mmol/l) in vitrectomy infusion fluids were associated with significant retinal cellular disorganisation and dissipation. Because the half life of intravitreal ganciclovir is 13.3 hours,² frequent administration is required, leading to patient intolerance. Repeated intravitreal ganciclovir administration is associated with increased risk of endophthalmitis, retinal detachment, vitreous haemorrhage, and increased intraocular pressure.^{2–4,8,17} The incidence of bac-

terial endophthalmitis varied from zero in 110 injections⁴ to 0.4% in a series of 249.¹⁷ Other reported complications include conjunctival scarring and scleral induration.

Because there is no animal model for CMV retinitis, *in vitro* studies are heavily relied upon. Fifty per cent reduction of viral plaque formation (minimal inhibitory concentration [MIC_{50}]) and a reduction in DNA synthesis occur at a ganciclovir concentration of 0.5 to 3.0 mmol/l. Another reason for studying intravitreal ganciclovir is its use in special situations such as juxtafoveal CMV retinitis lesions. The fovea is a relatively avascular area of the retina, although it is nourished from the choroid.

Although 400 μg in 0.1 ml was used by Cochereau-Marrin and associates⁴ without serious toxicity, there is inadequate information to conclude that higher doses show better efficacy. Doses up to 600 μg have been used clinically (personal discussion with Dr P Ma) with no obvious toxicity in controlling foveal lesions. The continued use of 400 μg for initial therapy was preferred, as it provides intravitreal levels of drug higher than the MIC for most CMV isolates. It is further believed to be effective by many investigators and will decrease risk of drug toxicity.

Liposomes are membrane-like vesicles used to encapsulate drugs. They are made from phospholipids such as lecithin, phosphatidylglycerol, and phosphatidylserine. Liposomal encapsulation before intravitreal injection has been used to enhance a drug's therapeutic index primarily by confining the drug's action to the local site of injection, thereby increasing the amount of drug delivered to the target tissues; serving as a sustained release depot; extending the drug's half life; and decreasing or minimising intraocular side effects through a controlled release effect.

Experimentally induced streptococcal, staphylococcal, and candida endophthalmitis were treated with liposome encapsulated penicillin,¹⁸ clindamycin,¹⁹ and amphotericin,²⁰ respectively, with variable success.

Intraocular drug delivery systems²¹ have recently been studied. If reasonably longer intravitreal retention of ganciclovir is achieved by intravitreal injection, complicated surgical implantation of a device can be avoided. Intravitreal injection of liposomal ganciclovir allowed the retention of ganciclovir as long as 24 days after injection in a concentration of 6.6 $\mu\text{g/ml}$, which is higher than the MIC_{50} concentration. The lower concentration of 4.2 $\mu\text{g/ml}$ followed by 6.6 $\mu\text{g/ml}$ may be due to the dilutional effect of intravitreal sampling.

Although subjective deterioration of visual acuity may be caused by vitreal haze, objective retinal examinations revealed no progression or recurrence of retinitis, suggesting clinical benefit of the sustained release of ganciclovir in the vitreous. The location and size of lesions have a greater short term effect on visual acuity than the degree of control by antiviral medications. The effect of liposomes on the retina is unclear at this time. The lack of acute retinal toxicity and the retention of intravitreal ganciclovir 24 days after the injection warrant further studies. Higher fractions of liposome encapsulated ganciclovir

may remain longer than 25 days. Although prolongation of intravitreal retention of ganciclovir is important, it needs to be correlated with improvement in visual acuity and resolution of the CMV retinitis lesions (Table 1).

Supported in part by US Public Health Service grants EY07541 and EY02377 from the National Eye Institute, National Institutes of Health, Bethesda, MD and GCRC grant 5M01RR050 96-05 from the NIH.

The material in the paper was presented as a poster at the VIII International Conference on AIDS/III STD World Congress in Amsterdam, The Netherlands, 19-24 July 1992.

- 1 Jabs DA, Enger C, Bartlett JG. Cytomegalovirus retinitis and acquired immunodeficiency syndrome. *Arch Ophthalmol* 1989; **107**: 75-80.
- 2 Henry K, Cantrill H, Fletcher C, Chinnock BJ, Balfour HH Jr. Use of intravitreal ganciclovir (dihydroxy propoxymethyl guanine) for cytomegalovirus retinitis in a patient with AIDS. *Am J Ophthalmol* 1987; **103**: 17-23.
- 3 Ussery FM III, Gibson SR, Conklin RH, Piot DF, Stool EW, Conklin AJ. Intravitreal ganciclovir in the treatment of AIDS-associated cytomegalovirus retinitis. *Ophthalmology* 1988; **95**: 640-8.
- 4 Cochereau-Massin I, Lehoang P, Lautier-Frau M, Zazoun L, Marcel P, Robinet M, et al. Efficacy and tolerance of intravitreal ganciclovir in cytomegalovirus retinitis in acquired immunodeficiency syndrome. *Ophthalmology* 1991; **98**: 1348-55.
- 5 Freeman WR, Lerner CW, Mines JA, Lash RS, Nadel AJ, Starr MB, et al. A prospective study of the ophthalmologic findings in the acquired immune deficiency syndrome. *Am J Ophthalmol* 1984; **97**: 133-42.
- 6 Aceves-Casillas P, Mullen MP, Taranta A. Infections associated with Hickman catheters in patients with acquired immunodeficiency syndrome. *Am J Med* 1989; **86**: 780-6.
- 7 Henderly DE, Freeman WR, Causey DM, Rao NA. Cytomegalovirus retinitis and response to therapy with ganciclovir. *Ophthalmology* 1987; **94**: 425-34.
- 8 Heinemann MH. Long-term intravitreal ganciclovir therapy for cytomegalovirus retinopathy. *Arch Ophthalmol* 1989; **107**: 1767-72.
- 9 Jacobson MA, O'Donnell JJ, Mills J. Foscarnet treatment of cytomegalovirus retinitis in patients with the acquired immunodeficiency syndrome. *Antimicrob Agents Chemother* 1989; **33**: 736-41.
- 10 Walmsley SL, Chew E, Read SE, Vellend H, Salit I, Rachlis A, et al. Treatment of cytomegalovirus retinitis with trisodium phosphonoformate hexahydrate (foscarnet). *J Infect Dis* 1988; **157**: 569-72.
- 11 Jabs DA, Newman C, de Bustros S, Polk BF. Treatment of cytomegalovirus retinitis with ganciclovir. *Ophthalmology* 1987; **94**: 824-30.
- 12 Smith TJ, Pearson PA, Blandford DL, Brown JD, Goins KA, Hollins JL, et al. Intravitreal sustained-release ganciclovir. *Arch Ophthalmol* 1992; **110**: 255-8.
- 13 Daikos GL, Pulido J, Kathpalia SB, Jackson GG. Intravenous and intraocular ganciclovir for CMV retinitis in patients with AIDS or chemotherapeutic immunosuppression. *Br J Ophthalmol* 1988; **72**: 521-4.
- 14 Buchi ER, Fitting PL, Michel AE. Long term intravitreal ganciclovir for cytomegalovirus retinitis in a patient with AIDS. *Arch Ophthalmol* 1988; **106**: 1349-50.
- 15 Harris ML, Mahalane MBR. Intravitreal ganciclovir in CMV retinitis: case report. *Br J Ophthalmol* 1989; **73**: 382-4.
- 16 Peyman GA, Khoobehi B, Tawakol M, Schulman JA, Mortada HA, Alkan H, et al. Intravitreal injection of liposome-encapsulated ganciclovir in a rabbit model. *Retina* 1987; **7**: 227-9.
- 17 Cantrill HL, Henry K, Melroe NH, Knobloch WH, Ramsay RC, Balfour HH Jr. Treatment of cytomegalovirus retinitis with intravitreal ganciclovir: long term results. *Ophthalmology* 1989; **96**: 367-74.
- 18 Alghadyan AA, Peyman GA, Khoobehi B. Intravitreal injection of liposome-encapsulated penicillin for the treatment of bacterial endophthalmitis. *Afro-Asian J Ophthalmol* 1988; **7**: 43-5.
- 19 Rao VS, Peyman GA, Khoobehi B, Vangipuram S. Evaluation of liposome-encapsulated clindamycin *Staphylococcus aureus* endophthalmitis. *Int Ophthalmol* 1989; **13**: 181-5.
- 20 Liu KR, Peyman GA, Khoobehi B. Efficacy of liposome-bound amphotericin B for the treatment of experimental fungal endophthalmitis in rabbits. *Invest Ophthalmol Vis Sci* 1989; **30**: 1527-34.
- 21 Sanborn GE, Anand R, Torti RE, Nightingale SD, Cal SX, Yates B, et al. Sustained-release ganciclovir therapy for treatment of cytomegalovirus retinitis: use of an intravitreal device. *Arch Ophthalmol* 1992; **110**: 188-95.