

# X linked ocular albinism in Japanese patients

Takashi Shiono, Masahiro Tsunoda, Yasuschi Chida, Mitsuru Nakazawa, Makoto Tamai

## Abstract

**Thirteen affected Japanese male patients and 13 female carriers with X linked ocular albinism from seven families were examined to assess their clinical findings and to compare them with those of white and black patients. Affected Japanese patients had poor visual acuity, horizontal nystagmus, macular hypoplasia, and loss of stereopsis. Some affected patients had exotropia. Most affected patients had non-albinotic fundus with moderate pigmentation. The amount of pigment in the fundus varied among affected patients and appeared to be between that of the white and black patients. All affected patients had brown irides that show no translucency. Interestingly, two affected patients had megalocornea and a third affected patient had posterior embryotoxon. All female carriers exhibited good visual acuity, normal eye position, stereopsis, brown irides without translucency, and the typical mosaic pattern in the fundus. The pigmented iris and fundus made the correct diagnosis of these affected patients difficult. Nine affected patients (70%) had been diagnosed initially as having congenital nystagmus, with or without macular hypoplasia, until they were reviewed for this study.**

(*Br J Ophthalmol* 1995; 79: 139-143)

X linked ocular albinism (XLOA), which was first described by Nettleship<sup>1</sup> in 1955, is

characterised by nystagmus, decreased visual acuity, strabismus, fundus hypopigmentation with macular hypoplasia, and iris hypopigmentation with translucency. Posterior embryotoxon, Axenfeld anomaly,<sup>2,3</sup> megalocornea,<sup>4</sup> and optic disc hypoplasia<sup>5</sup> also have been reported in a few affected patients. The fundus of the female carrier<sup>6</sup> shows a mosaic pattern of pigmentation and depigmentation, which helps to make the diagnosis of XLOA. Skin and hair are clinically normal. However, histological examination<sup>7-9</sup> of the skin from both affected patients and female carriers has disclosed abnormal macromelanosomes, suggesting that the disorder is systemic and not confined to the eye. Recent studies of a large number of white families with XLOA have confirmed these clinical and histological findings.<sup>10</sup>

Fundus and iris pigmentation in black patients with XLOA<sup>11</sup> reportedly differed from that of white patients. Affected black patients had brown irides without transillumination, and their fundi showed moderate pigmentation, making the correct diagnosis of XLOA difficult. It has been reported that some affected Japanese patients with XLOA<sup>3,4,12,13</sup> have brown irides and non-albinotic fundi, showing a degree of pigmentation between that of the white and black patients. To date, no studies have reported on large numbers of Japanese families with XLOA. In this study, we examined 13 affected patients and 13 female carriers from seven families to assess the phenotypic variation in Japanese patients and to show how it differs from that of white and black patients with XLOA.

Table 1 Clinical characteristics of Japanese patients with X linked ocular albinism

Case/age	Visual acuity	Refractive errors	Position	Stereopsis	Iris colour	Albinotic fundus	Megalocornea
1 A IV-11/12 years	RE; 0.4 LE; 0.4	+2.5 D=cyl+3.5 D A90° +2.5 D=cyl+3.0 D A95°	Orthophoria	None	Brown	No	No
2 A III-1/50 years	RE; 0.2 LE; 0.2	-4.0 D -3.25 D	Exotropia	None	Brown	Yes	No
3 A III-4/39 years	RE; 0.2 LE; 0.2	+1.0 D=cyl+2.75 D A90° +0.75 D=cyl+2.25 D A90°	Exotropia	ND	Brown	No	No
4 A IV-14/28 years	RE; 0.4 LE; 0.4	+1.5 D +2.0 D	Orthophoria	ND	Brown	No	No
5 B V-1/2 years	RE; ND LE; ND	ND ND	Orthophoria	ND	Brown	No	No
6 B IV-5/16 years	RE; 0.3 LE; 0.3	cyl-3.0 A180° cyl-1.75 D A180°	Exotropia	None	Brown	No	No
7 B III-5/44 years	RE; 0.05 LE; 0.07	+0.5 D=cyl+2.25 D A90° +0.5 D=cyl+2.25 D A90°	Orthophoria	None	Brown	No	No
8 C III-1/3 months	RE; ND LE; ND	ND ND	Orthophoria	ND	Brown	No	No
9 C II-3/24 years	RE; 0.1 LE; 0.1	0 0	Exotropia	None	Brown	No	No
10 D III-1/5 years	RE; 0.3 LE; 0.4	+1.25 D=cyl-3.0 D A180° +0.5 D=cyl-1.5 D A180°	Orthophoria	ND	Brown	No	Yes
11 E IV-1/10 years	RE; 0.3 LE; 0.3	+1.25 D=cyl-2.0 D A170° +2.25 D=cyl-2.5 D A20°	Orthophoria	None	Brown	Yes	Yes
12 F IV-1/10 years	RE; 0.4 LE; 0.4	+1.0 D=cyl-1.25 D A180° +1.0 D=cyl-0.25 D A180°	Orthophoria	None	Brown	No	No
13 G III-1/12 years	RE; 0.3 LE; 0.3	+2.0 D=cyl-5.0 D A180° +3.0 D=cyl-3.5 D A180°	Exotropia	None	Brown	No	No

ND=not done.

Department of Ophthalmology, Tohoku University School of Medicine, 1-1 Seiryō-machi, Aoba-ku, Sendai 980, Japan  
T Shiono  
M Tsunoda  
Y Chida  
M Nakazawa  
M Tamai

Correspondence to: T Shiono, MD, Department of Ophthalmology, Tohoku University School of Medicine, 1-1 Seiryō-machi, Aoba-ku, Sendai 980, Japan.

Accepted for publication 27 September 1994

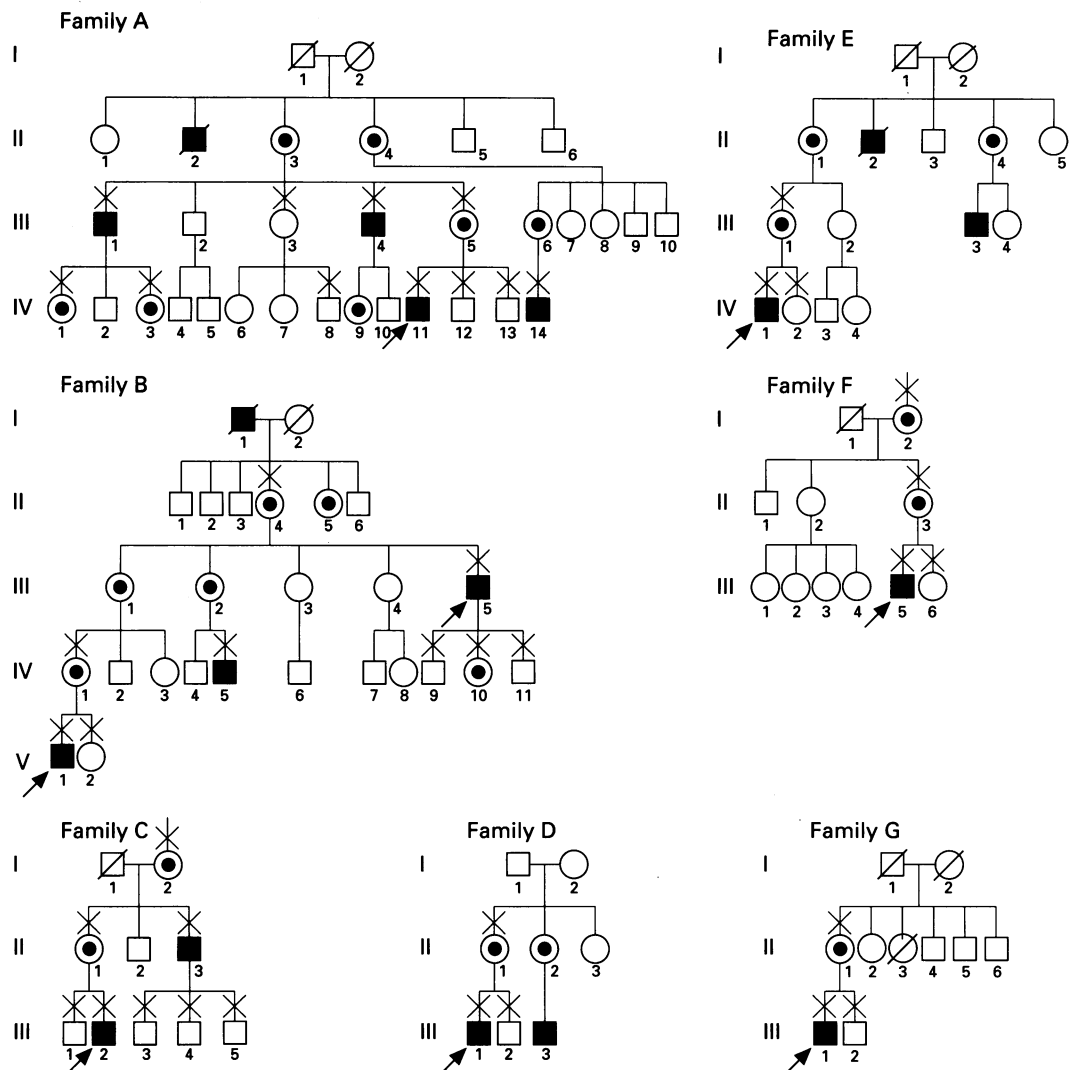


Figure 1 Kindreds of families examined. Family designations (A-G) correspond to those in Table 1. Family B was first thought to consist of two independent families; therefore, two probands are shown (arrows). X identifies individuals examined ophthalmologically.

### Patients and methods

All 13 affected patients in our series are Japanese men (Table 1). Family histories (Fig 1) disclosed X linked inheritance in all seven families. Two families (families F and G) had a few affected family members. However, female members had the mosaic fundus appearance that is characteristic of carriers with XLOA, suggesting X linked inheritance.

Each patient underwent a full ophthalmic examination including best corrected visual acuity, colour vision (Panel D-15 and/or Ishihara plates), and stereopsis (Randot stereotest). Eye movement, strabismus, and nystagmus were assessed. Nystagmus was recorded as absent, horizontal, vertical, rotary, or mixed. Iris colour, grading of translucency, presence of posterior embryotoxon, Axenfeld's anomaly, and megalocornea were also evaluated. Transillumination of the iris was performed during routine slit-lamp examination by transpupillary transillumination as described by Abrams.<sup>14</sup> Fundus photographs, fluorescein angiography, and skin biopsies were performed, when possible. Diagnosis of XLOA was made on the basis of nystagmus, and foveal hypoplasia in affected male patients and pigmentary mosaic fundus in female carriers.

### Results

The clinical characteristics of 13 affected male patients from seven families with XLOA have been summarised in Table 1. Nine affected patients had been diagnosed previously as having congenital motor nystagmus or nystagmus with macular hypoplasia. All patients had dark brown or black hair without albinotic skin.

Visual acuity, which could be measured in 11 affected patients, ranged from 0.05 to 0.4. However, most patients (nine of 11 patients) had visual acuity between 0.2 and 0.4. Visual acuity did not deteriorate with time and varied little among families.

Refractive errors were as follows. Spherical errors ranged from -4.0 dioptres (DS) to +3.0 (DS); cylindrical errors ranged from 0 to 5.0 DS; and 15 (68%) of 22 eyes had astigmatism of 2.0 DS or more.

Five affected patients had exotropia. All affected patients had horizontal nystagmus. Older patients demonstrated reduced amplitude with time. We found no relation between visual acuity and amplitude of nystagmus, although precise measurements of amplitude were not conducted. No affected patients revealed stereopsis using the Randot stereotest. Colour vision was examined in five patients, and no abnormalities were found.

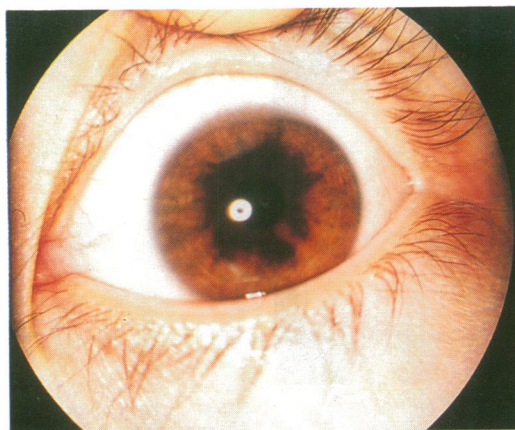


Figure 2 Iris photograph of affected patient 1 shows sufficient pigment resulting in brown iris.

All 13 affected patients had brown or light brown irides that showed no translucency (Fig 2). Slit-lamp examination revealed bilateral posterior embryotoxon in one patient. No patients had Axenfeld's anomaly. Two patients exhibited megalocornea (Fig 3). The sizes of these corneas were 13 mm.

Fundus examination disclosed foveal hypoplasia in all affected patients. The degree of pigmentation was assessed in all affected patients. Fundus was considered non-albinotic if there was sufficient pigment that masked the underlying choroidal vessels. Eleven affected patients had sufficient pigmentation in the fundus (non-albinotic). Two affected patients (patients 7 and 9) with appropriate pigment in the fundus (Fig 4) showed poor visual acuity, while two other affected patients (patients 2 and 11) had little pigmentation (Fig 5) and moderate visual acuity. Fluorescein angiography, which has been performed in two patients (patients 1 and 7) with non-albinotic fundus (Fig 6), disclosed no dark area corresponding to the macula area (Fig 7). The histopathological findings of a skin biopsy that was done in patient 1 showed macromelanosomes (Fig 8).

Thirteen female carriers from seven families were also assessed. All carriers showed good visual acuity, normal eye position, and stereopsis. Their hair was dark brown or black, and their skins were not albinotic. They had brown or light brown irides without the transillumination defect. They all disclosed a mud

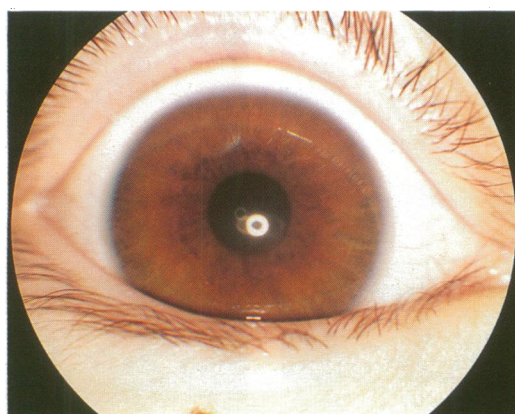


Figure 3 Photograph of the anterior segment of affected patient 11 exhibits megalocornea with brown iris.

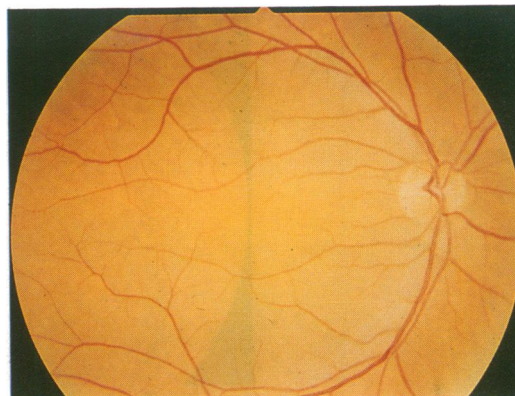


Figure 4 Fundus photograph of affected patient 7 demonstrates sufficient pigment to obscure choroidal vessels.

splattered appearance in both fundi. The mosaic pattern in some carriers was more clearly visible than in others. Fluorescein angiography was useful to detect the posterior embryotoxon, Axenfeld's anomaly, or megalocornea was found in any female carrier.

#### Discussion

In this study, we assessed the clinical characteristics of Japanese patients with XLOA. The visual acuity of these affected male patients ranged from 0.05 to 0.4 and was not progressive. These visual acuities seemed to fall between those of white and black affected patients, suggesting a possible relation between visual acuities and pigmentation in the fundus. It has been reported that affected black patients with XLOA<sup>11</sup> have better visual acuity than do affected white patients. In affected Japanese patients with XLOA, albinotic fundus was found in only two out of 13 patients, while 11 patients disclosed moderate pigmentation. The amount of pigment in the fundus varied among the affected Japanese patients.

Intrafamilial variations in the amount of pigment also could be found: however, pigmentation appeared to be between that of affected white and black patients. Previous reports<sup>15 16</sup> have correlated the severity of albinotic characteristics with the degree of visual pigment. We also examined a patient who had ocular albinism with unilateral

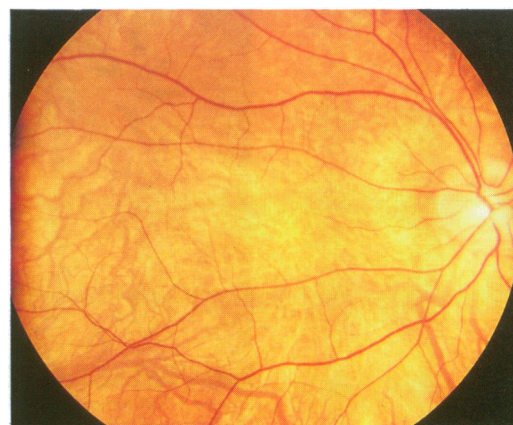


Figure 5 Fundus photograph of affected patient 2 reveals little pigment. Choroidal vessels can be seen.



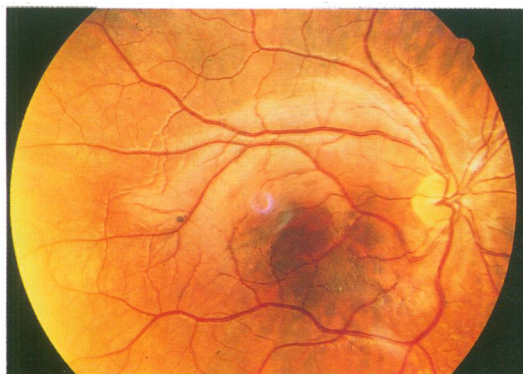


Figure 6 Fundus photograph of affected patient 1 demonstrates sufficient pigment.

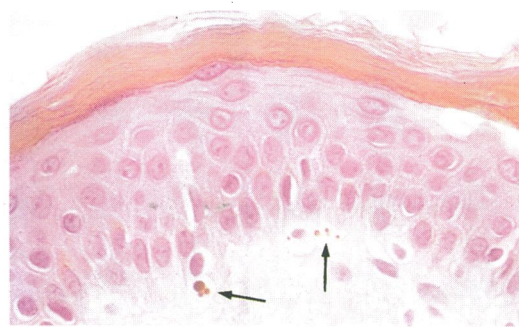

Figure 8 The histology of a skin biopsy from affected patient 1 showed macromelanosomes (arrows). Haematoxylin and eosin,  $\times 200$ .

sectorial pigmentation that reached the macula and good visual acuity.<sup>17</sup> These findings suggested that the amount of pigment may be an important factor in retaining good visual acuity. Other factors, such as macular hypoplasia and nystagmus, also appeared to result in poor visual acuity because some affected patients (such as our case 7) had appropriate pigmentation in the fundus and poor visual acuity.

In our study, many affected patients with XLOA had high refractive errors, including astigmatism, as previously reported.<sup>10</sup> Therefore, some degree of amblyopia resulting from uncorrected refractive errors in early infancy may be related to low visual acuity in XLOA. The early correction of refractive errors should be recommended to obtain better visual acuity, although it is not clear whether a failure of emmetropisation relates to low visual acuity in affected patients with XLOA. The lack of stereopsis and high incidence of strabismus seen in affected white patients<sup>10</sup> were also confirmed in our affected Japanese patients. This relation probably results from the misrouting of the optic nerve. In albino patients, most optic nerve fibres anatomically decussate at the optic chiasma and project to the contralateral hemisphere. This finding was also demonstrated by using visual evoked potentials<sup>18</sup> and positron emission tomography.<sup>19</sup>

Interestingly, all our affected patients had brown or light brown irides without

transillumination. None revealed blue or grey irides, as seen in affected white patients. The pigmentation of the iris and fundus made the correct diagnosis in the affected Japanese patients difficult. Only 30% of the affected patients were correctly diagnosed as having XLOA. The other 70% of the affected patients had been misdiagnosed as having congenital nystagmus, with or without macular hypoplasia. Therefore, XLOA should be considered in all male infants with nystagmus. The most predictable clinical signs of XLOA in affected Japanese patients were nystagmus and macular hypoplasia, which are seen in all affected patients.

Examination of the affected patients' mothers helps make the correct diagnosis, especially in a small family, because all female carriers have shown pigmentary mosaicism of the retinal pigment epithelium in their fundi. Fluorescein angiography was useful in the detecting of pigment mosaicism in the carriers' fundi when the mosaic was faint. We performed skin biopsy in only one affected patient who showed macromelanosome. Skin biopsy was previously performed in two Japanese patients,<sup>3,13</sup> both of whom showed macromelanosomes. Skin biopsy could, therefore, be helpful in making the correct diagnosis in Japanese patients as well as in white<sup>7,10</sup> and black patients.<sup>11</sup>

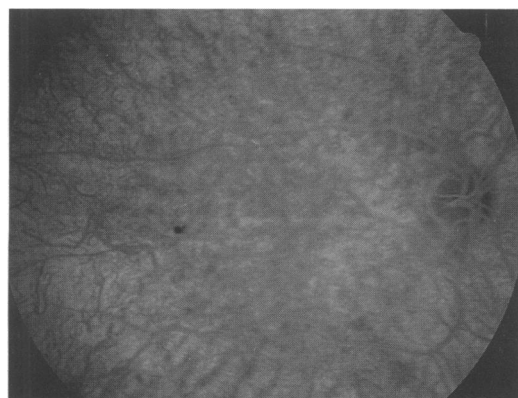

Figure 7 Fluorescein angiogram of affected patient 1 discloses no dark area corresponding to the macula. Choroidal vessels are not clearly visible because of pigment in the retinal pigment epithelium.

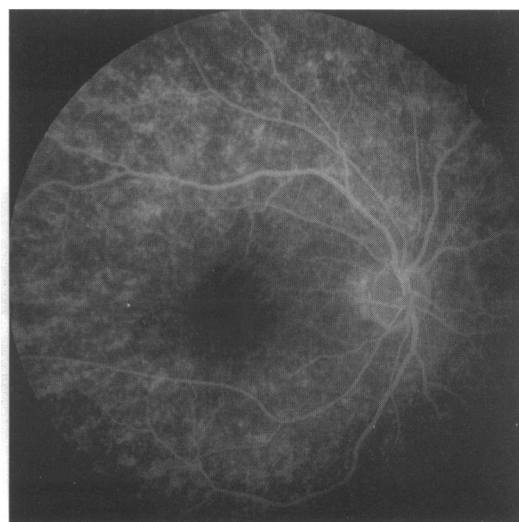


Figure 9 Fluorescein angiogram of a female carrier shows clearly the mosaic pattern in the fundus.

Posterior embryotoxon was found in one affected patient and megalocornea was seen in two affected patients in our study. Posterior embryotoxon which occurs from mild dysgenesis of the anterior segment is commonly found in affected white patients with XLOA.<sup>10</sup> Megalocornea is often inherited as X linked recessive disease.<sup>20</sup> The recent molecular biological approach has revealed that the locus of megalocornea is on Xq12-q26 – that is, a different locus from that of XLOA.<sup>21 22</sup> XLOA is thought to be linked to Xp22.3. In addition, megalocornea was not definitely cosegregated with XLOA, suggesting that megalocornea may also result from mild dysgenesis of the anterior segment as with posterior embryotoxon.

This study was supported in part by grant in aid for scientific research from the Ministry of Education, Science and Culture, Japan.

- 1 Nettleship E. On some hereditary diseases of the eye. *Trans Ophthalmol Soc UK* 1909; **29**: 41–50.
- 2 van Dorp DB, Delleman JW, Loewer-Sieger DH. Oculocutaneous albinism and anterior chamber cleavage malformations. *Clin Genet* 1984; **26**: 440–4.
- 3 Hayakawa M, Kato K, Nakajima A, Yoshiike T, Ogawa H. Nettleship-Falls X-linked ocular albinism with Axenfeld's anomaly. A case report. *Ophthalmol Paediatr Genet* 1986; **7**: 109–14.
- 4 Awaya S, Iwamura Y, Yasuma T, Sugita J, Ichikawa H. Ocular findings of genetic carrier of X-linked ocular albinism. *Rinsho Ganka (Jpn)* 1978; **32**: 750–1.
- 5 Spedick MJ, Beauchamp GR. Retinal and optic nerve abnormalities in albinism. *J Pediatr Ophthalmol Strabismus* 1986; **23**: 58–63.
- 6 Falls HF. Sex-linked ocular albinism displaying typical fundus changes in the female heterozygote. *Am J Ophthalmol* 1951; **34**: 41–50.
- 7 O'Donnell FE Jr, Hambrick GW, Green WR, Iliff WJ, Stone DL. X-linked ocular albinism: an oculocutaneous macromelanosomal disorder. *Arch Ophthalmol* 1976; **94**: 1883–92.
- 8 Cortin P, Tremblay M, Lemagne JM. X-linked ocular albinism: relative value of skin biopsy, iris transillumination and funduscopy in identifying affected males and carriers. *Can J Ophthalmol* 1981; **16**: 121–2.
- 9 Charles SJ, Moore AT, Grant JW, Yates JRW. Genetic counselling in X-linked ocular albinism: clinical features of the carrier state. *Eye* 1992; **6**: 75–9.
- 10 Charles SJ, Green JS, Grant JW, Yates JRW, Moore AT. Clinical features of affected male with X linked ocular albinism. *Br J Ophthalmol* 1993; **77**: 222–7.
- 11 O'Donnell FE Jr, Green WR, Fleischman JA, Hambrick GW. X-linked ocular albinism in blacks: ocular albinism cum pigmento. *Arch Ophthalmol* 1978; **96**: 1189–92.
- 12 Hagiwara S, Masuyama Y, Kodama Y, Matsuura Y, Kodama Y, Sawada A. Case report of a family with X-linked ocular albinism. *Ganki (Jpn)* 1986; **37**: 1220–4.
- 13 Hayakawa M, Kanai A, Kato K, Nakajima A, Takamori K. A Japanese family of Nettleship Falls X-linked ocular albinism. *Nippon Ganka Gakkai Zasshi (Jpn)* 1990; **94**: 1181–7.
- 14 Abrams JD. Transillumination of the iris during routine slit-lamp examination. *Br J Ophthalmol* 1964; **48**: 42–4.
- 15 Witkop CJ, Quevedo WC, Fitzpatrick TB. Albinism and other disorders of pigment metabolism. In: Stanbury JB, Wyngaarden JB, Fredrickson DS, eds. *The metabolic basis of inherited disease*. New York: McGraw-Hill, 1983: 301–46.
- 16 Kinnear PE, Jay B, Witkop CJ. Albinism. *Surv Ophthalmol* 1985; **30**: 75–101.
- 17 Shiono T, Mutoh T, Chida Y, Tamai M. Ocular albinism with unilateral sectorial pigmentation in the fundus. *Br J Ophthalmol* 1994; **78**: 412–3.
- 18 Russell-Eggitt I, Kriss A, Taylor DS. Albinism in childhood. A flash VEP and ERG study. *Br J Ophthalmol* 1990; **74**: 136–40.
- 19 Nakagawa Y, Kiyosawa M, Tamai M, Iro M. Positron emission tomography and <sup>18</sup>F-fluorodeoxyglucose for the detection of visual pathway abnormalities in albinism. *Am J Ophthalmol* 1993; **116**: 112–3.
- 20 Mackey DA, Buttery RG, Wise GM, Denton MJ. Description of X-linked megalocornea with identification of the gene locus. *Arch Ophthalmol* 1991; **109**: 829–33.
- 21 Schnur RE, Nussbaum RL, Anson-Cartwright L, McDowell C, Worton RG, Musarella MA. Linkage analysis in X-linked ocular albinism. *Genomics* 1991; **9**: 605–13.
- 22 Charles SJ, Moore AT, Yates JRW. Genetic mapping of X-linked ocular albinism: linkage analysis in British families. *J Med Genet* 1992; **29**: 552–4.