

## LETTERS TO THE EDITOR

## Choroidal malignant melanoma in association with oculodermal melanocytosis in a black patient

A F Bordon, M L Wray, R Belfort, I W McLean, M Burnier

Oculodermal melanocytosis (ODM) is a congenital melanocytic hyperpigmentation of the face and ocular tissues. The eponym naevus of Ota as described by Ota<sup>1</sup> has been used interchangeably with ODM and ocular melanosis (OM) in many reported cases. The original definition by Ota included patients with and without ocular involvement. For these reasons, we will refer to the term oculodermal melanocytosis, as suggested by Fitzpatrick<sup>2</sup> to describe this patient's condition.

### Case report

A 65-year-old black woman native of Brazil complained about painless decreased vision in her right eye for 5 months. Her past ocular history revealed a dark pigmentation of her right periocular skin and sclera. She stated that the pigmentation was present since birth with a noticeable increase during puberty. The patient's family history as well as her past medical history were unremarkable. The external examination revealed hyperpigmentation of her right periocular skin. The visual acuity with the best correction was hand movements in the right eye. The slit-lamp examination showed in the right eye pigmentation in all four quadrants of the sclera and episclera as well as in the lid margin (Fig 1). The lens had a 2+ nuclear opacity and a 2+ posterior subcapsular cataract. Her left eye was unremarkable except for a 2+ nuclear opacity of the lens. The intraocular pressure was 12 mm Hg in both eyes. Funduscopy findings revealed a

retinal detachment on the temporal side extending superiorly and inferiorly secondary to a dark choroidal mass that came towards the vitreous cavity. The left fundus was unremarkable. The B scan revealed a mushroom-shaped choroidal mass with partial retinal detachment in accordance with malignant melanoma. A medical examination, including liver enzyme studies, complete blood cell count, and chest x ray, revealed no evidence of metastasis. According to these findings and because of the large size of the tumour an uncomplicated enucleation was performed. The pathological findings showed the sclera diffusely pigmented and transillumination revealed an oval shadow on the superior temporal quadrant. After the eye was opened, a heavily pigmented choroidal tumour measuring 16×10×8 mm was disclosed. Overlying the tumour the retina was detached and the uvea was diffusely pigmented (Fig 2). The microscopic study (Fig 3) revealed a pigmented tumour composed of spindle and epithelioid cells confined to the uvea and extending to the pars plana of the ciliary body. Diffusely scattered pigmented fusiform and dendritic melanocytes were present in the optic nerve head, trabecular meshwork, sclera, episclera, and choroid.

### Comment

Since the first case reported by Hulke<sup>3</sup> in 1861, approximately 700 cases of ODM have

Retina Associates, 100  
Charles River Plaza,  
2nd Floor, Boston, MA  
02114, USA  
A F Bordon  
M L Wray  
R Belfort  
I W McLean  
M Burnier

Correspondence to:  
Dr A F Bordon,  
Departamento de  
Ofthalmologia, Escola Paulista  
de Medicina, Rua Botucatu,  
820, Sao Paulo, SP, Brazil  
04043.

Accepted for publication  
5 September 1994

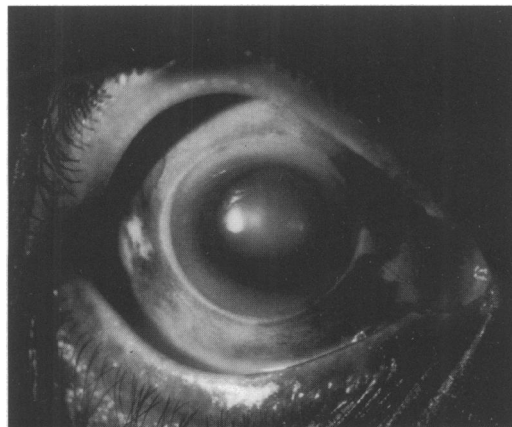


Figure 1 Slit-lamp photography of the patient's right eye showing the pigmentation in all four quadrants of the sclera and in the lid margin as well as a dark pigmentation in the periocular skin.

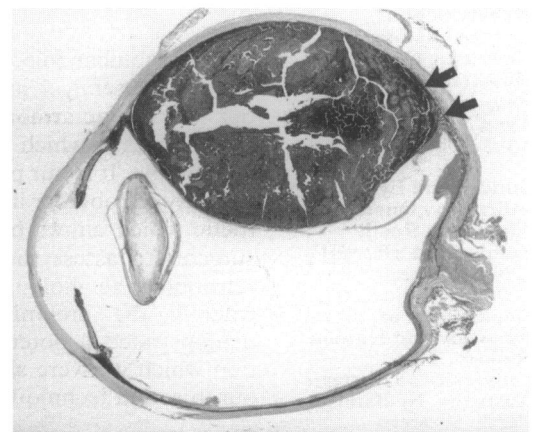


Figure 2 A histopathological specimen revealed a heavy pigmented tumour confined to the uvea extending to the pars plana of the ciliary body. At the border of the tumour with the sclera (arrows) there is a transition between the melanocytes without atypia with the malignant melanoma (haematoxylin and eosin; whole mount).

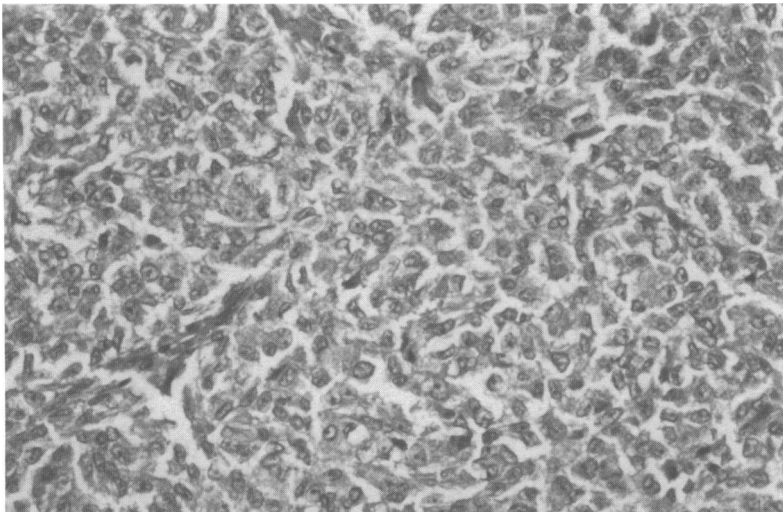


Figure 3 Microscopically the tumour revealed a mixture of malignant spindle cell and epithelioid cells (haematoxylin and eosin; magnification  $\times 25$ ).

been reported in the world literature.<sup>4</sup> The cutaneous pigmentation commonly involves the ophthalmic, maxillary, and occasionally the mandibular division of the trigeminal nerve. Oculodermal melanocytosis occurs most often in orientals and blacks and is rarely seen in the white population.<sup>2 5-7</sup> In contrast, malignant melanoma transformation associated with ODM and OM is known to occur more often in whites and rarely among blacks and orientals.<sup>5 7-9</sup> The rarity of black patients reported with ODM and choroidal melanoma is supported by only two previous case reports: Nik *et al*<sup>7</sup> reported a case of a 44-year-old

black woman with a mixed cell type melanoma and ODM. Velazquez<sup>9</sup> reported a 40-year-old black woman with bilateral ODM with a mixed cell malignant melanoma occurring in the more heavily pigmented eye (right eye).

Diagnosis of ODM in a black patient may be difficult. The dermal pigment may be difficult to detect because of the dark skin pigmentation and the ocular involvement may be confused with racial melanosis. In a situation with unilateral hyperpigmentation of the ocular tissues, the discrepancy between racial melanosis may be easier. With careful history and physical examination, the dermal pigment may be noticed.

- Ota M. Naevus fusco-caeruleus ophthalmo-maxillaris. *Tokyo Med J* 1939; **63**: 1243-5.
- Fitzpatrick TB, Zeller R, Kukita A, Kitamura H. Ocular and dermal melanocytosis. *Arch Ophthalmol* 1956; **56**: 830-2.
- Hulke JW. A series of cases of carcinoma of the eyeball. *Royal London Ophthalmic Hospital Reports* 1861; **3**: 279-86.
- Teekhasaene C, Ritch R, Rutnin U, Leelawongs N. Ocular findings in oculodermal melanocytosis. *Arch Ophthalmol* 1990; **108**: 1114-20.
- Dutton JJ, Anderson RL, Schelper RL, Purcell JJ, Tse DT. Orbital malignant melanoma and oculodermal melanocytosis: report of two cases and review of the literature. *Ophthalmology* 1984; **91**: 497-507.
- Cowan TH, Balistocky M. The nevus of Ota or oculodermal melanocytosis: the ocular changes. *Arch Ophthalmol* 1961; **65**: 483-92.
- Nik NA, Glew WB, Zimmerman LE. Malignant melanoma of the choroid in the nevus of Ota of a black patient. *Arch Ophthalmol* 1982; **100**: 1641-3.
- Wilkes TD, Uthman EO, Thornton CN, Cole RE. Malignant melanoma of the orbit in a black patient with ocular melanocytosis. *Arch Ophthalmol* 1984; **102**: 904-6.
- Velazquez N, Jones IS. Ocular and oculodermal melanocytosis associated with uveal melanoma. *Ophthalmology* 1983; **90**: 1472-6.

*British Journal of Ophthalmology* 1995; **79**: 192-194

## Precautionary note on retrobulbar alcohol injections

Suzanne K Webber, Charles N J McGhee, Paul G McMenamin

Department of  
Ophthalmology,  
Newcastle General  
Hospital, Westgate  
Road, Newcastle upon  
Tyne NE4 6BE  
S K Webber

Sunderland Eye  
Infirmary, Queen  
Alexandra Road,  
Sunderland SR2 9HP  
C N J McGhee

Department of  
Anatomy and Human  
Biology, The  
University of Western  
Australia, Nedlands,  
Perth, Western  
Australia 6009  
P G McMenamin

Correspondence to:  
Professor C N J McGhee.

Accepted for publication  
20 October 1994

The retrobulbar injection of alcohol for analgesia is a useful, if infrequently used, tool in our therapeutic armoury for those with blind, painful eyes in which enucleation is refused or inadvisable. It is our practice to perform a preliminary retrobulbar injection with local anaesthetic which allows both the patient and the surgeon to assess the potential benefit of a retrobulbar alcohol injection. We report a case wherein the preliminary anaesthetic block demonstrated a potentially serious complication which we were able to avoid by adapting our injection technique.

### Case report

The patient, a 54-year-old woman, was referred with a blind, painful right eye following a course of radiotherapy for a maxil-

lary antrum carcinoma. Conservative treatment with oral analgesia and topical lubricants failed to control the ocular pain and it was concluded that a retrobulbar alcohol injection should be performed. A preliminary injection of 5 ml 0.75% bupivacaine was administered using a 25 gauge 40 mm straight Atkinson retrobulbar needle (code no 1275, Steriseal, Redditch, England). The surgeon noted that the orbital tissues resisted the passage of the retrobulbar needle. The following day the patient reported beneficial ocular analgesia lasting several hours; however, she also observed that the 'whole' of the right side of her face had also been 'numbed'.

The injection was repeated and again the surgeon noted a stiffness of the orbital tissues which was sufficient to prevent the usually smooth unrestricted course of the needle