

# Infantile presentation of X linked retinoschisis

N D L George, J R W Yates, K Bradshaw, A T Moore

## Abstract

**Five infants who presented with nystagmus and/or strabismus were found to have bilateral highly elevated bullous retinoschisis involving the macula. Haemorrhage was present within the schisis cavity or the vitreous in four patients. The bullous retinoschisis eventually re-attached spontaneously leaving pigment demarcation lines. A family history of X linked retinoschisis (XLRs) was known in two of the patients but in the other three subsequent investigation showed other male family members to be affected. It is important to recognise this uncommon presentation of XLRs so that the correct diagnosis is made and appropriate genetic counselling is given. Surgical treatment is not usually indicated and the visual prognosis is better than the initial appearance may suggest.**

(*Br J Ophthalmol* 1995; 79: 653-657)

X linked retinoschisis (XLRs) is an uncommon retinal dystrophy which usually presents when poor vision is noted in the school classroom or on visual screening. The characteristic feature is foveal retinoschisis<sup>1</sup> but about half of the patients also have peripheral retinoschisis.<sup>2</sup> Other peripheral changes such as perivascular sheathing,<sup>3</sup> dendritiform patterns,<sup>4</sup> neovascularisation,<sup>5</sup> pigmentary mottling, and a tapetal-like reflex<sup>6</sup> may also be seen. Histopathology has shown the splitting to occur superficially in the nerve fibre layer and inner limiting membrane and a defect in the Müller cell has been suggested.<sup>7-9</sup> The demonstration of a normal a-wave but diminished b-wave on the electroretinogram also supports this theory.<sup>10</sup> Genetic linkage studies have mapped the gene to the Xp22 region with no evidence of genetic heterogeneity.<sup>11</sup>

Although the diagnosis of XLRs is usually made when the patient is of school age, patients with severe visual loss may present earlier with strabismus and nystagmus.<sup>12-16</sup> The unusual presentation and atypical retinal findings of XLRs presenting in infancy may lead to difficulties in diagnosis especially if there is no previous family history. We wish to draw attention to this mode of presentation of X linked retinoschisis with the following series of five cases.

## Patients and methods

### PATIENTS

Seventeen unrelated pedigrees with XLRs were ascertained from around the United Kingdom as part of a research project into the

disease. All members of the families were examined by one ophthalmologist (NDLG). Five patients from five pedigrees had presented before the age of 2 years with features that were quite distinct from the usual mode of presentation.

### ELECTRORETINOGRAPHY

The electroretinogram (ERG) procedure complied with internationally agreed standards.<sup>17</sup> The pupils were dilated with cyclopentolate 1% and the patient then dark adapted for 20 minutes. The ERG was recorded using gold foil electrodes located in the inferior conjunctival fornix. The ERG signal was amplified with a gain of  $1 \times 10^4$  over a bandwidth of 0.8-800 Hz and fed into the analogue to digital converter of a laboratory computer. Sampling rate was 1 kHz and sweep time 200 ms (rod responses) or 100 ms (cone responses). Four to 64 responses were averaged, depending on signal size.

The stimulus was a xenon flash (10  $\mu$ s duration) delivered via a diffusing sphere (Ganzfeld) so as to provide full field even illumination. Eye position was monitored during the procedure via a low light level CCD camera with a pinhole lens mounted within the Ganzfeld enclosure. Stimulus intensity was attenuated using neutral density filters (Kodak-Wratten). Following the period of dark adaptation, rod responses were recorded to seven stimuli of increasing intensity in 1 log unit steps, the final brightest stimulus having an intensity of 4 cd m<sup>-2</sup> s, which corresponds to the recommended standard flash.<sup>17</sup> The eyes were then exposed to a rod desensitising background of 25 cd m<sup>-2</sup> for 10 minutes, after which cone responses were recorded first to an intensity series (0.3 log unit steps) and finally to 30 Hz flicker.

Abnormal values were defined as those which fell outside 2 SD of the mean obtained from 20 controls.

### CASE 1

This young boy was normal up to the age of 15 months when his mother noticed nystagmus and head nodding. He was referred to the paediatricians who noted mild ataxia and made a provisional diagnosis of a space occupying lesion or viral encephalitis. Subsequent computed tomography and magnetic resonance imaging scans were normal and after a period of observation he was discharged home. Over the next few weeks, the nystagmus lessened and became intermittent. He was eventually referred to an ophthalmologist who elicited a history of poor vision in two of the boy's four maternal uncles.

Department of  
Ophthalmology,  
Addenbrooke's NHS  
Trust, Cambridge  
N D L George  
A T Moore

Department of  
Clinical Genetics,  
Addenbrooke's NHS  
Trust, Cambridge  
N D L George  
J R W Yates

Department of  
Pathology, Cambridge  
University, Cambridge  
J R W Yates

Vision Science,  
Addenbrooke's NHS  
Trust, Cambridge  
K Bradshaw

Moorfields Eye  
Hospital, London  
A T Moore

Correspondence to:  
Mr N D L George,  
Department of  
Ophthalmology, St James's  
University Hospital, Beckett  
Street, Leeds LS9 7TF.

Accepted for publication  
14 February 1995

Figure 1 Right and left fundus photographs of case 1, showing bilateral pigment demarcation lines, with pigment epithelial atrophy inferiorly where the bullous retinoschisis has regressed.

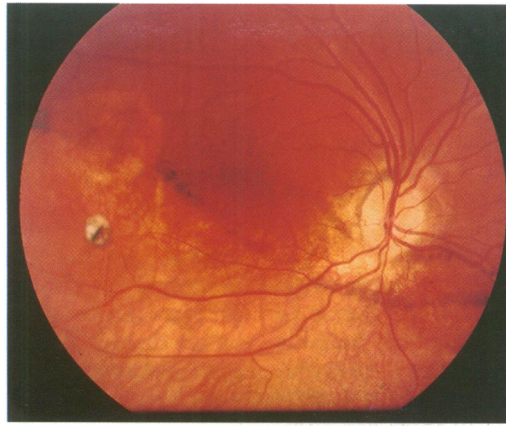


Fig 1A

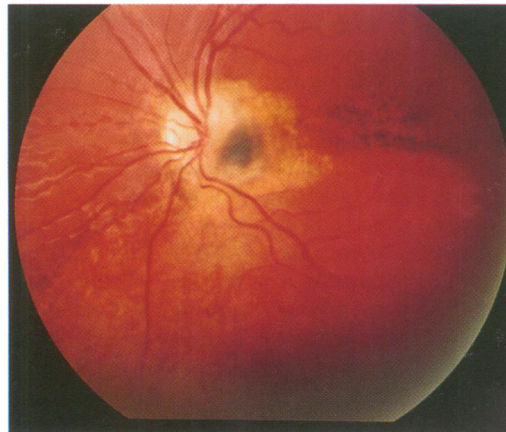


Fig 1B

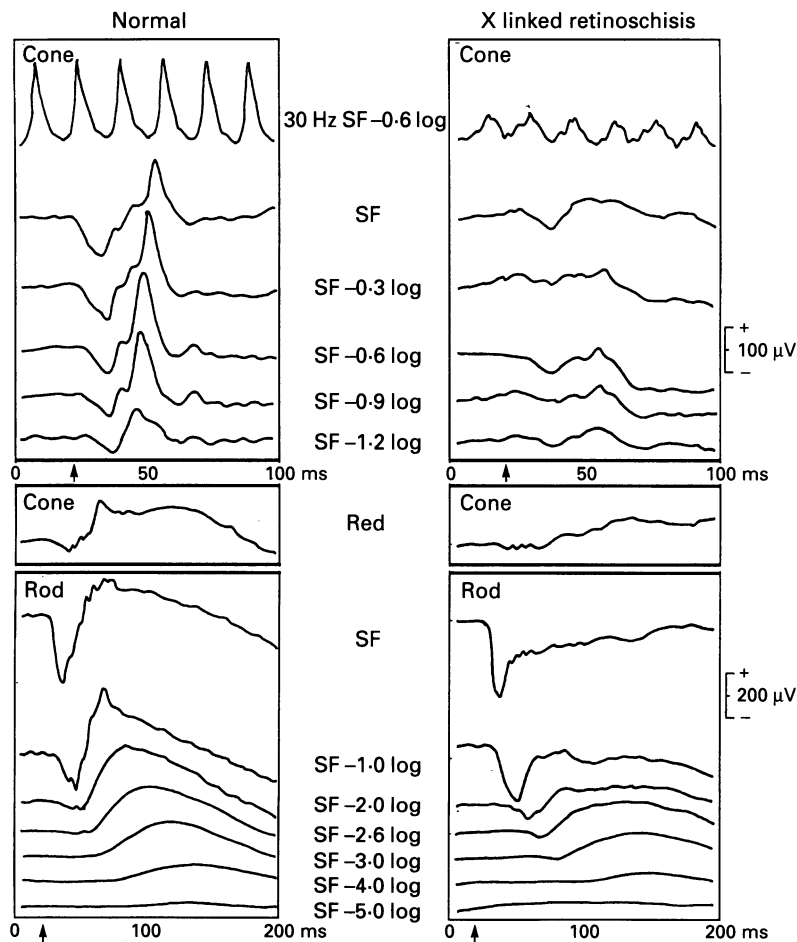


Figure 2 Electrophoretogram of maternal cousin of case 2 compared with the normal. The b-wave amplitude is reduced in the dark adapted series and fails to reach the isoelectric point in response to the bright white flash. A-waves are of normal amplitude, but cone responses and 30 Hz flicker are abnormal. Arrow indicates the timing of the flash stimulus. SF=standard flash.

On examination at 20 months of age, he could fix with either eye and there was no evidence of squint or nystagmus. Fundus examination revealed bilateral highly elevated bullous retinoschisis bisecting the maculae. There was some haemorrhage within the schisis cavity in the left eye. There were no retinal breaks. It was decided to manage him conservatively. Over the next 12 months the bullous retinoschisis gradually flattened leaving bilateral pigment demarcation lines over the inferior half of the retina.

On examination at the age of 5 years, his best corrected visual acuity was 6/36 in each eye and N8 for near. There was a small left esotropia. Anterior segments were normal and the vitreous was attached in both eyes with no evidence of vitreous veils. Fundus examination showed bilateral pigment lines extending across both inferotemporal retinae and bisecting the macula on the right (Fig 1). There was mild atrophy of the pigment epithelium inferior to the pigment demarcation lines but the retina was flat.

Examination of other family members revealed that two maternal uncles and a maternal great uncle had poor vision and foveal schisis. An ERG to a bright white flash recorded from one of the uncles showed normal a-wave (252  $\mu$ V) but reduced b-wave amplitudes (217  $\mu$ V) with a b-wave that failed to reach the isoelectric point. (Normal values for the standard flash were: a-wave mean 322 (SD 65)  $\mu$ V; b-wave mean 466 (SD 91)  $\mu$ V.)

#### CASE 2

This patient presented at the age of 3 months after his mother had noted a squint. He could fix with his right eye but was found to have very poor responses in his left eye. Fundus examination revealed bilateral bullous retinoschisis. In the right eye bullous schisis extended up to the inferior vascular arcade associated with intraschisis and vitreous haemorrhage. The left eye showed more severe changes with extensive retinoschisis complicated by an inferior half retinal detachment extending through the macula. There was an outer leaf break just below the inferotemporal retinal vessels. The retinal detachment was thought to be inoperable.

On examination at the age of 18 months, he could fix and follow small targets with the right eye but poorly with the left eye. There was a small left exotropia and hypertropia. The retinoschisis in the left eye had spontaneously flattened, leaving a pigment demarcation line through the fovea. The bullous schisis in the right eye showed incomplete regression, remaining outside the inferotemporal retinal arcade.

Other family members were examined; a maternal half brother aged 14 years had bilateral foveal and peripheral retinoschisis and a maternal cousin had foveal schisis. His deceased maternal grandfather had been blind and had one eye removed in childhood. An ERG performed on the cousin showed a normal a-wave amplitude (292  $\mu$ V) but

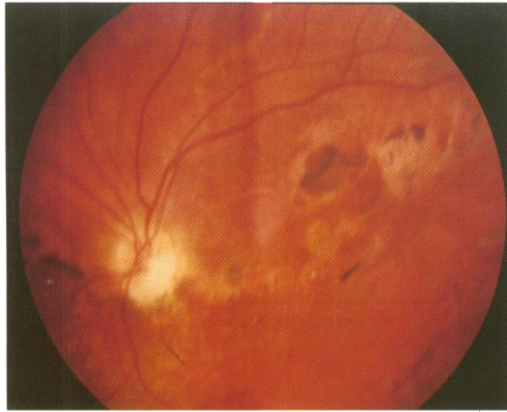


Figure 3 Left fundus photograph of case 3 showing a pigment demarcation line. The view of the right eye was obscured by a recent vitreous haemorrhage.

reduced b-wave (245  $\mu$ V) to a bright white flash (Fig 2).

#### CASE 3

At the age of 5 months this young boy's mother noted poor vision and horizontal and vertical nystagmus. He was found to have bilateral retinal abnormalities and an examination under anaesthetic (EUA) performed at the age of 18 months revealed bilateral bullous retinoschisis involving both maculae. It was decided to manage him conservatively.

On examination at the age of 5 years, his best corrected visual acuities were 4/60 right and 3/60 left. There was a moderate left esotropia but no nystagmus. The right fundus showed a mild vitreous haemorrhage and a large schitic membrane in the inferotemporal region, attached to the disc. There appeared to be vessels running within the membrane. There was pigment deposition at the macula and pigment clumping elsewhere. The left fundus had a more extensive membrane across the whole of the inferior fundus and again, attached to the disc margin. There was an arcuate gap in the membrane at the posterior pole but the macular details were difficult to discern. There were areas of marked pigment clumping as well as a pigment demarcation line running from 3 o'clock to 9 o'clock (Fig 3).

The patient's 9-year-old maternal half-brother had bilateral foveal schisis and a small vitreous veil in his right eye (Fig 4). His ERG to a bright white flash showed normal a-wave

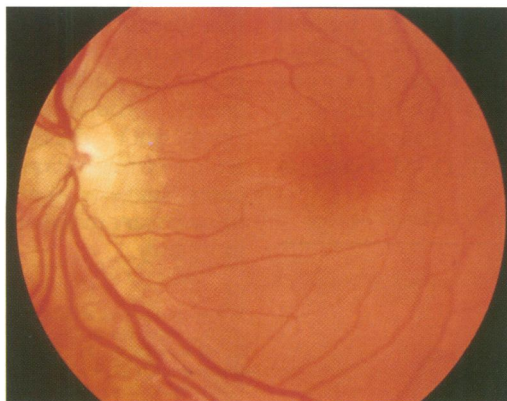


Figure 4 Fundus photograph left eye of maternal half brother of case 3, showing typical foveal schisis.

amplitudes (234  $\mu$ V) but a b-wave that did not reach the isoelectric point (211  $\mu$ V).

#### CASE 4

This boy presented at the age of 5 months with nystagmus. He could fix and follow bright objects equally with both eyes. Fundus examination revealed bilateral retinal abnormalities. At EUA there was a large schisis in the upper temporal retina of the right eye associated with vitreous haemorrhage inferiorly. There was some fine pigment mottling at the macula distributed in a linear fashion. The left eye showed more extensive retinoschisis in the superior and inferior retina and vitreous haemorrhage, which obscured the macula.

The nystagmus gradually resolved. On examination at the age of 7 years, his best corrected visual acuities were 6/24 right and 6/60 left with N9 near. There was a small left esotropia. There were bilateral small vitreous veils. Both maculae showed typical foveal schisis. There was a pigment demarcation line in the superotemporal retina of the right eye and both superiorly and inferiorly in the left eye.

Subsequent examination of other family members revealed that his two brothers had typical foveal schisis bilaterally. An 11-year-old cousin, who had suffered recurrent vitreous haemorrhages in early childhood, had an unusual bilateral maculopathy which consisted of punched out areas of pigment atrophy.

#### CASE 5

This patient is from an eight generation pedigree, including 16 affected males, which formed an early publication of XLRS.<sup>18</sup> He suffered an attack of meningitis at the age of 1 month, after which he was found to have poor vision and nystagmus. He was eventually diagnosed as having retinoschisis at the age of 3 years when it was ascertained that there was an extensive family history of poor vision in males. There are no details available of the fundus appearance at this time. His left eye never had much useful vision and, following a cosmetic cataract extraction at the age of 13 years, he was found to have a total fibrotic retinal detachment and no perception of light. The vision in his right eye has since remained stable.

On examination at the age of 28 years, the best corrected visual acuity in his right eye was 3/36 and he could read N10. He had a marked esotropia with rotary nystagmus. The retina showed extensive changes: there was a pigment demarcation line extending from 4 o'clock to 9 o'clock and gross pigment mottling elsewhere. Inferiorly there was shallow schisis. The vascular pattern was barely discernible with gross attenuation and sheathing of retinal vessels. A persistent hyaloid remnant ran from the disc to a posterior polar opacity of the lens.

#### Discussion

This series of patients illustrates an unusual infantile presentation of XLRS. All the patients

Table 1 Findings in five patients with X linked retinoschisis presenting in infancy

Case	Age at presentation	Nystagmus	Squint	Bullous retinoschisis	Haemorrhage	Pigment lines	Final vision	No affected in family
1	15/12	+	-	R+L	Intracyst, vitreous	R+L	R 6/36 L 6/36	4
2	3/12	-	HT	R+L	Intracyst, vitreous	R+L	Fixes R>L	4
3	5/12	+	ET	R+L	Vitreous	R	R 4/60 L 3/60	2
4	5/12	+	ET	R+L	Vitreous	R+L	R 6/24 L 6/60	4
5	3/12	+	ET	nk	nk	R	R 6/60 L NPL	16

HT=hypertropia; ET=esotropia, +=present; -=absent; nk=not known.

presented in the first 18 months of life with either nystagmus, strabismus, or both (Table 1). Highly elevated bullous retinoschisis involving the macula was observed in four of the five cases and in case 5 the presence of typical pigment lines across the inferior half of the retina suggests that he showed a similar evolution of the disease. Nystagmus developed at 15 months of age in case 1 and at 2 months in the other cases, suggesting that the bullous retinoschisis may not have been present at birth but developed later. In all cases the retinoschisis subsequently flattened with resolution of the nystagmus in all except case 5. The visual prognosis was better than might have been expected from the appearance in infancy. The most recent visual acuities of these patients ranged from 6/36 to 3/60 (although one patient had no perception of light in one eye) and the near vision was often surprisingly good, being between N8 and N10.

XLRS may be confused with other conditions which cause elevation of the retina in infancy (Table 2) and some eyes with XLRS have been enucleated for suspected retinoblastoma.<sup>7 19</sup> An important clue to the diagnosis of XLRS is the presence of intraschisis or vitreous haemorrhage,<sup>3 15 20 21</sup> which was seen in four of our cases. The haemorrhage may arise either from rupture of unsupported retinal vessels<sup>15</sup> or from new vessels.<sup>22</sup>

Although XLRS presenting with squint and nystagmus in infancy has been mentioned in a number of case reports<sup>12-15</sup> only one report has described similar cases, in which two infants who presented with squint and nystagmus subsequently underwent spontaneous flattening of the retinoschisis cavity.<sup>16</sup> Others have noted changes in the elevation and distribution of the retinoschisis cavities during infancy.<sup>22-24</sup> In nine of 10 eyes reported here, the bullous retinoschisis cavity spontaneously flattened leaving only pigment demarcation lines. The presence of pigment lines is significant as it would suggest that there had been an underlying retinal detachment (J D M Gass, in

discussion of paper by Grenen *et al*<sup>15</sup>); histologically, pigment lines represent retinal pigment epithelial cell hyperplasia and in order for pigment cells to migrate into the schisis cavity there would have to be either a retinal detachment or an outer leaf break present.<sup>25-27</sup> In this series outer leaf breaks were identified only in case 2, but vitreous and intraschisis haemorrhage may have precluded a clear view of the outer leaf of the schisis cavity in other cases.

Spontaneous flattening of the retina is known to occur in non-rhegmatogenous conditions such as retinopathy of prematurity<sup>28</sup> and optic disc coloboma,<sup>29</sup> and has been described in XLRS.<sup>2 30</sup> The mechanism leading to spontaneous flattening of the schisis cavity (and any underlying retinal detachment) in XLRS, however, remains unclear. The presence of vitreous veils in case 4 suggests that in this patient regression of retinoschisis cavity may in part be explained by fragmentation of the inner leaf.<sup>31 32</sup> Accumulation of an amorphous hyaluronidase negative material in retina and blood vessels adjacent to the schisis cavity has been reported.<sup>9</sup> Discharge of this substance into the vitreous cavity through inner leaf breaks, accompanied by intraschisis and vitreous haemorrhage, could explain spontaneous flattening in other cases.

Recognition of this infantile presentation of XLRS is of importance as this may be the first presentation of the disease to an ophthalmologist. A careful family history and examination of male siblings or maternal male relatives will often allow confirmation of the diagnosis. Three of the above patients were the first to be diagnosed within the family. Further confirmation of the diagnosis can be made by electrophysiology. A characteristic reduction in b-wave amplitude is virtually always seen in this disease.<sup>10 33</sup> Although there is at present no treatment for the disease, recognition of previously undiagnosed cases is important for genetic counselling and for prognosis. Furthermore, the high rate of spontaneous flattening of the bullous retinoschisis seen in our cases suggests that surgical intervention is unnecessary in the majority of cases presenting in infancy.

Table 2 Causes of bilateral retinal elevation in infancy

X linked retinoschisis
Retinoblastoma
Vitreoretinal dysplasias
Norries disease
Incontinentia pigmenti
Autosomal recessive vitreoretinal dysplasia
Familial exudative vitreoretinopathy
Trauma
Retinopathy of prematurity
Optic disc coloboma

We wish to acknowledge the help of Professor D McLeod (Manchester Royal Eye Infirmary), Miss U K Goddard (Hull Royal Infirmary), Mr A B Richards (Royal Berkshire Hospital, Reading), Dr D Wellesley (Churchill Hospital, Oxford), Dr J Clayton-Smith (St Mary's Hospital, Manchester), Dr G Turner (St James's Hospital, Leeds), and Ms K Haslam (photography). Mr N D L George is in grateful receipt of a research grant from Guide Dogs for the Blind Association.

- 1 Deutman AF. Sex-linked juvenile retinoschisis. In: Deutman AF, ed. *The hereditary dystrophies of the posterior pole of the eye*. Assen, The Netherlands: Van Gorcum, 1971: 48-98.
- 2 Kellner U, Brummer S, Foerster MH, Wessing A. X-linked congenital retinoschisis. *Graefes Arch Clin Exp Ophthalmol* 1990; 228: 432-7.
- 3 Ewing CC, Ives EJ. Juvenile hereditary retinoschisis. *Trans Ophthalmol Soc UK* 1969; 89: 29-39.
- 4 Green JL, Jampol LM. Vascular opacification and leakage in X-linked (juvenile) retinoschisis. *Br J Ophthalmol* 1979; 63: 368-73.
- 5 Pearson R, Jagger J. Sex linked retinoschisis with optic disc and peripheral retinal neovascularisation. *Br J Ophthalmol* 1989; 73: 311-3.
- 6 de Jong PT, Zrenner E, van Meel GJ, Keunen JEE, van Norren D. Mizuo phenomenon in X-linked retinoschisis. *Arch Ophthalmol* 1991; 109: 1104-8.
- 7 Yanoff M, Rahn EK, Zimmerman LE. Histopathology of juvenile retinoschisis. *Arch Ophthalmol* 1968; 79: 49-53.
- 8 Manschot WA. Pathology of hereditary juvenile retinoschisis. *Arch Ophthalmol* 1972; 88: 131-7.
- 9 Condon GP, Brownstein S, Wang N, Kearns AF, Ewing CC. Congenital hereditary (juvenile X-linked) retinoschisis: histopathologic and ultrastructural findings in three eyes. *Arch Ophthalmol* 1986; 104: 576-83.
- 10 Peachey NS, Fishman GA, Derlacki DJ, Brigell MG. Psychophysical and electroretinographic findings in X-linked juvenile retinoschisis. *Arch Ophthalmol* 1987; 105: 513-6.
- 11 Sieving PA, Bingham EL, Roth MS, Young MR, Boehnke M, Kuo C, et al. Linkage relationship of X-linked juvenile retinoschisis with Xp22.1-p22.3 probes. *Am J Hum Genet* 1990; 47: 616-21.
- 12 Brockhurst R. Photocoagulation in congenital retinoschisis. *Arch Ophthalmol* 1970; 84: 158-65.
- 13 Daniel R, Kanski JJ, Glasspool MG. Retinal detachment in children. *Trans Ophthalmol Soc UK* 1974; 94: 325-34.
- 14 Gieser EP, Falls HF. Hereditary retinoschisis. *Am J Ophthalmol* 1961; 51: 1193-200.
- 15 Greven CM, Moreno RJ, Tasman W. Unusual manifestations of X-linked retinoschisis. *Trans Am Ophthalmol Soc* 1990; 88: 211-28.
- 16 Kawano K, Tanaka K, Murakami F, Ohba N. Congenital hereditary retinoschisis: evolution at initial stage. *Graefes Arch Clin Exp Ophthalmol* 1981; 217: 315-23.
- 17 Marmor MF, Arden GB, Nilsson SE, Zrenner E. Standard for clinical electrophysiology. *Arch Ophthalmol* 1989; 107: 816-9.
- 18 Levy J. Inherited retinal detachment. *Br J Ophthalmol* 1952; 36: 626-36.
- 19 Laatikainen L, Tarkkanen A, Saksela T. Hereditary X-linked retinoschisis and bilateral congenital retinal detachment. *Retina* 1987; 7: 24-7.
- 20 Conway BP, Welch RB. X-chromosomal-linked juvenile retinoschisis with haemorrhagic retinal cyst. *Am J Ophthalmol* 1977; 83: 853-5.
- 21 Regillo CD, Tasman WS, Brown GC. Surgical management of complications associated with X-linked retinoschisis. *Arch Ophthalmol* 1993; 111: 1080-6.
- 22 Arkfeld DF, Brockhurst RJ. Vascularised vitreous membranes in congenital retinoschisis. *Retina* 1987; 7: 20-3.
- 23 Schepens CL. Congenital retinoschisis. *Klin Oczna* 1988; 90: 127-32.
- 24 Turut P, Francois P, Castier P, Milazzo S. Analysis of results in the treatment of peripheral retinoschisis in sex-linked congenital retinoschisis. *Graefes Arch Clin Exp Ophthalmol* 1989; 227: 328-31.
- 25 DiSclafani M, Wagner A, Humphrey W, Valone J. Pigmentary changes in acquired retinoschisis. *Am J Ophthalmol* 1988; 105: 291-3.
- 26 Dobbie JG. Cryotherapy in senile retinoschisis. *Trans Am Acad Ophthalmol Otolaryngol* 1969; 73: 1047-59.
- 27 Pischel DK. Surgical treatment of retinal cysts. *Am J Ophthalmol* 1963; 56: 1-16.
- 28 Flynn JT, O'Grady GE, Herrera J. Retrolental fibroplasia I: Clinical observations. *Arch Ophthalmol* 1977; 95: 217-23.
- 29 Gass JDM. Serous detachment of the macular secondary to congenital pit of the optic nerve head. *Am J Ophthalmol* 1969; 67: 821-41.
- 30 Verdauger J. Juvenile retinal detachment. *Am J Ophthalmol* 1982; 93: 145-56.
- 31 Forsius H, Krause U, Helve J, Vuopala V, Mustonen E, Vainio-Mattila B, et al. Visual acuity in 183 cases of X-chromosomal retinoschisis. *Can J Ophthalmol* 1973; 8: 385-93.
- 32 Basmadjian G, Labelle P, Dumas J. The natural evolution of juvenile retinoschisis. *Can J Ophthalmol* 1973; 8: 33-7.
- 33 Miyake Y, Shiroyama N, Ota I, Horiguchi M. Focal macular electroretinogram in X-linked congenital retinoschisis. *Invest Ophthalmol Vis Sci* 1993; 34: 512-5.