

# Ischaemic retinopathy occurring in patients receiving bone marrow allografts and campath-1G: a clinicopathological study

A R Webster, J R Anderson, E M Richards, A T Moore

## Abstract

**Aims/Background**—Ischaemic retinopathy is a well characterised complication of bone marrow transplantation (BMT). Although the aetiology is unclear, it is most probably multifactorial, and may be related to treatment such as radiation and cyclosporin A. The clinical findings are reported of two patients who developed such a retinopathy and the ocular histology from one of these cases is presented.

**Methods**—Two patients underwent BMT for acute lymphoblastic leukaemia, receiving campath-1G for prophylaxis against graft versus host disease, and showed fundal changes compatible with BMT retinopathy. The eyes from one patient were retrieved at post mortem and examined by both light and electron microscopy.

**Results**—The visual symptoms and fundal signs resolved spontaneously with no specific treatment in one patient. Light and electron microscopic examination of the eyes of the other patient was compatible with an ischaemic aetiology and showed evidence of retinal capillary endothelial loss.

**Conclusions**—(i) Histopathology in one case of BMT retinopathy demonstrates a retinal endotheliopathy similar to that described in radiation retinopathy. (ii) BMT retinopathy may occur in the absence of cyclosporin A treatment. (iii) The retinopathy can recover spontaneously with no specific treatment.

(*Br J Ophthalmol* 1995; 79: 687-691)

patients was campath-1G – a monoclonal antibody of the IgG2b subclass against a specific glycoprotein expressed on mature lymphocytes and monocytes but not expressed on cells of the myeloid series. Its use is both to deplete donor lymphocytes and therefore decrease the chances of GVHD and to ensure the depletion of any surviving recipient lymphocytes so reducing the probability of graft failure. It is used in the management of BMT in many centres.

## Patients and methods

### CASE 1

A 10-year-old boy was found to have acute lymphoblastic leukaemia and remission was induced with a standard regimen of chemotherapy (UKALL11). Included in the initial therapy was a single dose of 1800 cGy cranial irradiation for prophylaxis against CNS disease. After remaining well on maintenance chemotherapy for 2 years all treatment was stopped.

After 2 further years of good health he presented with pyrexia and was found to have relapsed. A standard combination of chemotherapy (the UKALLR1 regimen) was commenced. Four months after relapse, he received a bone marrow allograft from his HLA identical sister. His own marrow was harvested and he was given 1440 cGy of fractionated (180 cGy twice daily  $\times 4$ ) total body irradiation (TBI). Campath-1G was given to the patient and to the donor marrow for prophylaxis against GVHD.

Ten weeks after the allograft, he remained leukopenic indicating that the graft had failed. His own marrow was re-transplanted as an autograft. Although his red and white cell counts returned to normal he remained persistently thrombocytopenic. Also, he was found to have a right sided homonymous hemianopia and to be confused. A cerebrovascular accident was diagnosed, although imaging of the brain was at that time precluded by ill health. The patient complained of blurred vision, and was found to have abnormalities on funduscopy. During this time a *Candida* septicaemia was found and intravenous amphotericin was commenced. An ophthalmic opinion was sought.

Acutities of only counting fingers were obtained although testing was impaired by ill health. A right sided relative homonymous hemianopia was confirmed. The pupils appeared to constrict normally and symmetrically to light. Funduscopy (Fig 1)

Leukaemia can have widespread effects on the eye including direct infiltration of the tissues of the eye by leukaemic cells and the effects of further haematological abnormalities such as anaemia, hyperviscosity, and thrombocytopenia.<sup>1</sup> The treatment of leukaemia includes chemotherapy, irradiation, and bone marrow transplantation (BMT) all of which can adversely affect the eye.<sup>2-4</sup> A specific abnormality has been reported in the literature<sup>5-9</sup> and termed 'bone marrow transplant retinopathy' (BMT retinopathy) which we believe to be exhibited by the cases presented here. Although the pathogenesis remains unknown and is probably multifactorial, cyclosporin A used as prophylaxis against graft versus host disease (GVHD) has been implicated.<sup>6,7</sup> The agent used instead of cyclosporin A in our two

Addenbrooke's  
Hospital, Cambridge

Ophthalmology  
Department  
A R Webster  
A T Moore

Department of  
Haematology  
E M Richards

Department of  
Histopathology  
J R Anderson

Correspondence to:  
Mr A T Moore, Department  
of Ophthalmology, Box No  
41, Addenbrooke's NHS  
Trust, Hills Road,  
Cambridge CB2 2QQ.

Accepted for publication  
2 March 1995

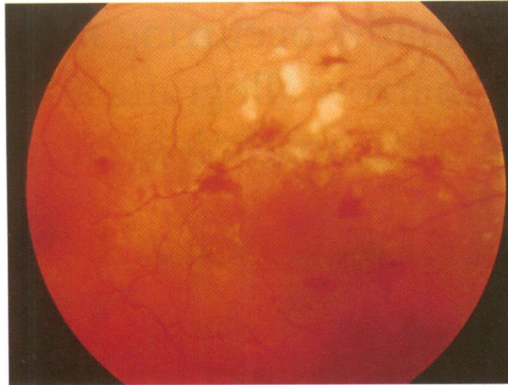


Fig 1A

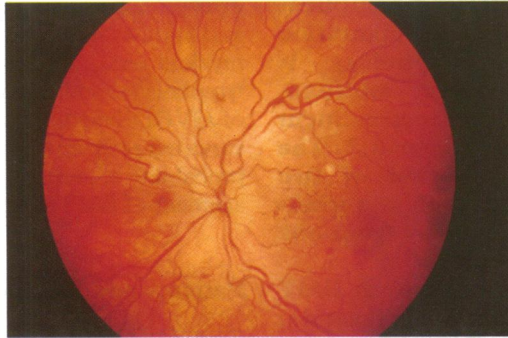


Fig 1B

Figure 1 Case 1. Fundi, right (A) and left (B).

showed bilateral cotton wool spots and retinal haemorrhages particularly at the posterior poles. These areas coincided with areas of capillary non-perfusion on fluorescein angiography (Fig 2). There was late leakage of fluorescein at the ischaemic areas but there was no oedema affecting the foveae. The optic discs were thought to be slightly swollen although there was no disc leakage of fluorescein. The media were entirely clear. A diagnosis of BMT retinopathy was made. No specific treatment was instituted and over a period of 1 month, the vision remained poor and the retinal appearances showed some worsening. Unfortunately the patient remained ill and died in respiratory failure shortly thereafter. Consent was obtained for a limited post mortem in which both eyes were taken for examination.

The eyes were taken shortly after death. One eye was placed in neutral buffered formalin for light microscopy and the other was incised and placed in glutaraldehyde for electron microscopy.

#### CASE 2

A 19-year-old female was diagnosed as having acute lymphoblastic leukaemia and while in complete remission started on standard induction chemotherapy. Four months after presentation she received a bone marrow allograft from her HLA identical brother. The patient's own bone marrow was harvested and TBI of a single dose of 950 cGy was given with an additional 1000 cGy 'cranial boost' (5×200 cGy fractions) to the brain and spinal cord. Campath-1G was given to the patient and the donor marrow as prophylaxis against GVHD. After 4 weeks, she remained leukopenic and it

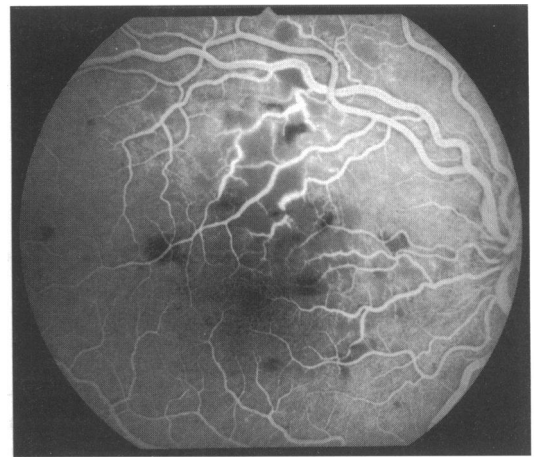


Fig 2A

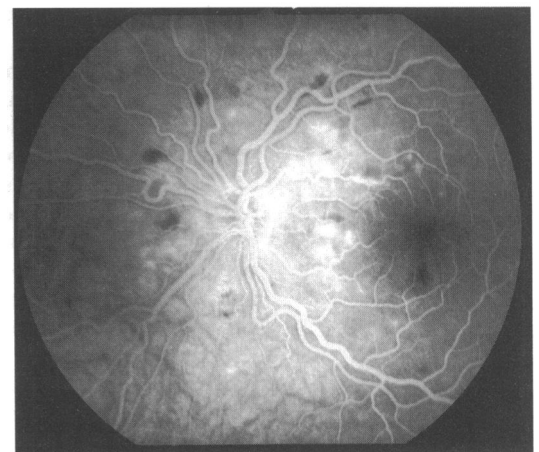


Fig 2B

Figure 2 Case 1. Fluorescein angiograms, right (A) and left (B).

became clear that the allograft had failed. Subsequent autografting was successful and her full blood count returned to normal. Four months after the allograft the patient complained of blurred vision in both eyes and of a rash affecting the left side of the face. An ophthalmic opinion was sought.

Examination revealed a typical herpes zoster rash affecting the left ophthalmic and maxillary divisions. There was no involvement of the left anterior segment. The best corrected acuities were 6/9 bilaterally. The media were clear. Both fundi showed retinal haemorrhages and cotton wool spots around the posterior poles (Fig 3). Fluorescein angiography revealed areas of capillary non-perfusion corresponding to the areas of cotton wool spots (Fig 4). There was late leakage of fluorescein in these areas.

The patient remained generally well on no systemic treatment. The visual symptoms and facial rash improved completely and when re-examined 6 months later her acuities were 6/5 bilaterally and the retinopathy had markedly regressed with only a few scattered retinal haemorrhages remaining.

One year after the bone marrow allograft she became unwell and was found to have relapsed. She died 1 month later.

#### Pathology

Light microscopy revealed infarction of the innermost layers of the retina (Fig 5). The



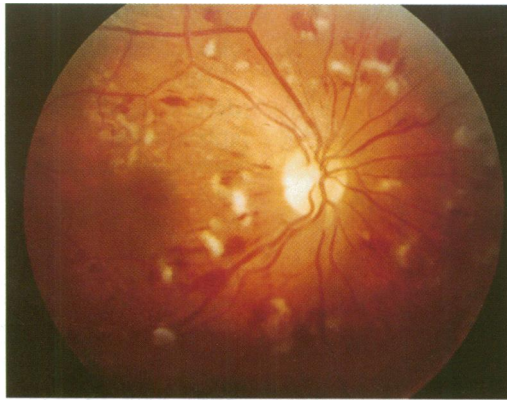


Fig 3A

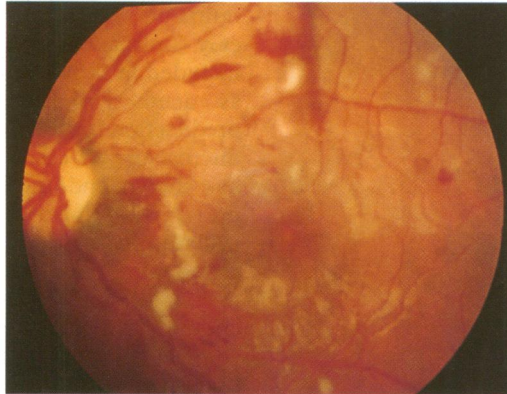

Fig 3B

Figure 3 Case 2. Fundi, right (A) and left (B).

infarcts showed an oedematous nerve fibre layer containing foci of cytooid bodies (Fig 6). Ischaemic ganglion cells and neurons of the inner plexiform layer were shrunken and eosinophilic. The innermost layers of the retina contained small haemorrhages but no capillary abnormalities. The outer layers of the neurosensory retina, the retinal pigment epithelium, and the choroid appeared normal. There was no evidence of any organisms or malignant cells and there was a notable absence of any inflammatory cell infiltration.

Electron microscopy confirmed the cytooid bodies as axonal swellings filled with degenerate organelles. The lumen of adjacent capillaries contained clumped erythrocytes and these vessels showed loss of endothelial cells with relative preservation of the pericytes (Fig 7).

### Discussion

The eye can be adversely affected in leukaemic patients owing to both haematological abnormalities<sup>1</sup> and also the side effects of treatment.<sup>2-4</sup> As the causes of cotton wool spots are numerous<sup>10</sup> the differential diagnosis of an ischaemic retinopathy occurring in such cases remains wide. Although case 2 presented with a herpes zoster rash, the fundal appearances and fluorescein angiogram were unlike those of a viral retinitis. In case 1, systemic *Candida* infection was noted although the ophthalmic signs were not consistent with a *Candida* uveitis, and the histology excluded an infective retinitis.

Cotton wool spots occurring in BMT recipients were first described by Gratwohl *et al*<sup>5</sup>

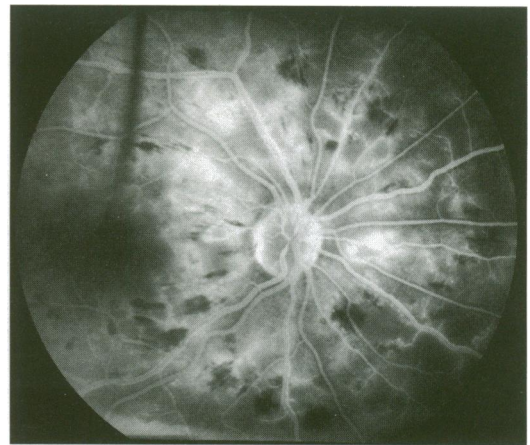


Figure 4 Case 2. Fluorescein angiogram, right eye only.

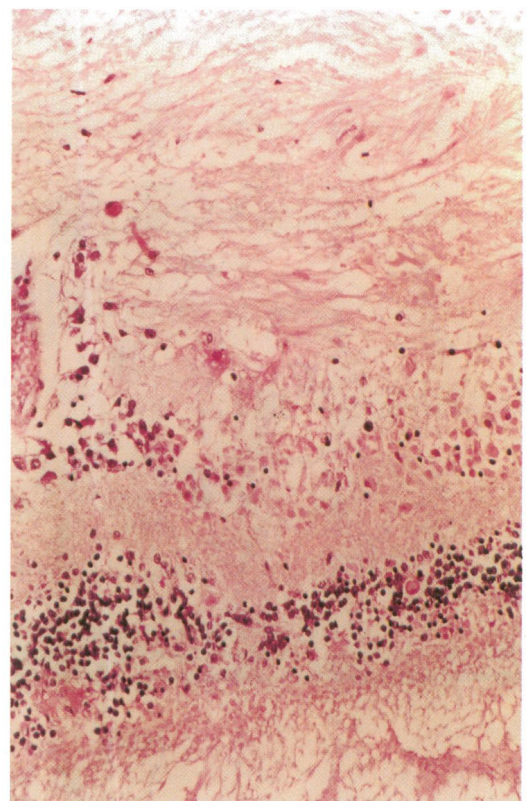


Figure 5 Case 1. Retinal microinfarct showing an oedematous nerve fibre layer and eosinophilic ischaemic neurons in the ganglion cell and inner plexiform layers (haematoxylin and eosin).

and Gloor *et al*.<sup>6</sup> Subsequent to this, Bernauer *et al* published the results of a large prospective study<sup>7</sup> in which 13 of 127 patients developed an ischaemic retinopathy within 6 months of BMT. The retinopathy significantly was only seen in patients receiving both TBI (for malignancies) and cyclosporin A (following allograft), suggesting that both these agents were necessary to develop retinal lesions. Other studies have also reported an ischaemic retinopathy<sup>8,9</sup> and optic disc swelling<sup>11</sup> after BMT although the relation with cyclosporin A and radiation is less clear.<sup>9</sup>

The ocular involvement of acute GVHD is usually confined to the anterior segment and an ischaemic retinopathy is not thought to be a recognised feature.<sup>4,12</sup> A recent series, however, did cite chronic GVHD as a risk factor for the development of cotton wool spots.<sup>9</sup> These patients showed no systemic or other ocular



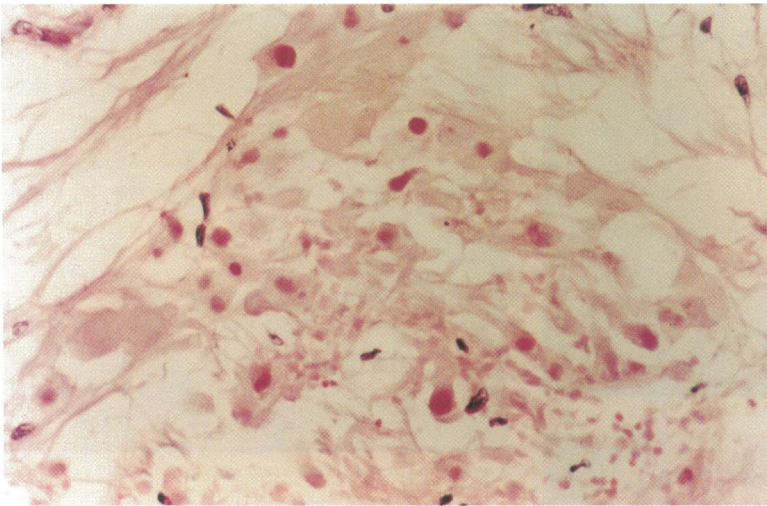


Fig 6A

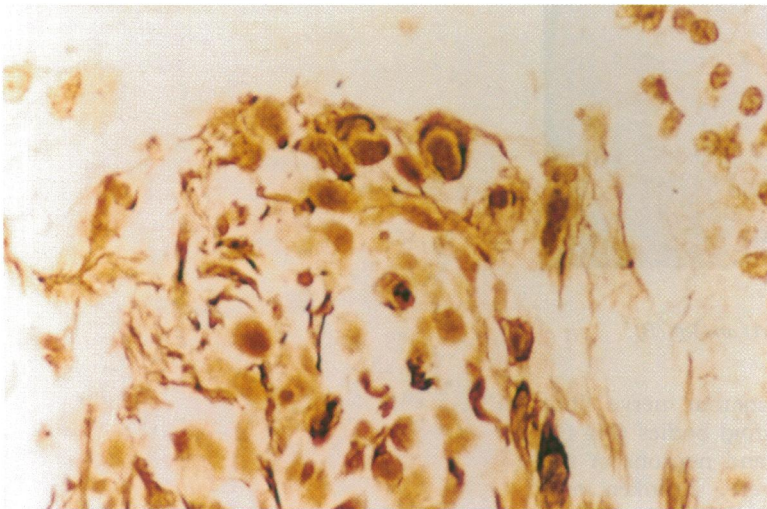


Fig 6B

Figure 6 (A) Case 1. Cytooid bodies in an oedematous nerve fibre layer (haematoxylin and eosin). (B) Case 1. Cytooid bodies showing the 'pseudonuclei' formed by aggregates of degenerating organelles in the axonal swelling. (Palmgren's silver stain for axons.)

signs of GVHD, which was anyway unlikely in view of the allograft failure.

Radiation retinopathy, a phenomenon first described by Stallard in 1933, has a clinical appearance that includes telangiectasia, retinal haemorrhages, cotton wool spots, macular oedema, and neovascularisation.<sup>10-13</sup> The retinopathy rarely develops earlier than 6 months after irradiation, the latent period usually being a number of years and the total dose rarely below 3500 cGy.<sup>14</sup> Each of our patients received TBI in an attempt to deplete the host of all leukaemic cells before BMT. They both developed a retinopathy within 6 months of receiving TBI, the total doses to the retina being 3240 cGy (fractionated) and 2950 cGy (unfractionated). The eye was necessarily included in the field of irradiation in each case as acute lymphoblastic leukaemia has a predilection for the CNS and the eye. Electron microscopy in cases of radiation retinopathy has shown endothelial cell loss with relative preservation of pericytes.<sup>13</sup> This finding is also evident in case 1 suggesting that BMT retinopathy may share a similar pathogenesis with radiation retinopathy involving initial endothelial cell loss. However, the rapid onset, atypical appearance, and lower doses of radiation suggest that other causative factors may also be implicated in the retinopathy in our patients.

The characteristics and applications of the campath-1 antibodies, which were used in the conditioning of our cases before BMT, have been described.<sup>15</sup> It is unlikely that the campath agent itself causes immune complex formation and subsequent retinopathy as there are no soluble blood borne campath antigens. The antibody has been found to be unreactive to some other human tissues in vitro and in vivo although the authors are unaware of any

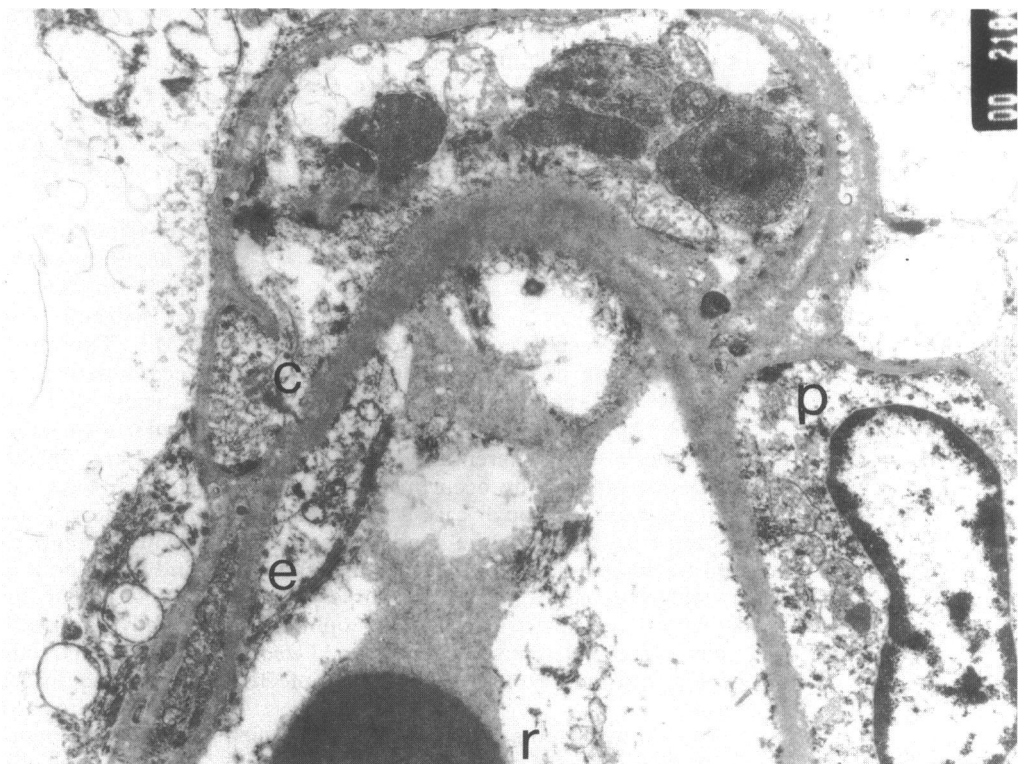


Figure 7 Case 1. Retinal capillary showing swollen degenerate endothelial cells devoid of nuclei and relative preservation of pericytes. (Electron micrograph, magnification  $\times 3645$ .) c, capillary basement membrane; e, endothelial cell; p, pericyte; r, red blood cell.

specific work on campath antibody and the retina.

We feel that it is likely that the retinopathy in these patients is similar to that previously labelled as BMT retinopathy. The pathogenesis of this entity remains enigmatic. Cyclosporin A itself does not appear to cause retinopathy.<sup>16</sup> Radiation itself is unlikely to be the sole cause, although clinically and pathologically the two retinopathies share some similarities. Both cyclosporin A and campath-1G are designed to inhibit the function of T cells. It is interesting to propose that normal T cell function may be necessary for the protection of retinal endothelial cells from such insults as irradiation which may lower the threshold for subsequent endothelial loss and retinal ischaemia. Similarly, perhaps, abnormal T cell function may also be implicated in the development of the morphologically similar entity of HIV retinopathy which, despite investigation, has an unexplained aetiology and whose histology has similarities to the cases presented here.<sup>17</sup>

- 1 Rosenthal AR. Ocular manifestations of leukemia - a review. *Ophthalmology* 1983; **90**: 899-905.
- 2 Imperia PS, Lazarus HM, Lass JH. Ocular complications of systemic cancer chemotherapy. *Surv Ophthalmol* 1989; **34**: 209-30.
- 3 Brown GC, Shields JA, Sanborn G, Augsburger JJ, Savino PJ, Schatz NJ. Radiation retinopathy. *Ophthalmology* 1982; **89**: 1494-501.

- 4 Hirst LW, Jabs DA, Tuschka PJ, Green WR, Santos GW. The eye in bone marrow transplantation - I Clinical study, II Histopathology. *Arch Ophthalmol* 1983; **101**: 580-90.
- 5 Gratwohl A, Gloor B, Hahn H, Speck B. Retinal cotton-wool patches in bone-marrow-transplant recipients. *N Engl J Med* 1983; **308**: 1101.
- 6 Gloor B, Gratwohl A, Hahn H, Kretzschmar S, Robert Y, Speck B, et al. Multiple cotton wool spots following bone marrow transplantation for treatment of acute lymphatic leukaemia. *Br J Ophthalmol* 1985; **69**: 320-5.
- 7 Bernauer W, Gratwohl A, Keller A, Daicker B. Microvasculopathy in the ocular fundus after bone marrow transplantation. *Ann Intern Med* 1991; **115**: 925-30.
- 8 Lopez PF, Sternberg P, Dabbs CK, Vogler WR, Crocker I, Kalin NS. Bone marrow transplant retinopathy. *Am J Ophthalmol* 1991; **112**: 635-46.
- 9 Coskucan NM, Jabs DA, Dunn JP, Haller JA, Green WR, Vogelsang GB, et al. The eye in bone marrow transplantation. IV Retinal complications. *Arch Ophthalmol* 1994; **112**: 372-9.
- 10 Brown GC, Brown MM, Hiller T, Fischer D, Benson WE, Magargal LE. Cotton-wool spots. *Retina* 1985; **5**: 206-14.
- 11 Avery R, Jabs DA, Wingard JR, Vogelsang G, Saral R, Santos G. Optic disc edema after bone marrow transplantation - possible role of cyclosporine toxicity. *Ophthalmology* 1991; **98**: 1294-301.
- 12 Livesey SJ, Holmes JA, Whittaker JA. Ocular complications of bone marrow transplantation. *Eye* 1989; **3**: 271-6.
- 13 Archer DB. Doyne Lecture. Responses of retinal and choroidal vessels to ionising radiation. *Eye* 1993; **7**: 1-13.
- 14 Amoaku WMK, Archer DB. Cephalic radiation and retinal vasculopathy. *Eye* 1990; **4**: 195-203.
- 15 Willemze R, Richel DJ, Falkenburg JH, Hale G, Waldmann H, Zwaan FE, et al. In vivo use of Campath-1G to prevent graft-versus-host disease and graft rejection after bone marrow transplantation. *Bone Marrow Transplant* 1992; **9**: 255-61.
- 16 Oechslin M, Thiel G, Landmann J, Gloor B. Cotton-wool exudates not observed in recipients of renal transplants treated with cyclosporine. *Transplantation* 1986; **41**: 60-2.
- 17 Pepose JS, Holland GN, Nestor MS, Cochran AJ, Foos RY. Acquired immune deficiency syndrome. Pathogenic mechanisms of ocular disease. *Ophthalmology* 1985; **92**: 472-84.