

Sodium hyaluronate eyedrops in the treatment of dry eyes

Shigeto Shimmura, Masafumi Ono, Kazumi Shinozaki, Ikuko Toda, Etsuko Takamura, Yukihiko Mashima, Kazuo Tsubota

Abstract

Background—Several studies in the past have attempted to demonstrate the efficacy of sodium hyaluronate in the treatment of dry eyes. However, results have been conflicting and a definite conclusion has not yet been reached. This study recruited a larger group of patients and has incorporated for the first time both fluorescein and rose bengal staining in the evaluation of the epithelium.

Methods—Eighteen albino rabbit corneas were used in a basic animal study to demonstrate the efficacy of sodium hyaluronate by comparing the effects on the rate of epithelial healing. The optimal concentration to be used in the clinical trial was determined from the results of the basic study. In the clinical study 104 patients with dry eye syndrome were enrolled in a double masked controlled clinical trial. Patients received sodium hyaluronate drops in one eye and control medication in the other eye for 4 weeks. Grading of subjective symptoms and clinical examinations were performed at 2 and 4 weeks.

Results—In the animal study sodium hyaluronate at concentrations of 0.1% and 0.5% significantly accelerated the recovery time of iodine vapour induced corneal erosions ($p < 0.01$). In the clinical study no statistical significance was observed in the improvement of subjective symptoms or rose bengal staining, while fluorescein scores significantly improved in eyes receiving sodium hyaluronate ($p = 0.0001$) at 4 weeks.

Conclusion—Sodium hyaluronate drops applied in six daily doses could not be demonstrated to offer advantages over conventional tear supplies in the improvement of subjective symptoms, but may play a role in maintaining a healthy corneal epithelium.

(*Br J Ophthalmol* 1995; 79: 1007-1011)

showed no significant advantage compared with chondroitin sulphate or polyvinyl alcohol, while Sand⁶ concluded that sodium hyaluronate was effective in another double masked trial. This discrepancy may be due to factors such as differences in severity of dry eyes, variation of examination techniques, or frequency of application. The relatively small number of patients enrolled (20 to 30 cases in each study) may have contributed to statistical variation. However, certain properties of sodium hyaluronate such as long ocular surface residence time⁷ and increased tear evaporation from the ocular surface following application⁸ make sodium hyaluronate a promising agent that merits a more extensive study.

In order to provide additional evidence for the effectiveness of sodium hyaluronate, we first conducted an in vivo study using rabbits to demonstrate the effects of sodium hyaluronate on experimentally induced corneal epithelial lesions, followed by a multicentred, controlled double masked clinical trial of sodium hyaluronate in the treatment of keratoconjunctival lesions in dry eyes. We adopted a study design in which sodium hyaluronate and placebo were applied concurrently in different eyes of the same patient in order to minimise differences in study conditions. This minimises temporal factors that come into play when comparing eyedrops applied during different time periods.

This study focused primarily on fluorescein staining as well as rose bengal staining. Both fluorescein and rose bengal are of the hydroxy-xanthene dye family, with rose bengal having extra halide derivatives within the molecule accounting for its larger molecular weight and shift in spectroscopic absorption wavelength. Feenstra and Tseng⁹ reviewed how fluorescein and rose bengal have slightly different staining properties. Although the consensus is that rose bengal stains non-viable cells and mucous strands, it has been demonstrated to stain viable cells in vitro but, in vivo, is blocked by tear component proteins and polymers such as carboxymethylcellulose. On the other hand, fluorescein lacks this ability to be blocked by tear constituents, and diffuses rapidly into the stroma where cell to cell junctions are disrupted. The clinical implications of each dye, as summarised by Feenstra and Tseng, are that fluorescein staining is promoted by disruption of cell-cell junctions, and rose bengal staining is due to insufficient protection of the precorneal tear film, both in terms of decreased tear components and abnormal surface epithelial cells. The different staining properties of each

Department of
Ophthalmology, Keio
University School of
Medicine, Tokyo,
Japan
S Shimmura
Y Mashima

Department of
Ophthalmology,
Minami-Tama
Hospital, Tokyo, Japan
M Ono

Department of
Ophthalmology, Tokyo
Women's Medical
College, Tokyo, Japan
K Shinozaki
E Takamura

Department of
Ophthalmology, Tokyo
Dental College, Chiba,
Japan
I Toda
K Tsubota

Correspondence to:
Shigeto Shimmura, MD,
Department of
Ophthalmology, Keio
University School of
Medicine, Shinanomachi 35,
Shinjuku, Tokyo, Japan.

Accepted for publication
18 July 1995

Sodium hyaluronate is a glycosaminoglycan found in significant amounts in synovial fluid and the vitreous humour. Owing to the large number of negative charges on the molecule, sodium hyaluronate is capable of holding large quantities of water, and thus lubricating surrounding structures. Previous studies have evaluated the efficacy of sodium hyaluronate as a tear replacement in the treatment of dry eyes with varying results.¹⁻⁶ Controlled double masked studies by Limberg⁴ and Nelson⁵

dye may prove effective in differentiating the pathological condition of the corneal epithelium. Micropipettes were used to apply fluorescein and rose bengal in order to standardise the amount of applied dye as much as possible.

Material and methods

BASIC STUDY

Eighteen corneas of nine male albino rabbits weighing 2 to 3 kg were used in the study. Test medication consisted of 0.1% and 0.5% sodium hyaluronate, while the vehicle of the solution (phosphate buffer, pH 7.35) served as a control. Corneas were divided into four groups: two groups receiving sodium hyaluronate in concentrations mentioned above (n=4 and 5 respectively), one group receiving the vehicle (n=4) serving as control, and one untreated group (n=5).

Corneal erosions were made according to Parkinson and Schuchard¹⁰ using iodine vapour. In brief, rabbits were put under general anaesthesia by pentobarbitone followed by topical administration of oxybuprocaine. A 7 mm glass tube with a glass wool plug containing iodine crystals was gently applied to the central cornea for 3.5 minutes. Round corneal erosions appeared approximately 4 hours after exposure to iodine vapour.

Corneas were stained with fluorescein, and the area of epithelial erosions was quantitatively calculated using a digitiser (Cosmozone 1S, Nikon Inc, Tokyo, Japan). After initial evaluation at 4 hours, 50 µl of 0.1%, 0.5% sodium hyaluronate, and control were applied four times daily at 2 hour intervals for 2 days. Evaluation of the wounded cornea was done at 22, 28, and 34 hours. Statistical analysis was performed by the one way ANOVA and Duncan's tests.

CLINICAL STUDY

The clinical study was conducted at eight major medical centres by 18 dry eye specialists during a period of 9 months between September 1991 to May 1992. A total of 104 patients with dry eye syndrome (including Sjögren's syndrome) were enrolled. Dry eye was diagnosed according to Toda *et al.*¹¹ In brief, patients with (1) dry eye related symptoms, (2) positive staining with either fluorescein or rose bengal, and (3) tear break up time less than 5 seconds or a Schirmer test value of less than 5 mm were diagnosed as having dry eyes. Sjögren's syndrome was diagnosed according to the criteria proposed by Fox *et al.*¹² where patients positive in three or more of the following four criteria were diagnosed as having Sjögren's syndrome: (1) dry eye, (2) xerostomia, (3) lymphocytic infiltrates on minor salivary gland biopsy, and (4) serological evidence (positive rheumatoid factor or positive antinuclear antibody or positive SS-A or SS-B antibody). The criteria for dry eye in this case are somewhat different from the original criteria for keratoconjunctivitis sicca (KCS) proposed by Fox *et al* on two points: (1) the presence of symptoms is not

questioned in the original paper, and (2) patients with Schirmer values in the normal range, but with tear break up times of less than 5 seconds were included.

All patients gave their informed consent before enlisting in the study. In addition to the diagnosis of dry eye, patients eligible for the study were required to have a rose bengal score of greater than 3 (on a scale of 0 to 21). This was to exclude very mild cases where statistical comparisons of staining scores would not be possible. Patients with infectious extraocular disease, corneal epithelial disorders associated with diabetes mellitus, and neurotrophic keratitis were excluded from the study. Patients with overt asymmetrical staining patterns at the time of initial examination were also excluded.

The test medication used was a preservative-free 0.1% sodium hyaluronate solution (1×10⁶ Da) bottled in a single dose disposable container. The vehicle for the solution, consisting of the same agents as the test solution excluding sodium hyaluronate (25 mM phosphate buffered saline, pH 7.36), was used as control. Identical disposable containers were used so that discrimination between solutions was difficult.

The study was conducted in a double blind, controlled fashion in which each patient received the sodium hyaluronate eyedrops in one eye, and the vehicle in the other. The eye to receive sodium hyaluronate in each patient was randomly selected by a designated study controller.

Before participating in the study, patients were required to 'wash out' their eyes for 2 weeks with a conventional preservative-free artificial tear solution (Soft Santear, an isotonic NaCl, KCl solution with 1% boric acid, pH 7.0–8.0, Santen Pharmaceuticals, Osaka Japan), applied six times a day. After this 2 week period, patients were examined and interviewed to grade subjective symptoms such as foreign body sensation, pain, burning, and itching on a scale of 0 to 5 (see Table 1 for list of symptoms). Fluorescein and rose bengal staining, as well as tear break up time were observed according to Toda and Tsubota¹³ by instilling 2 µl of a 1% fluorescein–1% rose bengal solution by micropipette (Fig 1). Micropipettes were used in order to obtain

Table 1 Improvement in symptoms (SD) in 91 patients after 4 weeks

	0.1% Sodium hyaluronate	Control
Asthenopia	-0.55 (0.90)	-0.46 (0.89)
Dry eye sensation	-0.69 (1.04)	-0.65 (1.16)
Foreign body sensation	-0.67 (1.10)	-0.56 (1.07)
Pain	-0.40 (1.00)	-0.41 (1.10)
Blurred vision	-0.43 (0.80)*	-0.30 (0.84)
Photophobia	-0.34 (0.82)	-0.31 (0.85)
Redness	-0.43 (0.99)	-0.52 (1.02)
Discharge	-0.24 (0.81)	-0.14 (0.80)
Heavy lids	-0.40 (1.06)	-0.35 (0.98)
General discomfort	-0.59 (1.14)	-0.46 (1.10)
Difficulty in awakening	-0.14 (0.85)	-0.13 (0.79)
Epiphora	-0.10 (0.62)	-0.07 (0.44)
Itchy sensation	-0.04 (0.82)	+0.01 (0.81)
Hot sensation	-0.08 (0.97)	-0.03 (0.90)

Minus sign indicates decrease (improvement) in grading score. *p=0.0627 (Wilcoxon's signed rank test), p>0.1 for all other examinations.

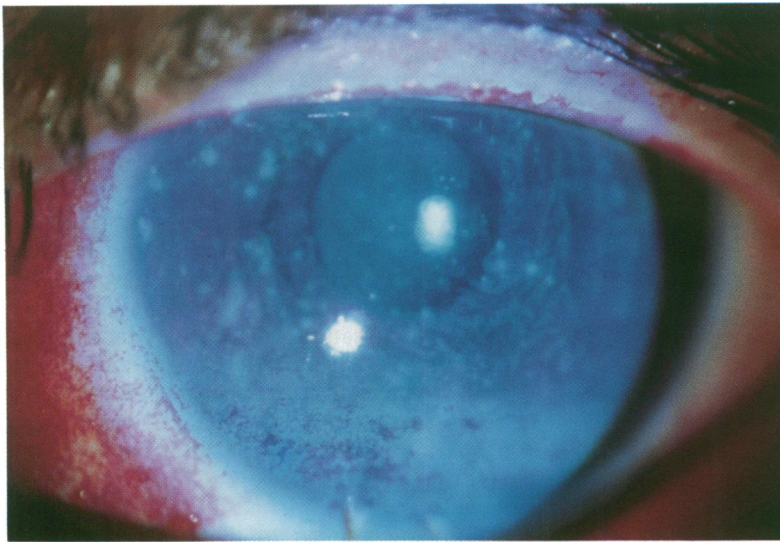


Figure 1 Slit-lamp photograph following application of 2 µl of 1% fluorescein—1% rose bengal solution by micropipette.

consistent volumes and concentrations of dye so that staining scores were not influenced by the staining habits of different physicians. Staining was graded on a scale of 0 to 3 for each section of cornea and conjunctiva as in Figure 2, followed by a photograph and/or detailed sketch. Corneal debris, meibomitis, conjunctivitis, and conjunctival injection were graded on a scale of 0 to 4. Schirmer test and tear clearance were observed simultaneously according to Ono *et al.*,¹⁴ 5 minutes after instilling 10 µl of a 0.5% fluorescein—0.1% oxybuprocaine solution by micropipette. Tear clearance was evaluated by the colour of the Schirmer strip stained by residual fluorescein in the conjunctival sac. Schirmer strips stained with known concentrations of fluorescein were compared with the Schirmer strip of the patient to determine qualitatively the amount of fluorescein remaining after 5 minutes. The Schirmer test with nasal stimulation¹⁵ was performed on selected patients. Following preliminary examinations, patients were supplied with two sets of eyedrops in single use disposable containers with labels indicating the eye to be treated. Neither the patient nor the physician knew of the contents. Information concerning which eye to receive sodium hyaluronate and which eye to receive control in

each patient was sealed in an envelope, kept under guard by the study controller, and left unopened until the study was over. Patients were asked to use the designated eyedrops in each eye six times daily at 3 hour intervals for 4 weeks. Patients were equipped with digital wrist watches with preset alarms indicating time of eyedrop application. Compliance was determined by counting the number of empty containers collected upon each visit. Grading of subjective symptoms and objective findings was repeated at 2 weeks and at the end of the study.

Wilcoxon's signed rank test was used to analyse differences in efficacy between each test medication. Analysis was done in the entire group as a whole, and in subgroups of patients with the Sjögren's syndrome and patients with non-Sjögren dry eye.¹⁶

Results

BASIC STUDY

Each group demonstrated a linear reduction in erosion size as shown in Figure 3. The time required for 50% recovery in erosion size was significantly shorter in groups receiving 0.1% and 0.5% sodium hyaluronate (18 hours) compared with the untreated group, or the group receiving vehicle alone (30 hours). The accelerating effect of sodium hyaluronate was observed up to 22 hours after erosion of the epithelium. Between 22 hours and 34 hours, the healing rates in each group were similar, but wound area was significantly smaller in both concentrations of sodium hyaluronate compared with control and the untreated group. No significant difference was observed between 0.1% and 0.5% sodium hyaluronate in both healing rate and wound area, and therefore 0.1% was chosen as the final concentration to be used in the clinical trial.

CLINICAL STUDY

Of the 104 patients enrolled in the study, 91 patients successfully completed the trial and were eligible for statistical analysis. Among the 13 dropout patients, two patients developed signs of allergic conjunctivitis, one discontinued treatment because of exacerbation of symptoms, and the remainder were disqualified because of non-compliance of dose or period not related to symptoms or side effects. Non-compliance was mainly the result of a lack of understanding of the protocol such as omitting to apply drops, or failure to visit clinics on the appointed dates. Compliance of dose was confirmed by counting the number of empty and untouched containers collected at each visit.

No statistically significant difference was observed between any of the subjective symptoms under study in terms of improvement in grading scores (Table 1). There was a trend towards improvement in blurring of vision in eyes receiving sodium hyaluronate ($p=0.063$). The absolute score value for foreign body sensation at 4 weeks was less in sodium

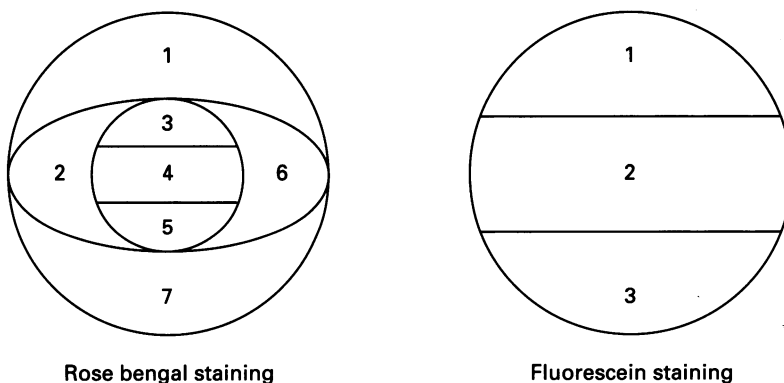


Figure 2 Anterior segment sectioning for staining scores. Each compartment was graded on a scale of 0 (no staining) to 3 (intense staining). Rose bengal: (1) superior palpebral conjunctiva, (2) and (6) nasal and temporal bulbar conjunctiva, (3) superior cornea, (4) mid cornea, (5) inferior cornea, (7) inferior palpebral conjunctiva. Fluorescein: (1) superior cornea, (2) mid cornea, (3) inferior cornea.

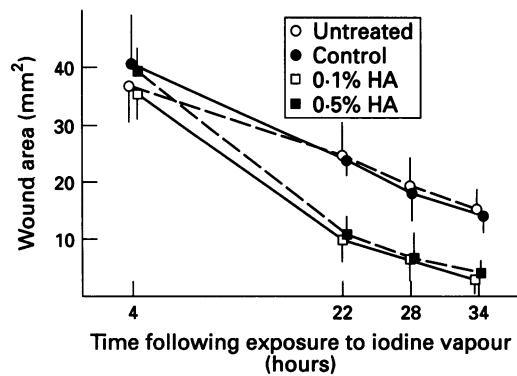


Figure 3 Wound size (mean (SD)) following application of sodium hyaluronate drops and control. Wound size improved significantly earlier in groups receiving 0.1% and 0.5% sodium hyaluronate. No significant difference was observed between each concentration of sodium hyaluronate. HA=sodium hyaluronate.

hyaluronate treated eyes in the Sjögren group (1.67 (SD 0.20) versus 1.97 (SD 0.21)) and the entire group (1.20 (SD 0.12) versus 1.36 (SD 0.13)) with statistical significance; however, when comparing improvement (difference in score before and after treatment) the difference was not significant. Neither of the test medications was overwhelmingly preferred over the other in a questionnaire completed by participants at the end of the study.

Fluorescein staining scores significantly decreased in eyes receiving sodium hyaluronate (average decrease 1.46 (SD 2.08)) compared with eyes receiving control at 4 weeks (average decrease 0.54 (SD 1.89)) ($p=0.0001$). No statistically significant difference was observed in rose bengal staining, tear break up time, Schirmer scores, or tear clearance. Similar results were obtained in both the Sjögren group and the non-Sjögren dry eye group when analysed separately (Table 2).

Discussion

Although previous studies have demonstrated greater subjective improvements in eyes receiving sodium hyaluronate drops, our study failed to demonstrate any significant difference compared with the control except for a trend in improvement in blurred vision and foreign body sensation. The grading scores for symptoms improved in both eyes in the majority of cases. This may be due to the therapeutic effects of the placebo vehicle itself, as well as the difficulty patients may have experienced in grading symptoms in each eye separately. In other words, symptomatic relief or deterioration in one eye invariably affected judgment of symptoms in the other eye. The use of a five point scale for symptoms as well as the long list

of relatively non-specific symptoms under study may have been an excess burden for the patients, which may have affected their concentration and keenness. The trends observed in the study suggest that a more extensive study focusing on fewer symptoms may be worthwhile.

To our surprise, fluorescein staining scores significantly improved in eyes receiving sodium hyaluronate drops, while no significant difference was observed in rose bengal scores. Based on the observations made by Feenstra and Tseng⁹ as reviewed in the introduction to this paper, the lack of improvement in rose bengal scores suggests that sodium hyaluronate drops in quantities used in the study (six drops per day) may not be sufficient to stabilise the precorneal tear film. The half life of 0.2% sodium hyaluronate applied to the ocular surface is reported to be approximately 321 seconds,⁷ and thus a more frequent dose may be more effective. However, the improvement in fluorescein scores indicates that sodium hyaluronate may improve cell to cell adhesions between corneal epithelial cells, since fluorescein staining is exaggerated by rapid diffusion into the stroma through disruptions in cell to cell junctions.⁹

Pflugfelder *et al*¹⁷ have suggested the possibility that squamous metaplasia of the conjunctiva in patients with Sjögren's syndrome may be a primary feature of the disease in addition to tear deficiency. The fact that sodium hyaluronate in six daily doses improved fluorescein scores in the Sjögren group may be a promising sign that sodium hyaluronate can be used to treat conditions caused by factors other than desiccation.

Results of the preliminary study on rabbits also confirmed that sodium hyaluronate drops have an accelerating effect on epithelial wound healing *in vivo*. The mechanism by which sodium hyaluronate enhances epithelial wound healing has not yet been clarified. Fibronectin is known to promote epithelial wound healing by chemotactic and haptotactic effects on epithelial cells.¹⁸⁻²⁰ Inoue and Katakami²¹ reported that sodium hyaluronate promotes cell proliferation, which may contribute to the wound healing effects of sodium hyaluronate. Nishida *et al*²² have demonstrated that sodium hyaluronate stimulates corneal epithelial migration in rabbit organ cultures, which was not affected by the addition of antisera against fibronectin or epithelial growth factor. The effects of sodium hyaluronate on the epithelium may be caused by different factors from those of fibronectin and epithelial growth factor. The possible existence of sodium hyaluronate binding sites in the epithelium has been suggested.²²

Previous reports have demonstrated improvements in rose bengal staining with the use of sodium hyaluronate drops.^{2 5 6} This discrepancy with our results may be due to differences in scoring methods, the manner in which dyes were applied, or the number of patients involved. Certain limitations in our study design can also be pointed out. Different climatic conditions among the eight centres may have contributed to variability. Although

Table 2 Improvement in staining score (SD) after 4 weeks

	No of patients	Stain	0.1% HA	Control	p Value
Total	91	Rose bengal	-1.27 (1.84)	-1.19 (2.09)	0.8955
		Fluorescein	-1.46 (2.08)	-0.54 (1.89)	0.0001
Non-Sjögren's syndrome	55	Rose bengal	-1.36 (1.77)	-1.49 (2.08)	0.6926
		Fluorescein	-1.40 (2.29)	-0.58 (2.08)	0.0049
Sjögren's syndrome	36	Rose bengal	-1.14 (1.97)	-0.72 (2.05)	0.5643
		Fluorescein	-1.56 (1.73)	-0.47 (1.58)	0.0005

HA=sodium hyaluronate. Minus sign indicates decrease in staining score. Statistical analysis by Wilcoxon's signed rank test.

outpatient clinics were all run during the morning, variation in the interval between clinical evaluation and the last drop applied may have affected results. However, the relatively large number of patients (n=104) enrolled in this double blind study, excellent patient compliance, and the use of micropipettes to apply precise amounts of dye have assured maximal standardisation in such a clinical situation.

Sodium hyaluronate drops presented with very few complications. Two patients developed signs of allergic conjunctivitis, and only one patient had to discontinue the trial owing to exacerbation of symptoms. This patient was treated with her original prescription of frequently applied tear supplies to alleviate symptoms.

Sodium hyaluronate drops alone in six daily doses may not adequately improve subjective symptoms associated with dry eye, but may play a role in maintaining a healthy corneal epithelium. Drops applied more frequently, or in conjunction with conventional tear replacements, may offer effective treatment of patients with dry eyes.

- 1 Polack FM, McNiece MT. The treatment of dry eyes with Na hyaluronate (Healon). *Cornea* 1982; 1: 133-6.
- 2 DeLuise VP, Peterson WS. The use of topical Healon tears in the management of refractory dry eye syndrome. *Ann Ophthalmol* 1984; 16: 823-4.
- 3 Mengher LS, Pandher KS, Bron AJ, Davey CC. Effect of sodium hyaluronate (0.1%) on break-up time (NIBUT) in patients with dry eyes. *Br J Ophthalmol* 1986; 70: 442-7.
- 4 Limberg MB, McCaa C, Kissling GE, Kaufman HE. Topical application of hyaluronic acid and chondroitin sulfate in the treatment of dry eyes. *Am J Ophthalmol* 1987; 103: 194-7.
- 5 Nelson JD, Farris RL. Sodium hyaluronate and polyvinyl alcohol artificial tear preparations. *Arch Ophthalmol* 1988; 106: 484-7.
- 6 Sand BB, Marnier K, Norn MS. Sodium hyaluronate in the treatment of keratoconjunctivitis sicca. *Acta Ophthalmol* 1989; 67: 181-3.
- 7 Snibson GR, Greaves JL, Soper NDW, Tiffany JM, Wilson CG, Bron AJ. Ocular surface residence times of artificial tear solutions. *Cornea* 1992; 4: 288-93.
- 8 Tsubota K, Yamada M. Tear evaporation from the ocular surface. *Invest Ophthalmol Vis Sci* 1992; 33: 2942-50.
- 9 Feenstra RPG, Tseng SCG. Comparison of fluorescein and rose bengal staining. *Ophthalmology* 1992; 99: 605-17.
- 10 Parkinson G, Schuchard R. A standard large wound of the corneal epithelium in the rabbit. *Invest Ophthalmol Vis Sci* 1979; 18: 103-6.
- 11 Toda I, Fujishima H, Tsubota K. Ocular fatigue is the major symptom of dry eye. *Acta Ophthalmol* 1993; 71: 347-52.
- 12 Fox R, Robinson C, Curd J, Kozin F, Howell F. Sjogren's syndrome: proposed criteria for classification. *Arthritis Rheum* 1986; 29: 577-83.
- 13 Toda I, Tsubota K. Practical double vital staining for ocular surface evaluation. *Cornea* 1993; 12: 366-8.
- 14 Ono M, Tsubota K, Yoshino K, Yamada M. Tear fluid clearance test. *Jpn J Clin Ophthalmol* 1991; 45: 1143-7.
- 15 Tsubota K. The importance of the Schirmer test with nasal stimulation. *Am J Ophthalmol* 1991; 111: 106-108.
- 16 Tsubota K, Toda I, Yagi Y, Ogawa Y, Ono M, Yoshino K. Three different types of dry eye. *Cornea* 1994; 13: 202-9.
- 17 Pflugfelder SC, Huang AJW, Feuer W, Chuchovski PT, Pereira IC, Tseng SCG. Conjunctival cytologic features of primary Sjogren's syndrome. *Ophthalmology* 1990; 97: 985-91.
- 18 Nishida T, Nakagawa S, Awata T, Ohashi Y, Watanabe K, Manabe R. Fibronectin promotes epithelial migration of cultured rabbit cornea in situ. *J Cell Biol* 1983; 97: 1653-7.
- 19 Nishida T, Nakagawa S, Nishibayashi C, Tanaka H, Manabe R. Fibronectin enhancement of corneal epithelial wound healing of rabbits in vivo. *Arch Ophthalmol* 1984; 102: 455-6.
- 20 Watanabe K, Nakagawa S, Nishida T. Chemotactic and haptotactic activities of fibronectin for cultured rabbit corneal epithelial cells. *Invest Ophthalmol Vis Sci* 1988; 29: 572-7.
- 21 Inoue M, Katakami C. The effect of hyaluronic acid on corneal epithelial cell proliferation. *Invest Ophthalmol Vis Sci* 1993; 34: 2313-5.
- 22 Nishida T, Nakamura M, Mishima H, Otori T. Hyaluronan stimulates corneal epithelial migration. *Exp Eye Res* 1991; 53: 753-8.