

## LETTER TO THE EDITOR

**Indocyanine green angiography in a case of punctate inner choroidopathy**

EDITOR.—The term punctate inner choroidopathy (PIC) was first applied by Watzke *et al*<sup>1</sup> in 1984, although similar lesions had previously been described by Doran and Hamilton.<sup>2</sup> Classically, PIC occurs in moderately myopic young women, and is characterised by the development of unilateral blurred vision, often associated with photopsia. On examination multiple, white-yellow, subretinal lesions are observed concentrated at the posterior pole. Fewer similar lesions are also often seen in the asymptomatic eye. Signs of intraocular inflammation are absent. Visual acuity is only slightly affected unless the lesions are subfoveal or (as in about 30% of cases) subsequent choroidal neovascularisation develops. The aetiology of this condition is as yet unclear.

We report here a patient who appeared to present with features typical of PIC, and who showed unusual, and in our experience unique, abnormalities of the choroidal vasculature as demonstrated by indocyanine green angiography (ICG). To our knowledge this is the first report of ICG findings in this condition.

## CASE REPORT

A 31-year-old woman presented in August 1994 with an 8 week history of reduced central vision in her right eye. She denied any photopsia and had had no recent systemic illness. Her medical history was unremarkable.

Visual acuity was 6/18 unaided in the right eye, improving to 6/12 with a -0.5 spherical correction, and 6/5 unaided in the left eye. She complained of only seeing the top half of the test type letters with the right eye. No cells were present in either the anterior chamber or vitreous. Funduscopy of the right eye showed multiple yellowish subretinal lesions at the level of the inner choroid and retinal pigment epithelium throughout the posterior pole (Fig 1A). The left eye showed three similar lesions (Fig 1B). On fluorescein angiography (FFA) the lesions showed early hyperfluorescence (Fig 1C) with some mild leakage evident in late frames. ICG demonstrated some unusual changes (Fig 1D). In the right eye several areas of obvious hypofluorescence, which corresponded with the site of the visible subretinal lesions were observed; larger choroidal vessels were noted to cross these areas. In addition, several choroidal vessels demonstrated localised points of hyperfluorescence situated close to the vessel wall/border. These changes were noted early and persisted through the study. No such changes were observed in the left eye. Automated field testing using the Humphrey full field 120 point screening program demonstrated three paracentral relative defects in the right eye and was full in the left. There was no evidence of a generalised disorder on electrophysiological testing. A diagnosis of PIC was made and no treatment was recommended.

At the 3 month review, visual acuity in the right eye had decreased to 6/60. Fundal examination showed subretinal fibrosis extending under the fovea with some associated haemorrhage (Fig 2A), consistent with

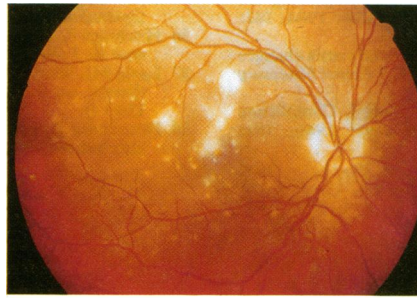


Fig 1A

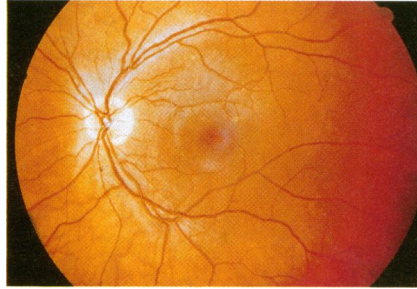


Fig 1B

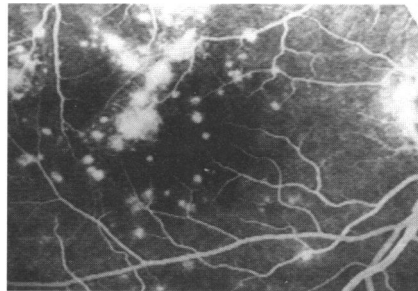


Fig 1C

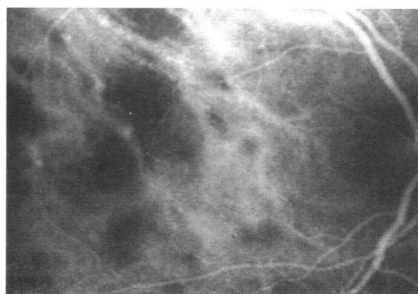


Fig 1D

**Figure 1** (A) Right eye fundal appearance at presentation. Visual acuity 6/18 (6/12 corrected). Note the multiple yellowish-white lesions at the level of the inner choroid and the retinal pigment epithelium. (B) Left eye fundal appearance at presentation showing only three small lesions. Visual acuity 6/5. (C) Right eye at presentation - early phase fluorescein angiogram showing hyperfluorescence of the lesions. (D) Right eye at presentation - early phase indocyanine green (ICG). Note the areas of hypofluorescence and the presence of hyperfluorescent spots on some of the choroidal vessels. This appearance was sustained throughout the ICG study.

choroidal neovascularisation. The remaining lesions visible in the right eye appeared to have developed a more punched out, inactive appearance. The left eye remained asymptomatic with an unaided acuity of 6/5 and an unchanged fundal appearance. Repeat fluorescein angiography confirmed the presence of subretinal neovascularisation but appeared

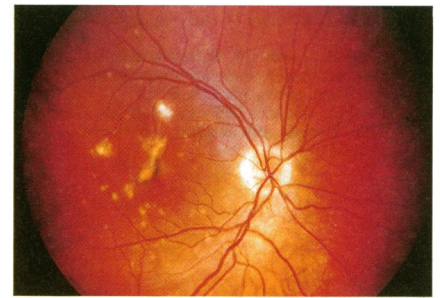


Fig 2A

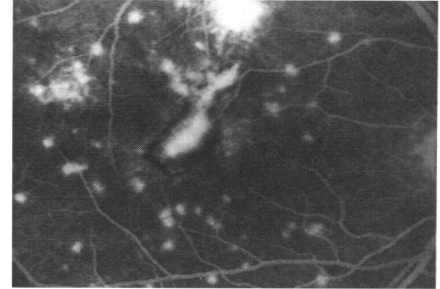


Fig 2B

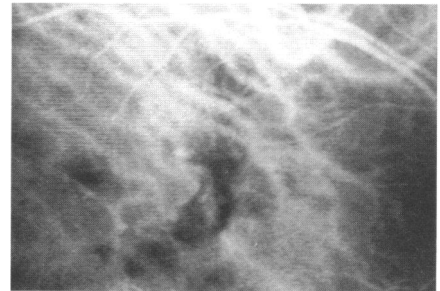


Fig 2C

**Figure 2** (A) Right eye 3 months after presentation. Visual acuity 6/60. Note subretinal fibrosis and associated haemorrhage. (B) Right eye 3 months after presentation - early phase fluorescein angiogram. Note the choroidal neovascularisation and masking due to associated haemorrhage. (C) Right eye 3 months after presentation - indocyanine green angiogram. Note some areas of hypofluorescence and spots of hyperfluorescence persist although less than in Figure 1(D).

otherwise unchanged from previous observations (Fig 2B). ICG showed some resolution of the previously noted abnormalities with fewer areas of hypofluorescence and fewer hyperfluorescent spots (Fig 2C).

When last seen in February 1995 visual acuity and fundal appearances remained unchanged.

## COMMENT

Several disorders with symptomatology and fundal changes similar to those found in PIC have been described. These have been variously termed inflammatory presumed ocular histoplasmosis,<sup>3</sup> multifocal choroiditis and panuveitis,<sup>4</sup> multifocal choroiditis,<sup>5</sup> and recurrent multifocal choroiditis.<sup>6</sup> All of these syndromes have a preponderance in young, myopic women, individual patients differing according to the extent of associated intraocular inflammation. Inflammatory signs were absent in all patients with PIC originally described by Watzke *et al*.<sup>1</sup> Several authors

feel that the cases described in these various series in fact all represent different presentations of a single disease process.<sup>5-7</sup> In addition, widespread retinal dysfunction, as indicated by enlargement of the blind spot and/or abnormal electroretinography, similar to that observed in the multiple evanescent white spot syndrome and acute macular neuroretinopathy, has also been observed in patients with multifocal choroiditis.<sup>7,8</sup> These intriguing observations have led to speculation that all of these conditions may be caused by a single pathogenic agent or group of agents. As yet, however, the aetiology remains obscure, although evidence of recent Epstein-Barr virus infection has been demonstrated in some patients with multifocal choroiditis.<sup>9</sup>

The ICG appearance in this case of PIC was unique in the authors' experience. ICG is highly protein bound (>99%) and therefore stays within the choroidal circulation. The hypofluorescent areas suggest localised choroidal hypoperfusion and the localised points of hyperfluorescence on the vessel walls may indicate an associated choroidal vasculitic element. The presence of larger choroidal

vessels running through the hypofluorescent areas implies that the vasculitis may be confined to smaller choroidal vessels and the choriocapillaris. The hyperfluorescent points on the larger choroidal vessels resembled aneurysmal-like dilatation of the vessel walls and are unlikely to be other choroidal vessels seen in cross section in view of their close proximity. In addition they have not been observed with previous ICG studies in this department. With resolution of the active lesions the areas of hypoperfusion and vascular outpouchings reduced. The mechanism – that is, whether these changes are intrinsic or extrinsic to the choroidal vessels, of these changes and their nature remain unclear.

In summary, we present a typical case of PIC, the ICG appearance of which would appear to demonstrate abnormality of the choroidal vasculature.

P A C TIFFIN  
R MAINI  
S T D ROXBURGH  
A ELLINGFORD  
University of Dundee,  
Department of Ophthalmology,  
Ninewells Hospital and Medical School,  
Dundee DD1 9SY

Accepted for publication 13 September 1995

- 1 Watzke RC, Packer AJ, Benson WE, Burgess D, Ober RR. Punctate inner choroidopathy. *Am J Ophthalmol* 1984; **98**: 572-84.
- 2 Doran RML, Hamilton AM. Disciform macular degeneration in young adults. *Trans Ophthalmol Soc UK* 1982; **102**: 471-80.
- 3 Deutsch TA, Tessler HH. Inflammatory pseudohistoplasmosis. *Ann Ophthalmol* 1985; **17**: 461-5.
- 4 Dreyer FR, Gass JDM. Multifocal choroiditis and panuveitis: a syndrome that mimics ocular histoplasmosis. *Arch Ophthalmol* 1984; **93**: 1776-84.
- 5 Joondeph BC, Tessler HT. Multifocal choroiditis. *Int Ophthalmol Clin* 1990; **30**: 286-90.
- 6 Morgan CM, Schatz H. Recurrent multifocal choroiditis. *Ophthalmology* 1986; **93**: 1138-47.
- 7 Callanan D, Gass JDM. Multifocal choroiditis and choroidal neovascularisation associated with the multiple evanescent white dot and acute idiopathic blind spot enlargement syndrome. *Ophthalmology* 1992; **99**: 1678-85.
- 8 Holz FG, Kim RY, Schwartz D, Harper CA, Wroblewski J, Arden GB, et al. Acute zonal occult outer retinopathy (AZOOR) associated with multifocal choroidopathy. *Eye* 1994; **8**: 77-83.
- 9 Teideman JS. Epstein-Barr virus antibodies in multifocal choroiditis and panuveitis. *Am J Ophthalmol* 1987; **103**: 659-63.