

Ultrastructural features and prevalence of tubuloreticular structures in the ocular vasculature of patients with AIDS: a study of 23 cases

Raj K Maturi, Ramon L Font

Abstract

Background—Tubuloreticular structures (TRS) are subcellular inclusions that are most commonly found in endothelial cells and lymphocytes of patients with auto-immune or collagen vascular disorders. In AIDS, TRS have been described in various tissues throughout the body including the lung, kidney, liver, muscle, and skin.

Methods—Ocular tissues from 23 patients with AIDS were examined by electron microscopy. These included 17 post-mortem eyes in addition to three chorio-retinal and three conjunctival biopsy specimens.

Results—The overall prevalence of TRS in the ocular and conjunctival endothelial cells was found to be 83% (19/23).

Conclusions—This is the first documented study of the prevalence of these structures in the ocular structures of patients with AIDS. Given the high frequency of their occurrence in AIDS, it is recommended that the presence of TRS in ocular or conjunctival tissues be an indication for obtaining an HIV antibody titre. Additionally, a rheumatological examination for HIV seronegative patients is suggested.

(*Br J Ophthalmol* 1996; 80: 252-255)

Tubuloreticular structures (TRS) were first described in association with systemic lupus erythematosus (SLE)¹ but have been found in association with other immunological disorders,²⁻⁴ including AIDS⁵⁻⁹ and, rarely, malignant lymphomas and leukaemias.¹⁰ Ultrastructurally, TRS are composed of multiple branching inclusions located adjacent to the cisternae of the rough surfaced endoplasmic reticulum and, occasionally, within the perinuclear envelope.⁶ On transmission electron microscopy, these inclusions have a diameter of 20-30 nm and are found most commonly as electron dense cytoplasmic aggregates. Cytochemical studies

have determined that TRS consist primarily of membrane phospholipids and glycoprotein.^{2,3}

An extensive review of the tissue location and cell types containing TRS in humans has been reported previously.¹⁰ One case report has described TRS in the endothelial cell of a choroidal vessel.¹¹ One of the authors (RLF) has previously described these structures in a conjunctival biopsy specimen of an HIV seropositive patient.¹²

To our knowledge, no published data on the prevalence of these structures in the ocular tissues of AIDS patients have been recorded. The purpose of this study was to document the prevalence of TRS in the retinal, choroidal, and conjunctival vasculature and to demonstrate their ultrastructural features in these locations.

Materials and methods

Postmortem eyes from 17 patients who were HIV seropositive and had a diagnosis of AIDS were examined by both light and electron microscopy. Three surgical chorioretinal biopsy specimens and three conjunctival biopsy specimens were also similarly examined. Paraffin embedded 5 µm sections were stained with haematoxylin and eosin, periodic acid Schiff (PAS), Gomori-methanamine-silver (GMS), and Gram methods.

For electron microscopic studies, the tissues were fixed in 10% buffered formalin, postfixed in 2% glutaraldehyde, followed by 1% osmium tetroxide. Thick sections (~1 µm) were stained with toluidine blue and paragon. Ultrathin sections (40-60 nm) were mounted on copper grids, stained with uranyl acetate and lead citrate, and examined with a Jeol 100 CX electron microscope.

We examined an average of 15 grids from each specimen, with special attention to the presence of TRS in the retinal and choroidal vasculature.

Results

The pertinent clinical findings and prevalence of TRS in 23 patients are summarised in Table 1. Nine patients who had no ocular symptoms showed no histological evidence of retinitis. All three surgical chorioretinal biopsy specimens were ophthalmoscopically diagnosed as cytomegalovirus (CMV) retinitis and were confirmed by light and electron microscopic studies. The conjunctival biopsies were performed with a presumptive diagnosis of

Department of Ophthalmology, Cullen Eye Institute, Baylor College of Medicine, Houston, USA

R K Maturi
R L Font

Correspondence to: Ramon L Font, MD, Ophthalmic Pathology Laboratory, Cullen Eye Institute, Baylor College of Medicine, Houston, TX 77030, USA.

Accepted for publication 30 November 1995

Table 1 Prevalence of tubuloreticular structures (TRS) in 23 patients with AIDS

A	17 autopsy eyes.	
	● 6 eyes with cytomegalovirus (CMV) retinitis	6/6 had TRS
	● 9 eyes with no clinical or histological retinal lesions	6/9 had TRS
	● 2 eyes with opportunistic infections*	1/2 had TRS
B	3 surgical chorioretinal biopsy specimens	
	● 3 eyes with clinical CMV	3/3 had TRS
C	3 conjunctival biopsy specimens	
	● 3 eyes with punctate epithelial keratoconjunctivitis	3/3 had TRS
	Overall prevalence of tubuloreticular structures	19/23 (83%)

**Histoplasma capsulatum* and *Proteus* sp were isolated from peripheral blood cultures (one patient each) and demonstrated in the ocular tissues by special stains.

microsporidial keratoconjunctivitis. In these three biopsy specimens, we found intracellular electron dense, lipoidal bodies mostly in the epithelial cells and TRS in the capillary endothelial cells. No microsporidia were identified.

We observed that eyes without TRS in the retinal capillaries also failed to demonstrate these structures in the choroidal vasculature.

Representative ultrastructural features of the TRS in the retinal and choroidal endothelial cells are illustrated in Figures 1–3. Figure 4 depicts the presence of TRS in a plasma cell

associated with a chronic non-granulomatous choroiditis in a patient with histologically proved CMV retinitis.

Discussion

Our studies demonstrate a high prevalence of TRS in the ocular structures of patients with AIDS. Sidhu and coworkers studied 97 patients with AIDS and found a similar prevalence (85%) of TRS in the endothelial cells from multiple anatomical sites.¹³ We also note that TRS identified in ocular/adnexal tissues are ultrastructurally quite similar to those observed in other anatomical locations. Thus, their mechanism of formation, while still under some debate, is presumably analogous to that observed in other tissues.

Some observers have suggested that TRS may be of viral origin,^{1 14} given their close association with viral diseases. TRS are primarily composed of membrane phospholipids and glycoproteins. Evidence against a viral origin includes their lack of nucleic acids, digestion with proteases and pepsin, and insensitivity to digestion with trypsin and ribonuclease.¹

The nucleoprotein strands of myxoviruses and paramyxoviruses have been confused ultrastructurally with TRS. The viral nucleocapsids of the myxovirus/paramyxoviruses have a helical configuration, are not associated with the rough surfaced endoplasmic reticulum, and rarely exceed 18 nm in diameter. In contrast, the tubular structures of TRS measure 20–30 nm in diameter and are contiguous with the endoplasmic reticulum.³

Another hypothesis regarding the origin of TRS suggests that they may be an unusual morphological response of the rough surfaced

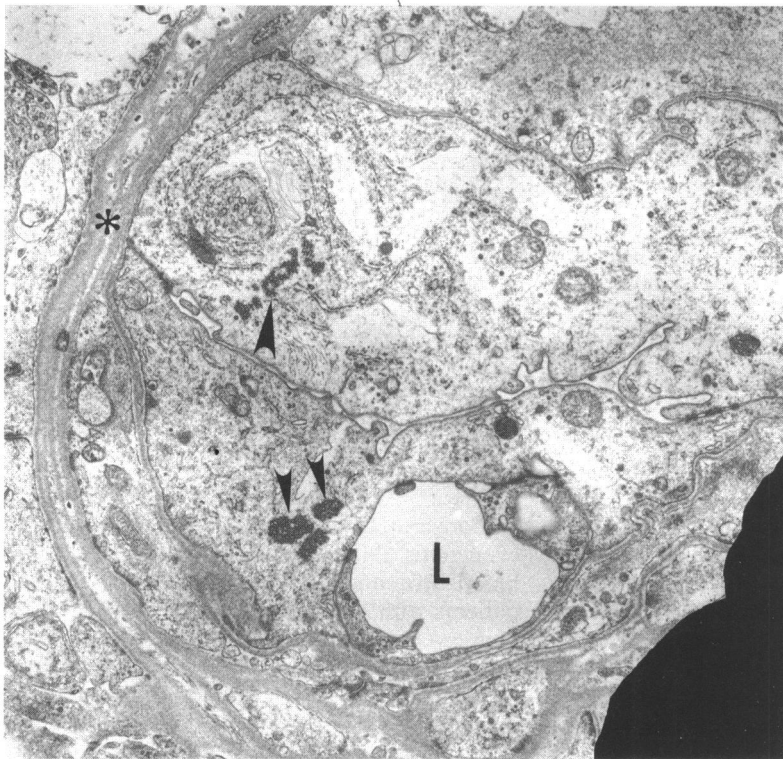


Fig 1A

Figure 1 (A) Low power view of retinal capillary. The endothelial cells appear swollen and the lumen (L) is narrow and eccentrically displaced. Asterisk (*) outlines the basement membrane of the capillary. Several tubuloreticular structures are visible (small arrowheads). Some tubuloreticular structures appear to be merging with the rough surfaced endoplasmic reticulum (large arrowhead) ($\times 10\,000$).

(B) High power view of adjacent section of (A) displaying the tubuloreticular structures (small arrowheads). The tubuloreticular structures on the upper left appear to fuse with the adjacent lamellae of the rough surfaced endoplasmic reticulum (large arrowhead). The plasma membrane of the endothelial cell is incomplete adjacent to the tubuloreticular structures on the left. Cytoplasmic microfilaments (F) ($\times 24\,800$).

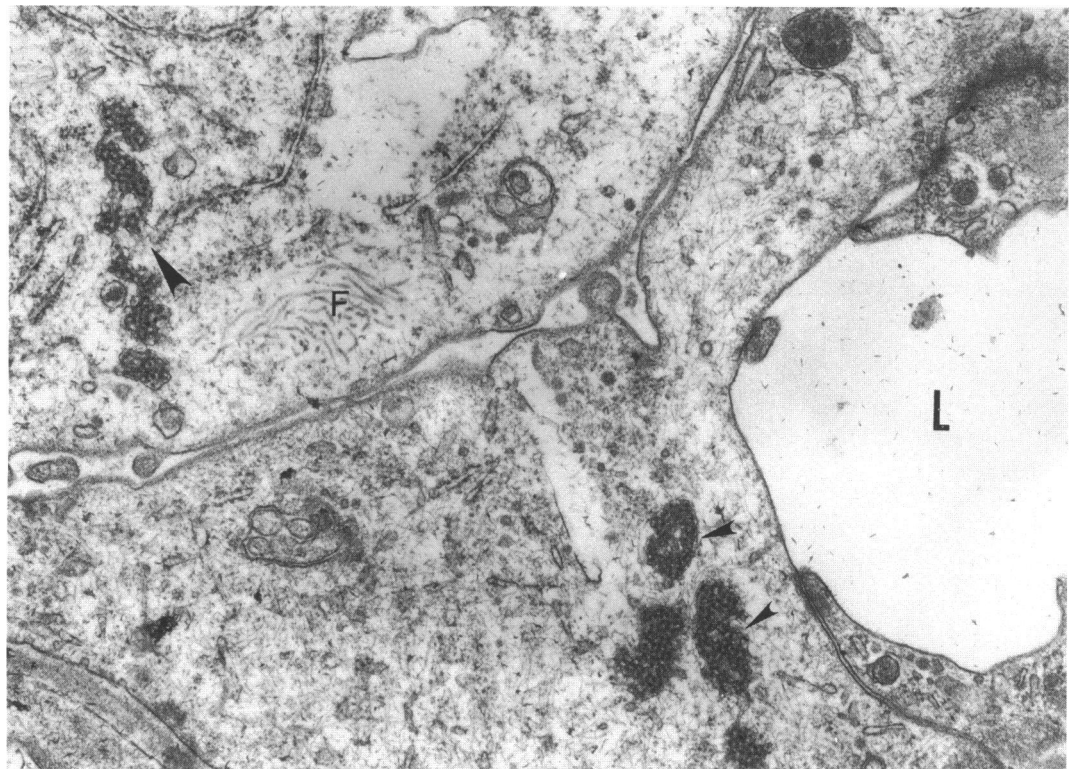


Fig 1B

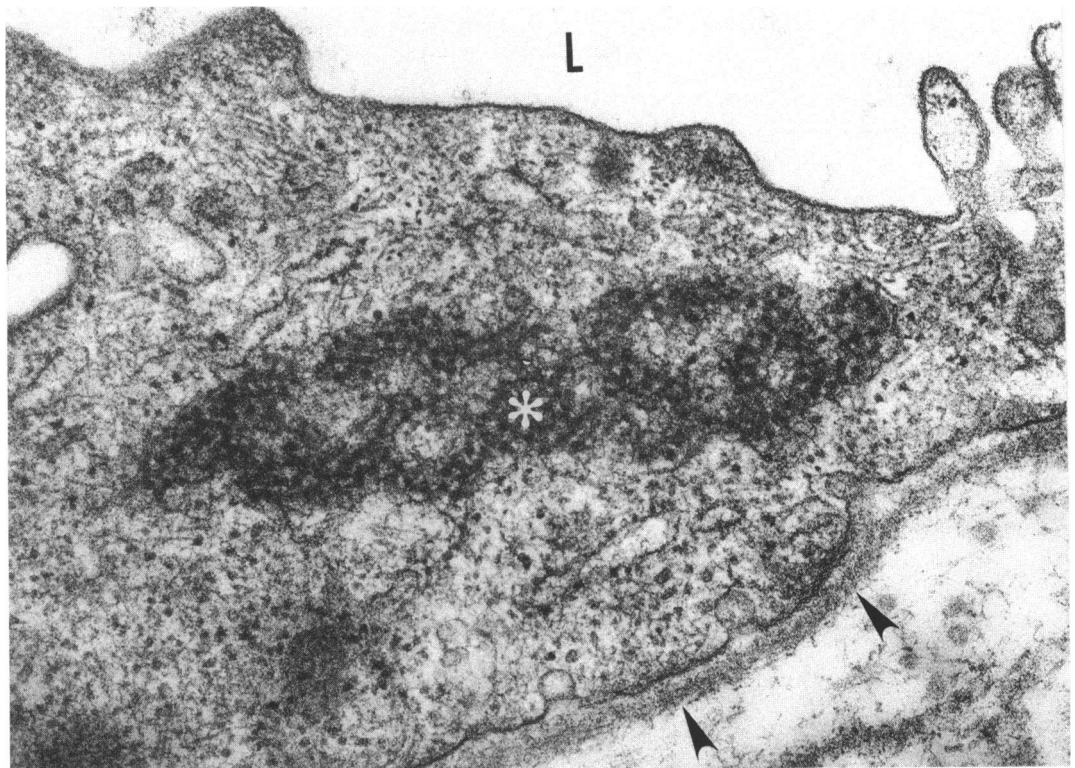


Figure 2 High power view of an endothelial cell from a retinal capillary depicting on cross section the confluent hollow tubular structures. Lumen (L) and basement membrane (arrowheads) ($\times 58\,300$).

endoplasmic reticulum occurring in cells subjected to various insults. Thus, TRS may represent a morphological expression indicative of cellular injury.¹

There is significant evidence that TRS represent a cellular response to increased serum levels of interferon alfa ($\text{INF } \alpha$).¹⁵⁻¹⁸ This association was first noted after the discovery that patients with systemic lupus erythematosus (SLE) had increased serum levels of

$\text{INF } \alpha$.¹⁹ Additionally, in vitro studies have demonstrated the induction of TRS by exogenous $\text{INF } \alpha$ when added to peripheral blood lymphocytes.²⁰ It is noteworthy that patients with AIDS, like those with SLE, have high levels of $\text{INF } \alpha$.¹⁵

The presence of TRS in ocular/adnexal structures in a previously HIV seronegative patient may indicate the presence of a collagen vascular disease (typically SLE or scleroderma) or other

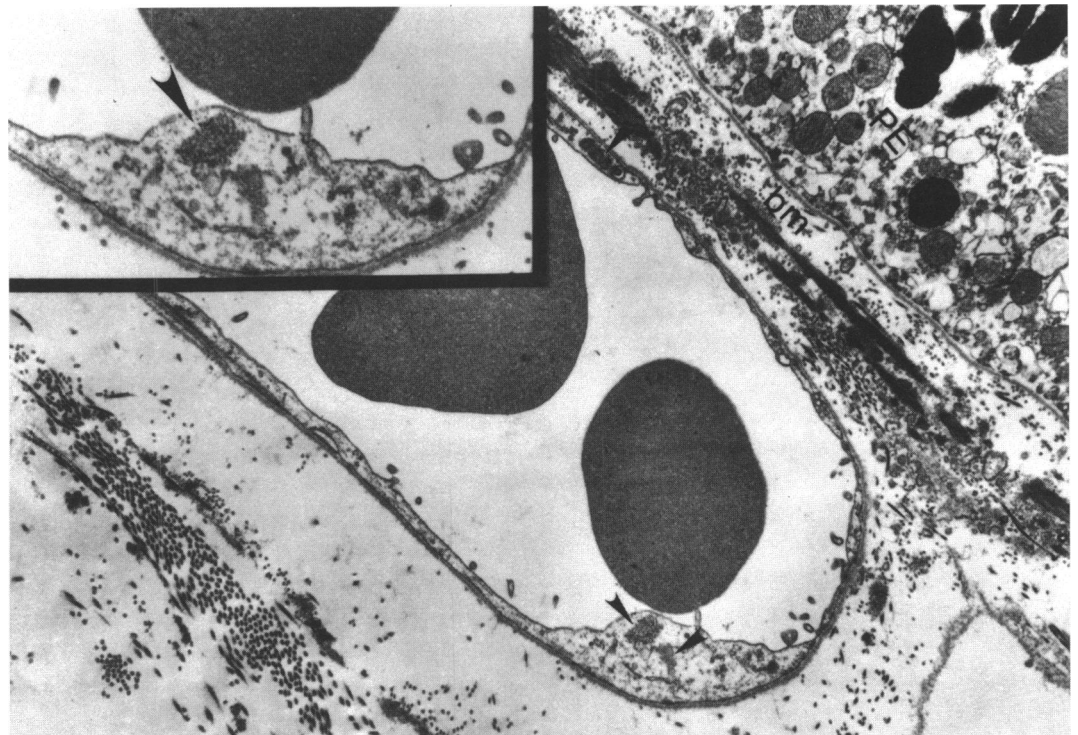


Figure 3 Low power view demonstrating several tubuloreticular structures in the endothelial cells of the choriocapillaris (arrowheads). Bruch's membrane (bm), and retinal pigment epithelium (PE) ($\times 7800$). Inset demonstrates a high power view of the tubuloreticular structures in the cytoplasm of the endothelial cell shown below ($\times 14\,350$).

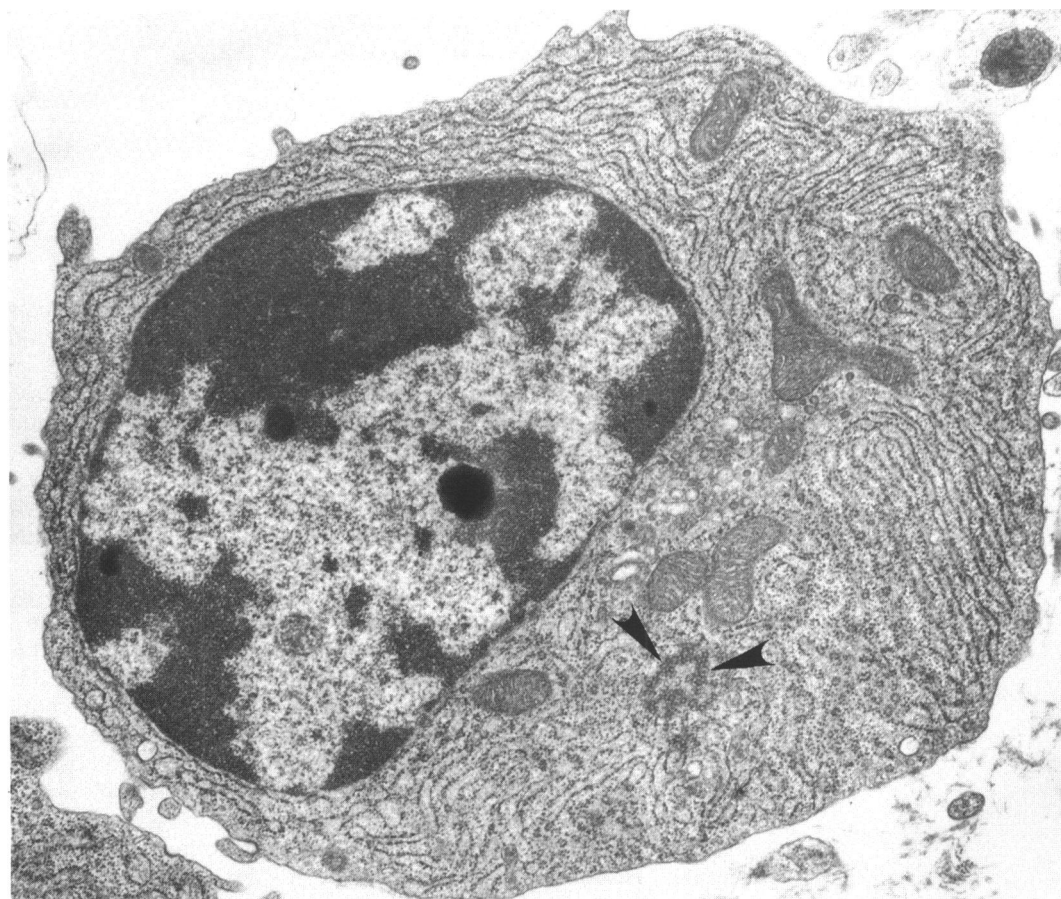


Figure 4 Chorioretinal biopsy specimen from a patient with histologically proved cytomegalovirus retinitis showing a plasma cell within the choroid. Tubuloreticular structures are demonstrated in the cytoplasm (arrowheads) ($\times 11\,600$).

immunologically mediated disorders. If TRS are found in the ocular/adnexal tissues of HIV seronegative patients, we would suggest performing a complete immunological examination (antinuclear antibody, rheumatoid factor, etc) to exclude the possibility of a collagen-vascular disorder. If these results are negative, we believe that periodic HIV antibody testing is indicated to exclude the possibility that the patient might be in the prodromal stage of infection.

This study was supported in part by grants from the Retina Research Foundation and the Lions Eye Bank, Houston, Texas and the Research to Prevent Blindness, New York, USA.

- 1 Luu, J, Bokus D, Remington F, Bean M, Hammar S. Tubuloreticular structures and cylindrical confronting cisternae: a review. *Hum Pathol* 1989; 20: 617-27.
- 2 Fuller G, Jacobs J. Cytoplasmic inclusions in the peripheral nerves in AIDS. *Acta Neuropathol* 1989; 79: 336-9.
- 3 Schaff Z, Barry DW, Grimley PM. Cytochemistry of tubuloreticular structures in lymphocytes from patients with systemic lupus erythematosus and in cultured human lymphoid cells: comparison to a paramyxovirus. *Lab Invest* 1973; 29: 577-85.
- 4 Mette SA, Palevsky HI, Pietra GG, Williams TM, Bruder E. Primary pulmonary hypertension in association with human immunodeficiency virus infection. *Am Rev Resp Dis* 1992; 145: 1195-200.
- 5 Blandshard C, Ellis DS, Tovey G, Gazzard BG. Electron microscopy of rectal biopsies in HIV-positive individuals. *J Pathol* 1993; 169: 79-87.
- 6 Mezin P, Brion J, Vermont J, Micound M, Stoebner P. Ultrastructural changes associated with peripheral neuropathy in HIV/AIDS. *Ultrastruct Pathol* 1991; 15: 593-602.
- 7 Cohen AH, Nast CC. HIV-associated nephropathy: a unique combined glomerular, tubular, and interstitial lesion. *Mod Pathol* 1988; 1: 87-97.
- 8 Chander P, Agarwal A, Soni A, Kim K, Tresler G. Renal cytoplasmic inclusions in idiopathic renal disease as predictive markers for the acquired immunodeficiency syndrome. *Hum Pathol* 1988; 19: 1060-4.
- 9 Kostianovsky M, Kang YH, Grimley PM. Disseminated tubuloreticular inclusions in the acquired immunodeficiency syndrome (AIDS). *Ultrastruct Pathol* 1983; 4: 331-6.
- 10 Grimley PM, Schaff Z. Significance of tubuloreticular inclusions in the pathobiology of human diseases. *Pathobiol Ann* 1976; 6: 221-57.
- 11 Jensen OA. Cytoplasmic structures in endothelial cells of the choroid: case for the panel. *Ultrastruct Pathol* 1985; 8: 375-9.
- 12 Wilhelmus KR, Keener MJ, Jones DB, Font RL. Corneal lipidosis in patients with the acquired immunodeficiency syndrome. *Am J Ophthalmol* 1995; 119: 14-9.
- 13 Sidhu GS, Stahl RE, El-Sadr W, Cassi ND, Forrester EM, Zolla-Pazner S. The acquired immunodeficiency syndrome: an ultrastructural study. *Hum Pathol* 1985; 16: 377-86.
- 14 Bariety J, Amor B, Kahan A, Balfrej JL, Delbarre F. Ultrastructural anomalies in mononuclear cells of peripheral blood in SLE: presence of virus-like inclusions. *Eur J Clin Biol Res* 1971; 16: 715.
- 15 Orenstein JM, Preble OT, Kind P, Schulof R. The relationship of serum alpha-interferon and ultrastructural markers in HIV-seropositive individuals. *Ultrastruct Pathol* 1987; 11: 673-9.
- 16 Grimley PM, Davis GL, Dooley JS, Strohmaier J, Hoofnagle JH. Tubuloreticular inclusions in peripheral blood mononuclear cells related to systemic therapy with α -interferon. *Lab Invest* 1985; 52: 638-49.
- 17 Hooks JJ, Moutsopoulos HM, Geis SA, Stahl NI, Decker JL, Notkins AL. Immune interferon in the circulation of patients with autoimmune disease. *N Engl J Med* 1979; 301: 5-8.
- 18 Grimley PM, Rutherford MN, Kang Y, Williams T, Woody JN, Silverman RH. Formation of tubuloreticular inclusions in human lymphoma cells compared to the induction of 2'-5' oligoadenylate synthetase by leucocyte interferon in dose-effect and kinetic studies. *Cancer Res* 1984; 44: 3480-8.
- 19 Rich SA, Owens TR, Anzola CM, Bartholomew LE. Induction of lupus inclusions by sera from patients with systemic lupus erythematosus. *Arthritis Rheum* 1986; 29: 501-6.
- 20 Feldman DG, Goldstein AL, Cox DC, Grimley PM. Cultured human endothelial cells treated with recombinant leukocyte A interferon (rIFN- α). Tubuloreticular inclusion formation, anti-proliferative effect and 2'-5' oligoadenylate synthetase induction. *Lab Invest* 1988; 58: 584-9.