

## LETTERS TO THE EDITOR

## Benign fleck retina

EDITOR.—We report a case of flecked retinal dystrophy in a child of mixed Australian aboriginal and white descent. Both fundi showed widespread discrete yellow-white fleck lesions at the level of retinal pigment epithelium, extending to the far periphery but sparing the macular region. Visual acuity was normal and the electroretinogram showed no abnormality. To our knowledge no other family members are affected, and there is no history of consanguinity between the parents. The phenotype appears similar to the 'benign familial fleck retina' described by Aish and Dajani,<sup>1</sup> and we believe this to be the first published report of such a case since the original description in 1980.

## CASE REPORT

A 12-year-old girl was referred after her optometrist noted areas of retinal abnormality on ophthalmoscopy after a routine refraction. She complained of occasional headaches, but had no specific ocular symptoms and was in good general health. Drug or substance abuse was denied. There was no history of maternal illness or nutritional deficiency during pregnancy, and the patient was born at full term. Visual and general development were reportedly normal during infancy and early childhood, and the mother noted no signs of poor daytime or night vision in any of her three children.

The child was of mixed ethnic origin, the non-consanguineous parents both being of mixed Australian aboriginal and white descent, and there was no family history of ocular or systemic disease other than the recent development of maturity onset diabetes mellitus in the mother.

General examination found no evidence of skin depigmentation or vitiligo. Visual acuities were 6/9 right with +0.50 DS/-1.00 DC×180 degrees, 6/6 left with +0.50 DS. Slit-lamp examination of anterior segments and vitreous was normal. Funduscopy revealed a striking pattern of multiple yellow-white flecks situated at a level deep to the retinal vessels, affecting both fundi in a symmetrical pattern (Fig 1). The lesions were distributed in a concentric pattern around the posterior fundus but sparing the optic disc, papillomacular bundle, and the peripapillary area for a distance of 1 disc diameter except inferiorly, where there was involvement to the margin of the optic disc. No part of the equatorial, peripheral, or far peripheral retina was spared. The shape of the flecks was highly variable. The most centrally located lesions were roughly round or oblong in shape, and approximately the diameter of a third order arteriole. With increasing distance from the central macula, the flecks tended to become much larger and confluent, up to 1/2 disc diameter in size across the largest dimension. The more peripheral flecks showed greater variability in shape, with linear, geographical, or amoeboid outlines and smooth sinuous margins. On stereoscopic slit-lamp biomicroscopy, the fleck lesions appeared flat, with no evidence of accumulated material within or anterior to retinal pigment epithelial cells. There was no evidence of pigment migration, although several of the larger lesions enclosed areas of normally pigmented retina, giving the

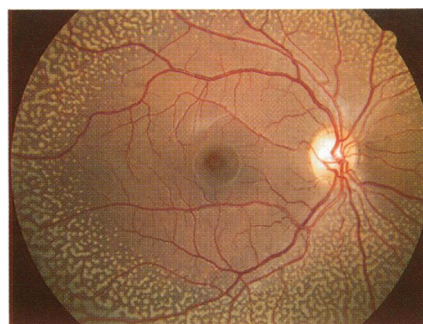


Fig 1A

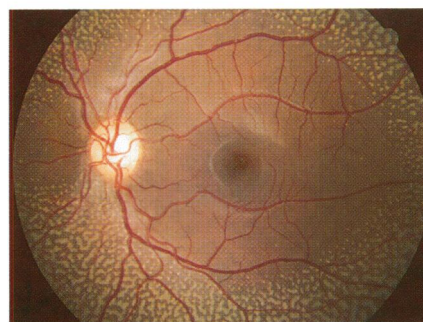


Fig 1B

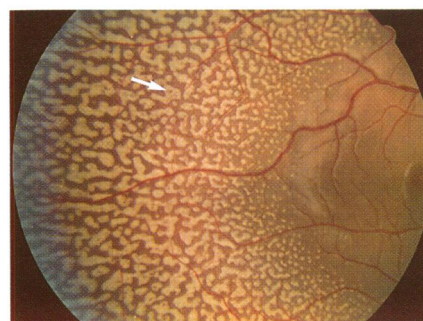

Fig 1C

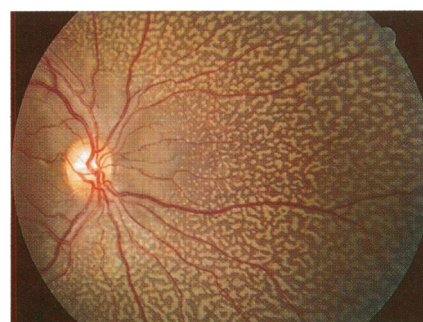


Fig 1D

appearance of a central pigment clump (Fig 1C, arrowed). No calcification was seen, and choroidal vessels were not visible at the base of the flecks. Fundus fluorescein angiography revealed patchy, fine, irregular hyperfluorescence throughout the fundus which did not correspond to the fleck lesions (Fig 2).

appearance of a central pigment clump (Fig 1C, arrowed). No calcification was seen, and choroidal vessels were not visible at the base of the flecks. Fundus fluorescein angiography revealed patchy, fine, irregular hyperfluorescence throughout the fundus which did not correspond to the fleck lesions (Fig 2).

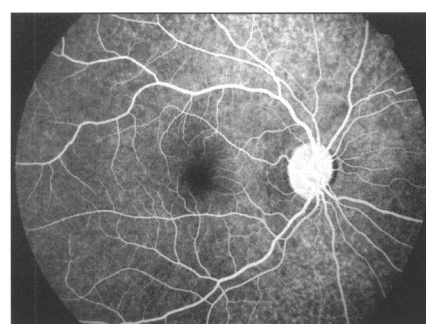


Fig 2A

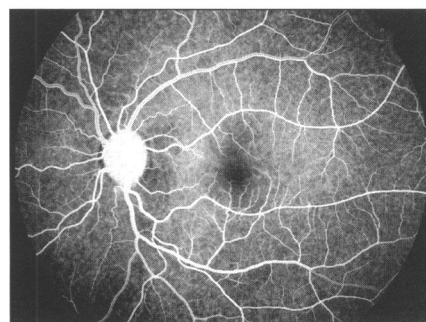


Fig 2B

Figure 2 Fundus fluorescein angiograms. (A) Right eye, venous phase. (B) Left eye, arteriovenous phase. Retinal and choroidal vascular filling is normal. There is diffuse irregular hyperfluorescence throughout both fundi, which does not correspond to the fleck lesions, suggesting a diffuse abnormality of retinal pigment epithelium.

Colour vision testing with Ishihara plates and the Farnsworth dichotomous (D-15) test was normal in each eye. Electro-oculogram (EOG) Arden ratios were at the lower end of the normal range at 1.7 and 1.6 in right and left eyes, respectively. The full field electroretinogram (ERG) was recorded under photopic and scotopic conditions (Fig 3), and was normal except for a slight delay in the b-wave latency from the left eye during 30 Hz flicker stimulation.

At follow up examination 18 months later the headaches had resolved and there were no new ocular symptoms. Visual acuities and funduscopy appearances were unchanged. Both parents and the only sister of the proband have been examined. All are asymptomatic, and funduscopy is normal in each case. The patient's remaining sibling, an older brother, is asymptomatic and has indicated that he is unwilling to undergo ophthalmic examination.

## COMMENT

Our case is characterised by the presence of widespread discrete yellow-white fleck lesions affecting both fundi of an asymptomatic child of mixed Australian aboriginal descent. The macular region is spared and functional testing has revealed no significant abnormality. Stereo slit-lamp biomicroscopy suggests that the location of the flecks is sub-retinal, yet has revealed no evidence of either atrophic or hypertrophic retinal pigment epithelial cells. Fluorescein angiography is unhelpful in elucidating the precise nature of the retinal dystrophy, since the flecks show

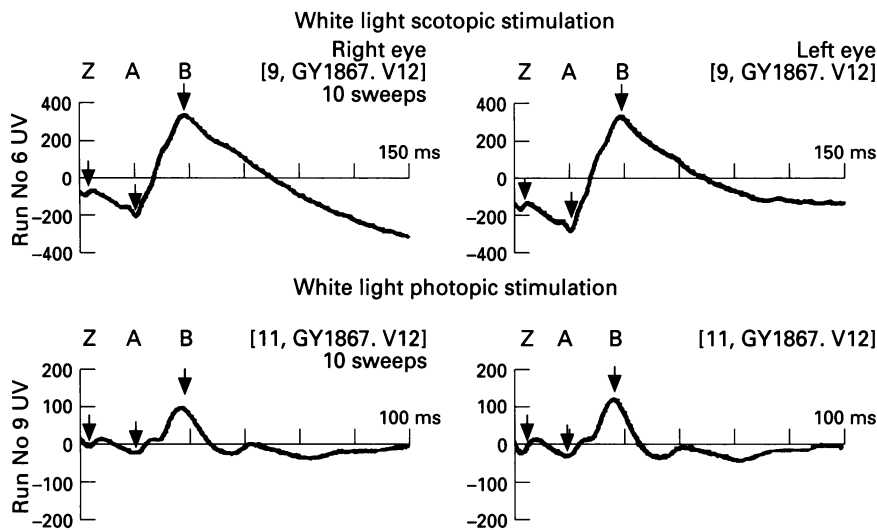


Figure 3 Full field Ganzfeld electroretinogram (ERG). Upper traces show scotopic ERG elicited by a single white flash in the dark adapted eye: A-wave latency 25.5 ms RE, 25.7 ms LE (normal range 24.4–28.1 ms), amplitude 121.0  $\mu$ V RE, 131.0  $\mu$ V LE (normal range 56.1–185.2  $\mu$ V). B-wave latency 48.0 ms RE, 47.8 ms LE (43.8–53.1 ms) and amplitude 548.0  $\mu$ V RE, 616.0  $\mu$ V LE (348.0–679.6  $\mu$ V). Lower traces show photopic ERG response to a single white flash: A-wave latency 16.6 ms in each eye (normal range 16.5–18.9 ms) and amplitude 27.0  $\mu$ V RE, 28.0  $\mu$ V LE. B-wave latency 30.7 ms RE, 31.0 ms LE (27.5–31.8 ms) and amplitude 121.0  $\mu$ V RE, 151.0  $\mu$ V LE (39.1–207.1  $\mu$ V). All normal range values represent mean (2 SD).

neither a 'window defect' suggesting depigmentation, nor hypofluorescence, which might suggest an abnormal accumulation of material within retinal pigment epithelium cells. Instead, the mild generalised irregular hyperfluorescence suggests merely a diffuse abnormality of retinal pigment epithelium.

The occurrence of a marbled fundus in asymptomatic patients is rare. Aish and Dajani have described an Arab Palestinian family with clinical features which appear to closely resemble those of our patient.<sup>1</sup> In this pedigree, the parents were phenotypically normal first cousins. Seven out of 10 of their offspring showed massive invasion of both fundi by bright white or yellow fleck lesions situated behind the retinal blood vessels, and always sparing the macula. Visual findings were normal in all cases. The probable mode of inheritance within this family was autosomal recessive, since both sexes were involved, and the consanguineous parents were unaffected. Krogh *et al* have described an asymptomatic 31-year-old woman with normal visual acuity, with bilateral retinal flecks in the mid periphery of both eyes.<sup>2</sup> The flecks became more dense in the periphery, where they formed a palisade pattern quite unlike that of our case. Functional testing revealed an absent EOG light rise in one eye but was otherwise normal. More recently, a case of bilateral 'breadcrumb' flecked retinopathy with normal fluorescein angiography and normal electrophysiological findings has been reported in a 9-year-old girl. However, this child also had an idiopathic seizure disorder which had been controlled medically for 6 years, subnormal intelligence, gross motor and developmental delay, and esotropia.<sup>3</sup> The size and shape of the retinal flecks in this case are not described in detail, but the published photographs appear to demonstrate a more uniform size and more irregular margins to the flecks than in our patient, with a more linear distribution of flecks and a greater area of normal appearing retina between the flecks.

A marbled fundus appearance has also been reported as a rare finding in Leber's congenital amaurosis.<sup>4–6</sup> In this variant,

yellowish lesions are seen deep to the retinal vessels in a periarterial distribution, and there may be associated systemic abnormalities, including medullary cystic renal disease (juvenile nephronophthisis).<sup>7</sup> The other clinical features and absent ERG response of Leber's amaurosis make confusion with our case unlikely. However, it is interesting to note in such cases that a marbled fundus may be incidental to visual functional abnormalities.

We suggest that our case represents either a new mutation of the condition described, or possibly an autosomal recessive disorder, since both parents are phenotypically normal.

We wish to thank the Department of Medical Technology and Physics, Sir Charles Gairdner Hospital, for performing the electrophysiological testing.

TIMOTHY W ISAACS  
IAN L McALLISTER  
MATTHEW S WADE  
Department of Ophthalmology,  
Royal Perth Hospital,  
Wellington Street,  
Perth, Western Australia 6001,  
Australia

Correspondence to: Mr Timothy W Isaacs, Lions Eye Institute, 2 Verdun Street, Nedlands, Western Australia, WA 6009, Australia.

Accepted for publication 11 October 1995

- 1 Aish SFS, Dajani B. Benign familial fleck retina. *Br J Ophthalmol* 1980; **64**: 652–9.
- 2 Krogh E, Reersted P, Holm K. Flecked retina syndrome with palisade appearance in the periphery. A case study with a family investigation. *Int Ophthalmol* 1980; **2**: 77–80.
- 3 Protzko EE, Schatz H, Raymond WR 4th, McDonald HR, Johnson RN. Bread crumb-flecked retinopathy. *Retina* 1992; **12**: 21–3.
- 4 Franceschetti A, Forni S. Degenerescence tapeto-retinienne (type Leber) avec aspect marbre du fond de l'oeil peripherique. *Ophthalmologica* 1958; **135**: 610–8.
- 5 Chew E, Deutman A, Pinckers A, Aan De Kerck A. Yellowish flecks in Leber's congenital amaurosis. *Br J Ophthalmol* 1984; **68**: 727–31.
- 6 Schroeder R, Mets MB, Maumenee IH. Leber's congenital amaurosis. Retrospective review of 43 cases and a new fundus finding in two cases. *Arch Ophthalmol* 1987; **105**: 356–9.
- 7 Ticho B, Sieving PA. Leber's congenital amaurosis with marbled fundus and juvenile nephronophthisis. *Am J Ophthalmol* 1989; **107**: 426–8.

### Brown's syndrome as a complication of cardiopulmonary resuscitation

EDITOR.—Brown's syndrome is a well recognised ocular motility disorder which may be congenital or acquired. Regardless of aetiology it manifests itself clinically with restriction to both active and passive elevation in adduction, minimal or only slight limitation in abduction, and occasionally a downshoot of the affected eye in adduction and, in more severely affected cases, a primary position hypotropia with an associated abnormal head posture. The head posture consists of a chin-up head position with a face turned away from the affected side or a variable head tilt. Other features less commonly seen are a 'V' pattern resulting from divergence in upgaze and widening of the palpebral fissure on adduction.<sup>1</sup>

### CASE REPORT

We report a case of acquired Brown's syndrome in a 2-year-old girl without a history of ocular motility defects, who accidentally fell into the family swimming pool and was found cyanotic, face down in the water. Her mother, trained in cardiopulmonary resuscitation, rescued her from the pool and successfully resuscitated her using nasal compression, mouth to mouth ventilation, and cardiac massage. The patient was transferred to the Children's Hospital of Pittsburgh and, after a short period of artificial ventilation, made a full recovery. A computed tomography brain scan did not reveal any abnormality.

After hospitalisation it was noted that the child had developed a mild chin-up head posture. One week later her vision was 20/30 in each eye using Allen figures, she was orthophoric in the primary position of gaze, had a chin-up head posture without head tilt or face turn, and ocular versions revealed limitation of elevation in adduction (Fig 1). There was no evidence of superior oblique muscle overaction or downshoot in adduction. In addition, the right superior rectus muscle did not demonstrate overaction and there was some divergence in upgaze which helped to differentiate this entity from an isolated left inferior oblique paresis. She demonstrated 100 seconds of arc stereoacuity and had normal fusion for both distance and near using the Worth 4 dot test in the primary position of gaze. Magnetic resonance imaging of the orbits was normal and did not reveal any evidence of trochlear disinsertion or swelling. The orbital floor was intact. When the patient was considered sufficiently mature we performed forced duction testing under local anaesthesia which confirmed the diagnosis. The patient was 3 years old at this time. We did not feel it necessary to subject the patient to general anaesthesia when she first presented in order to confirm the diagnosis, particularly in light of her near drowning event.

This patient has been followed for 18 months and the restriction to elevation in adduction has improved significantly. As the patient did not have a significant head tilt and was orthophoric in primary position surgical intervention was not required.

### COMMENT

Acquired Brown's syndrome has been reported following traumatic events occurring in the region of the trochlea; these include peribulbar anaesthesia,<sup>2</sup> orbital surgery,<sup>3</sup> orbital roof fracture with superior oblique