

LETTERS TO THE EDITOR

***Acanthamoeba* keratitis: first recorded case from a Palestinian patient with trachoma**

Keratitis due to *Acanthamoeba* is a potentially sight threatening condition if unrecognised, or if inappropriate medical therapy is used.¹ The infection is being recognised worldwide.²⁻⁴ It is often associated in Europe and in the USA with contact lens wear; elsewhere, particularly in the tropics, it occurs most often in rural communities and can be associated with trauma and mud splashing.⁵

We present here the first recorded isolation of *Acanthamoeba* in a Palestinian patient with keratitis, not associated with either contact lens wear or the patient's recollection of trauma. The patient suffered from previous trachoma (Fig 1). Herbert's pits were clearly observable at the superior limbus, although there was no evidence of trichiasis.

CASE REPORT

A 65-year-old female UNRWA refugee presented with a 2 day history of diminished vision (counting fingers) in the right eye. The cornea was hazy and a small (2 mm) central abscess was present. Fundal examination revealed an old central retinal vein occlusion. Initial treatment was topical cephalothin (10%) and topical gentamicin (1.5%) both 2 hourly, and topical homatropine (2%). Local microbiology laboratory investigations proved unhelpful. The condition improved and she was discharged after 4 days.

On first review, 1 week later, there was a significant improvement. Treatment was changed to chloramphenicol (0.5%) ointment and topical Liquifilm three times daily. The patient re-presented 6 weeks later with a 3 day history of severe pain; vision had decreased to light perception. There was an elevated central lesion with surrounding ring abscess. The intraocular pressure was 35 mm Hg. A stromal biopsy was performed the following day and the tissues forwarded to the Tennent Institute in Glasgow, for microbiological analysis.

Meanwhile, with a high index of clinical suspicion of *Acanthamoeba* infection of the cornea, novel therapy with chlorhexidine (0.02%, 2 hourly) was instituted, in combination with topical dexamethasone (0.1%, four times daily), atropine (1%, twice daily), and topical Polycidin (polymyxin B, neomycin, gramicidin). The combination of chlorhexidine digluconate and propamidine isethionate (as Brolene), known to be effective against *Acanthamoeba* both in vitro and in vivo,^{6,7} was

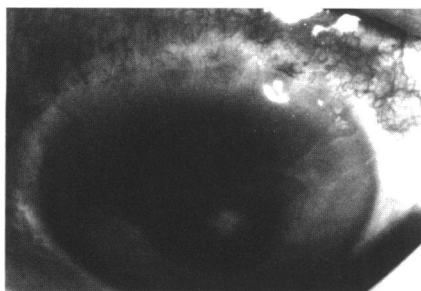


Figure 1 Appearance of cornea 1 week after biopsy, showing Herbert's pits and *Acanthamoeba* keratitis.

Table 1 Drug sensitivity of *Acanthamoeba* isolate from cornea

Drug	Minimum amoebicidal concentration ($\mu\text{g/ml}$)	
	Trophozoites	Cysts
Chlorhexidine	1.6	1.6
Polyhexamethylene biguanide	3.2	6.3
Alexidine	6.3	6.3
Propamidine	6.3	25.0
Pentamidine	12.5	50.0
Hexamidine	6.3	25.0
Neomycin	12.5	50.0

not used initially because of local unavailability of the diamidine. Neomycin was likewise unavailable as a single agent. The treatment brought about a rapid improvement in the appearance of the cornea. The patient was discharged 4 days later, having been taught the procedure for self administration of the antiprotozoal chemotherapy.

The corneal samples were incubated in a defined medium.⁸ After 1 week at 32°C there was prolific growth of *Acanthamoeba*. No bacteria or fungi were isolated. Drug sensitivity tests were performed⁶ (Table 1).

Two weeks later, the patient was readmitted with ocular pain. There was marked corneal oedema secondary to rubeotic glaucoma, the pressure being 55 mm Hg. Initially the pressure was reasonably well controlled with oral acetazolamide (250 mg, four times daily) and topical Timolol (0.5%, twice daily). There was considerable fluctuation over the following 5 weeks, however, and vision dropped to no perception of light. Ultimately, pressure reduction and comfort were achieved through use of cyclotherapy. By this time, Brolene had been received from Glasgow. At this point there was no perceptible progression of the ring abscess, but the rubeotic glaucoma remained problematic.

After discharge 4 weeks later, the patient attended clinic intermittently. She was not altogether compliant with the fairly demanding schedule required for self administration of the chlorhexidine-Brolene therapy. The corneal infection, however, appeared to be well controlled using this combination. Two months later, the patient re-presented with an area of central corneal staining and hypopyon. A deep corneal scrape was performed but rigorous microbiological examination failed to reveal any organisms, including *Acanthamoeba*. The patient was, however, treated with topical chlorhexidine (0.02%, 2 hourly), Brolene (2 hourly), dexamethasone (0.1%, four times daily), and chloramphenicol ointment (twice daily). Within 4 days, there was resolution and the patient was once again discharged. There has been no subsequent recurrence of the ocular disease.

COMMENT

Antibiotic therapy alone was unsuccessful for treatment of the keratitis in this case, resolution being accomplished only when a combination of a cationic antiseptic (chlorhexidine) and an aromatic diamidine (propamidine isethionate) was used. It was considered fortunate that corneal scrapings were forwarded to a centre with expertise in cultivation and identification of *Acanthamoeba*, since

the clinical features in this case were not especially reminiscent of those generally recorded for such an amoebal infection.⁹

Traumatic injury is likely to predispose the then compromised cornea to *Acanthamoeba* infection. For the contact lens wearer, there is now irrefutable evidence to demonstrate that the protozoa are derived from contaminated tap water,¹⁰ which is used as part of the cleaning disinfection procedures for the lenses and associated paraphernalia.

The observations from this case indicate that chronic trachomatous disease may also compromise the corneal surface such as to facilitate invasion by *Acanthamoeba*, and that this should be considered where other predisposing factors cannot be readily identified. Further, the clinical appearance of the *Acanthamoeba* infection, as in this case, may not be typical.

A PYOTT

St John's Ophthalmic Hospital,
Jerusalem 97200, Israel

J HAY

D SEAL

Tennent Institute of Ophthalmology,
Western Infirmary, Glasgow G11 6NT

Correspondence to: Dr J Hay.

Accepted for publication 6 May 1996

- 1 Kirkness CM, Hay J, Seal DV, Aitken D. *Acanthamoeba* keratitis. *Ophthalm Clin N Am* 1994;7:605-16.
- 2 Seal DV, Hay J, Kirkness CM. *Acanthamoeba* keratitis and contact lens wear: the need for a global strategy for prevention of corneal infection. *Community Eye Health* 1995;8:4-5.
- 3 Mohamed Kamel AG, Norazah A. First case of *Acanthamoeba* keratitis in Malaysia. *Trans Roy Soc Trop Med Hyg* 1995;89:652.
- 4 Hay J, Seal DV. *Acanthamoeba* keratitis, contact lenses, and the potential health implications of global marketing. *Trans Roy Soc Trop Med Hyg* 1996;90:331.
- 5 Thomas PA. *Acanthamoeba* keratitis. *Ind J Med Microbiol* 1995;13:51-3.
- 6 Hay J, Kirkness CM, Seal DV, Wright P. Drug resistance and *Acanthamoeba* keratitis; the quest for alternative antiprotozoal chemotherapy. *Eye* 1994;8:555-63.
- 7 Seal D, Hay J, Kirkness C, Morrell A, Booth A, Tullio A, et al. Successful medical therapy of *Acanthamoeba* keratitis with topical chlorhexidine and propamidine. *Eye* (in press).
- 8 Byers TJ, Akins RA, Maynard BJ, Lefken RA, Martin SM. Rapid growth of *Acanthamoeba* in defined medium: association of encystment by glucose-acetate starvation. *J Protozool* 1980;27:216-9.
- 9 Bacon AS, Dart JKG, Ficker LA, Matheson MM, Wright P. *Acanthamoeba* keratitis the value of early diagnosis. *Ophthalmology* 1993;100:1238-43.
- 10 Ledee DR, Hay J, Byers TJ, Seal DV, Kirkness CM. *Acanthamoeba* griffini. Molecular characterization of a new corneal pathogen. *Invest Ophthalmol Vis Sci* 1996;37:544-50.

Cytomegalovirus retinitis associated with long term oral corticosteroid use

EDITOR,—We examined a patient with a small area of peripheral retinitis in her left eye. She had been using oral corticosteroids continuously for 17 years for asthma. Despite treatment with intravenous acyclovir and laser photocoagulation the lesion recurred and resembled cytomegalovirus (CMV) retinitis. CMV DNA was detected in the aqueous humour using the polymerase chain reaction. She was HIV negative with normal T cell