

## LETTERS TO THE EDITOR

***Acanthamoeba* keratitis: first recorded case from a Palestinian patient with trachoma**

Keratitis due to *Acanthamoeba* is a potentially sight threatening condition if unrecognised, or if inappropriate medical therapy is used.<sup>1</sup> The infection is being recognised worldwide.<sup>2-4</sup> It is often associated in Europe and in the USA with contact lens wear; elsewhere, particularly in the tropics, it occurs most often in rural communities and can be associated with trauma and mud splashing.<sup>5</sup>

We present here the first recorded isolation of *Acanthamoeba* in a Palestinian patient with keratitis, not associated with either contact lens wear or the patient's recollection of trauma. The patient suffered from previous trachoma (Fig 1). Herbert's pits were clearly observable at the superior limbus, although there was no evidence of trichiasis.

## CASE REPORT

A 65-year-old female UNRWA refugee presented with a 2 day history of diminished vision (counting fingers) in the right eye. The cornea was hazy and a small (2 mm) central abscess was present. Fundal examination revealed an old central retinal vein occlusion. Initial treatment was topical cephalothin (10%) and topical gentamicin (1.5%) both 2 hourly, and topical homatropine (2%). Local microbiology laboratory investigations proved unhelpful. The condition improved and she was discharged after 4 days.

On first review, 1 week later, there was a significant improvement. Treatment was changed to chloramphenicol (0.5%) ointment and topical Liquifilm three times daily. The patient re-presented 6 weeks later with a 3 day history of severe pain; vision had decreased to light perception. There was an elevated central lesion with surrounding ring abscess. The intraocular pressure was 35 mm Hg. A stromal biopsy was performed the following day and the tissues forwarded to the Tennent Institute in Glasgow, for microbiological analysis.

Meanwhile, with a high index of clinical suspicion of *Acanthamoeba* infection of the cornea, novel therapy with chlorhexidine (0.02%, 2 hourly) was instituted, in combination with topical dexamethasone (0.1%, four times daily), atropine (1%, twice daily), and topical Polycidin (polymyxin B, neomycin, gramicidin). The combination of chlorhexidine digluconate and propamidine isethionate (as Brolene), known to be effective against *Acanthamoeba* both in vitro and in vivo,<sup>6,7</sup> was

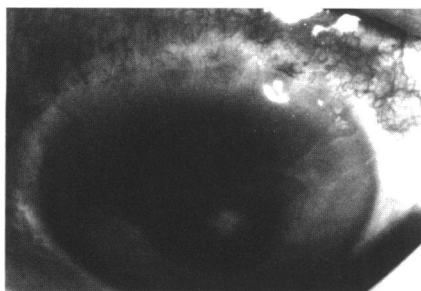


Figure 1 Appearance of cornea 1 week after biopsy, showing Herbert's pits and *Acanthamoeba* keratitis.

Table 1 Drug sensitivity of *Acanthamoeba* isolate from cornea

Drug	Minimum amoebicidal concentration ( $\mu\text{g/ml}$ )	
	Trophozoites	Cysts
Chlorhexidine	1.6	1.6
Polyhexamethylene biguanide	3.2	6.3
Alexidine	6.3	6.3
Propamidine	6.3	25.0
Pentamidine	12.5	50.0
Hexamidine	6.3	25.0
Neomycin	12.5	50.0

not used initially because of local unavailability of the diamidine. Neomycin was likewise unavailable as a single agent. The treatment brought about a rapid improvement in the appearance of the cornea. The patient was discharged 4 days later, having been taught the procedure for self administration of the antiprotozoal chemotherapy.

The corneal samples were incubated in a defined medium.<sup>8</sup> After 1 week at 32°C there was prolific growth of *Acanthamoeba*. No bacteria or fungi were isolated. Drug sensitivity tests were performed<sup>6</sup> (Table 1).

Two weeks later, the patient was readmitted with ocular pain. There was marked corneal oedema secondary to rubeotic glaucoma, the pressure being 55 mm Hg. Initially the pressure was reasonably well controlled with oral acetazolamide (250 mg, four times daily) and topical Timolol (0.5%, twice daily). There was considerable fluctuation over the following 5 weeks, however, and vision dropped to no perception of light. Ultimately, pressure reduction and comfort were achieved through use of cyclotherapy. By this time, Brolene had been received from Glasgow. At this point there was no perceptible progression of the ring abscess, but the rubeotic glaucoma remained problematic.

After discharge 4 weeks later, the patient attended clinic intermittently. She was not altogether compliant with the fairly demanding schedule required for self administration of the chlorhexidine-Brolene therapy. The corneal infection, however, appeared to be well controlled using this combination. Two months later, the patient re-presented with an area of central corneal staining and hypopyon. A deep corneal scrape was performed but rigorous microbiological examination failed to reveal any organisms, including *Acanthamoeba*. The patient was, however, treated with topical chlorhexidine (0.02%, 2 hourly), Brolene (2 hourly), dexamethasone (0.1%, four times daily), and chloramphenicol ointment (twice daily). Within 4 days, there was resolution and the patient was once again discharged. There has been no subsequent recurrence of the ocular disease.

## COMMENT

Antibiotic therapy alone was unsuccessful for treatment of the keratitis in this case, resolution being accomplished only when a combination of a cationic antiseptic (chlorhexidine) and an aromatic diamidine (propamidine isethionate) was used. It was considered fortunate that corneal scrapings were forwarded to a centre with expertise in cultivation and identification of *Acanthamoeba*, since

the clinical features in this case were not especially reminiscent of those generally recorded for such an amoebal infection.<sup>9</sup>

Traumatic injury is likely to predispose the then compromised cornea to *Acanthamoeba* infection. For the contact lens wearer, there is now irrefutable evidence to demonstrate that the protozoa are derived from contaminated tap water,<sup>10</sup> which is used as part of the cleaning disinfection procedures for the lenses and associated paraphernalia.

The observations from this case indicate that chronic trachomatous disease may also compromise the corneal surface such as to facilitate invasion by *Acanthamoeba*, and that this should be considered where other predisposing factors cannot be readily identified. Further, the clinical appearance of the *Acanthamoeba* infection, as in this case, may not be typical.

A PYOTT

St John's Ophthalmic Hospital,  
Jerusalem 97200, Israel

J HAY

D SEAL

Tennent Institute of Ophthalmology,  
Western Infirmary, Glasgow G11 6NT

Correspondence to: Dr J Hay.

Accepted for publication 6 May 1996

- Kirkness CM, Hay J, Seal DV, Aitken D. *Acanthamoeba* keratitis. *Ophthalm Clin N Am* 1994;7:605-16.
- Seal DV, Hay J, Kirkness CM. *Acanthamoeba* keratitis and contact lens wear: the need for a global strategy for prevention of corneal infection. *Community Eye Health* 1995;8:4-5.
- Mohamed Kamel AG, Norazah A. First case of *Acanthamoeba* keratitis in Malaysia. *Trans Roy Soc Trop Med Hyg* 1995;89:652.
- Hay J, Seal DV. *Acanthamoeba* keratitis, contact lenses, and the potential health implications of global marketing. *Trans Roy Soc Trop Med Hyg* 1996;90:331.
- Thomas PA. *Acanthamoeba* keratitis. *Ind J Med Microbiol* 1995;13:51-3.
- Hay J, Kirkness CM, Seal DV, Wright P. Drug resistance and *Acanthamoeba* keratitis; the quest for alternative antiprotozoal chemotherapy. *Eye* 1994;8:555-63.
- Seal D, Hay J, Kirkness C, Morrell A, Booth A, Tullio A, et al. Successful medical therapy of *Acanthamoeba* keratitis with topical chlorhexidine and propamidine. *Eye* (in press).
- Byers TJ, Akins RA, Maynard BJ, Lefken RA, Martin SM. Rapid growth of *Acanthamoeba* in defined medium: association of encystment by glucose-acetate starvation. *J Protozool* 1980;27:216-9.
- Bacon AS, Dart JKG, Ficker LA, Matheson MM, Wright P. *Acanthamoeba* keratitis the value of early diagnosis. *Ophthalmology* 1993;100:1238-43.
- Ledee DR, Hay J, Byers TJ, Seal DV, Kirkness CM. *Acanthamoeba* griffini. Molecular characterization of a new corneal pathogen. *Invest Ophthalmol Vis Sci* 1996;37:544-50.

**Cytomegalovirus retinitis associated with long term oral corticosteroid use**

EDITOR,—We examined a patient with a small area of peripheral retinitis in her left eye. She had been using oral corticosteroids continuously for 17 years for asthma. Despite treatment with intravenous acyclovir and laser photocoagulation the lesion recurred and resembled cytomegalovirus (CMV) retinitis. CMV DNA was detected in the aqueous humour using the polymerase chain reaction. She was HIV negative with normal T cell

markers and no systemic immunodeficiency disorder. She had reduced numbers of B cells and tests of T cell function showed a global reduced response to stimulation by antigens. The CMV retinitis probably resulted from long term oral corticosteroid use.

#### CASE REPORT

A 39-year-old woman presented in November 1994 to the Accident and Emergency Department of the Birmingham and Midland Eye Hospital with a recent onset of a shadow and floaters in the temporal field of her vision of her left eye.

She had previously attended in October 1993 with an unusual appearance of the temporal periphery of the right retina. This lesion was thought to be a retinoschisis and was adjacent to a region of chorioretinal atrophy. There was no evidence of inflammation in the vitreous or retina. The schisis was observed but a retinal detachment subsequently occurred and she underwent a vitrectomy in September 1994 following failure of conventional detachment surgery. A devastating *Haemophilus influenzae* endophthalmitis developed 3 days after surgery. Despite treatment with systemic and intravitreal antibiotics, and prednisolone 60 mg per day the eye became blind and phthisical. The corticosteroid dose was gradually reduced to 15 mg over the next 2 weeks.

She was a severe asthmatic who had suffered from recurrent bouts of lower respiratory tract infection and had been on systemic prednisolone continuously for the last 17 years. She had undergone many acute admissions to hospital for her asthma, necessitating short term increases in her corticosteroid therapy. This was gradually reduced to a maintenance dose of 5 mg per day. She presented to us 2 months after the episode of endophthalmitis affecting her right eye and was still on oral prednisolone 15 mg per day. She had active cold sores on her lips and in her left nostril. She did not appear malnourished.

Visual acuity was 6/9 in the left eye. There was a mild anterior uveitis, with a 1+ cells in the anterior chamber and fine keratic precipitates on the inferior cornea. There was 1+ of cells in the vitreous. Ophthalmoscopic examination showed a small, circumferential white area in the inferonasal periphery of the retina associated with sheathing of retinal arterioles and scattered haemorrhages (Fig 1).

The lesion in the nasal periphery of her left retina slowly progressed and a provisional diagnosis of acute retinal necrosis was made. Treatment with intravenous acyclovir, 10 mg/kg three times a day, was given and indirect laser photocoagulation applied around the lesion.

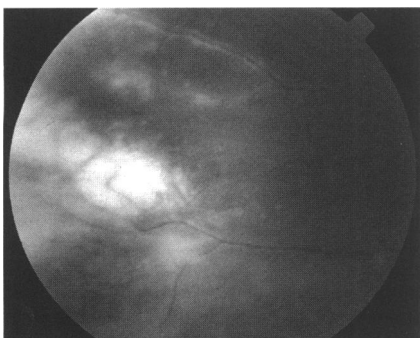


Figure 1 Necrotising retinitis in nasal periphery of left eye.

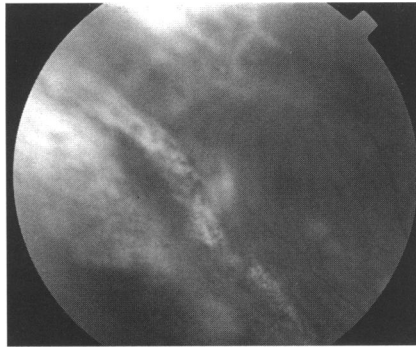


Figure 2 A recurrence detected superior to original lesion and laser photocoagulation scars.

After an initial improvement a recurrence resembling CMV retinitis was detected superior to the original lesion (Fig 2). An anterior chamber tap was performed. Polymerase chain reaction testing for herpesviral DNA detected CMV DNA in the aqueous humour but was negative for varicella zoster and herpes simplex type 1 and 2 viral DNA.

She was induced with intravenous ganciclovir at a dose of 5 mg/kg, twice daily for 2 weeks. Maintenance therapy was oral ganciclovir at a dose of 1 g three times per day, three times a week, resulting in resolution of the retinitis. Over the next 12 months the oral ganciclovir was reduced to a once a week dosage with no recurrence of the retinitis.

Investigations showed a normal full blood count, serum biochemistry, and serum immunoglobulins. Anticardiolipin, antinuclear and antinuclear cytoplasmic antibodies were all negative. Her HIV antibody test was also negative. Peripheral blood B cell numbers were reduced to  $0.02 \times 10^9/l$  ( $0.22 \times 10^9/l$  in a healthy control). She had normal T cell numbers and subtypes with her serum CD4 count being  $1.18 \times 10^9/l$  ( $0.48 \times 10^9/l$  in a healthy control). Her T cells responded normally to concanavalin A, phytohaemagglutinin, and pokeweed mitogen stimulation, but poorly to purified protein derivative, *Candida albicans* and herpes simplex viral antigens. The global nature of the antigen response defect suggested that it was secondary to the corticosteroid therapy. These results implied that the CMV retinitis resulted from long term oral corticosteroid use.

#### COMMENT

Although the commonest intraocular infection seen in AIDS patients, CMV retinitis is also a recognised complication of immunosuppressive therapy,<sup>1</sup> particularly after organ transplantation. Cyclosporin, azathioprine, and cyclophosphamide have an intermediate effect and corticosteroids a minimal effect in inducing CMV disease.<sup>2</sup> Patients with rheumatological disorders on long term immunosuppression may develop a rapidly progressive CMV retinitis.<sup>3</sup>

There have been two reports in the literature of CMV retinitis in 'immunocompetent' patients.<sup>4,5</sup> It was found to be reversible without treatment in one case,<sup>4</sup> and in the other it was attributed to exposure to chronically sick children.<sup>5</sup> No test results of immune function were given and the diagnosis was made on serological investigations alone.

A case of culture proved cytomegalovirus panuveitis involving both eyes of a previously healthy young woman receiving immunosuppressive doses of corticosteroids has been reported.<sup>6</sup> The virus was isolated from subretinal fluid obtained during retinal detach-

ment surgery. The corticosteroids were given following craniotomy for evacuation of a subacute right subdural haematoma.

Ophthalmologists should now be aware of another potential complication of corticosteroid usage.

M K KULSHRESTHA  
R R GOBLE  
P I MURRAY

Birmingham and Midland Eye Centre

Correspondence to: Mr P I Murray, Academic Unit of Ophthalmology, Birmingham and Midland Eye Centre, City Hospital NHS Trust, Dudley Road, Birmingham B18 7QH.

Accepted for publication 24 May 1996

- 1 Winkler A, Finan MJ, Pressly T, Roberts R. Cytomegalovirus retinitis in rheumatic disease: a case report. *Arthritis Rheum* 1987;30:106-8.
- 2 Ong ELC. Viral infections in the immunocompromised host. *Clin Virol* 1995;18-23.
- 3 Scott WJ, Giangiacomo J, Hodges KE. Accelerated cytomegalovirus retinitis secondary to immunosuppressive therapy. *Arch Ophthalmol* 1986;104:1117-24.
- 4 England AC, Miller SA, Maki DG. Ocular findings of acute cytomegalovirus infection in an immunologically competent adult. *N Engl J Med* 1982;8:94-5.
- 5 Chawla HB, Ford MJ, Munro JF, Scorgie RE, Watson AR. Ocular involvement in cytomegalovirus infection in a previous healthy adult. *BMJ* 1976;2:281-2.
- 6 Berger BB, Weingerg RS, Tessler HH, Wyhinny GJ, Vygantas CM. Bilateral cytomegalovirus panuveitis after high dose corticosteroid therapy. *Am J Ophthalmol* 1979;88:1020-

#### Unilateral choroidal melanoma with bilateral retinal vasculitis

EDITOR,—The association of choroidal melanoma with ipsilateral ocular inflammation is recognised and has most frequently been noted in those with tumour necrosis and mixed or epithelioid cell types.<sup>1</sup> Sympathetic ophthalmitis has also been observed with necrotic choroidal melanomas, often with extrascleral extension.<sup>2</sup> Distant carcinoma associated retinopathy and more recently cutaneous melanoma associated retinopathy have both been reported with an accompanying bilateral retinal vasculitis.<sup>3,4</sup> We report a case of a 22-year-old man with a left anterior choroidal melanoma in association with a bilateral retinal vasculitis.

#### CASE REPORT

A 22-year-old man was referred with a 6 week history of a gradually enlarging left nasal field defect in association with bilateral visual floaters and occasional photopsia. He was otherwise fit and well.

Examination revealed 6/6 vision bilaterally. There was a left nasal field defect. The right field was full. Bilateral medium sized keratic precipitates were present with a plus/minus of anterior chamber cells.

There were 1+ of vitreous cells bilaterally. On the left he had a large solid anterior choroidal mass in the temporal periphery with a base and depth of approximately 13 mm. There was some subretinal fluid inferiorly. Bilateral focal retinal venous sheathing was evident with some associated retinal new vessels inferiorly in the right fundus. General medical examination was unremarkable.

A fluorescein angiogram demonstrated mottled hyperfluorescence over the mass. There were focal areas of perivenous leakage in peripheral retinal venules but no capillary closure.