

COMMUNICATIONS

OCULAR LESIONS OF ONCHOCERCIASIS*

BY

F. H. BUDDEN†

Formerly Specialist Ophthalmologist, Overseas Civil Service, Northern Nigeria

THIS paper aims at describing, illustrating, and interpreting the ocular lesions associated with onchocerciasis. The literature of onchocerciasis already includes many pictures of the ocular lesions. The paintings‡ and diagrams in this paper supplement those previously published and are intended to fill gaps in the existing literature. The accompanying text expresses the author's views on the interpretation of the lesions and refers to alternative opinions. Particular attention is paid to the choroïdo-retinal lesions because they have been the subject of much controversy. It is hoped that the paper as a whole will assist workers in the field to distinguish and understand the lesions of onchocerciasis.

Eyelids and Conjunctiva

(1) Oedema of Eyelids.—This is usually a temporary lesion, no doubt similar to that occurring elsewhere in infected skin.

(2) Conjunctivitis.—Conjunctival infection occurs in response to the local presence, or more probably local death, of microfilariae. Mild chemosis is present in the more severe cases and a limbal inflammatory swelling, somewhat similar to, although more diffuse than, that found in "spring catarrh", may develop. Conjunctival phlyctens are occasionally present in heavy infections. These lesions are associated with photophobia and watering of the eyes. In long-standing infections, as with other chronic inflammations, the African conjunctiva becomes heavily pigmented, particularly near the limbus. The clinical appearance suggests an allergic reaction and the finding of eosinophils in conjunctival biopsies supports this interpretation.

The active inflammatory lesions of lids and conjunctiva are more marked in young persons (*i.e.* at an early stage of ocular invasion by microfilariae) and may be precipitated by therapy with diethylcarbamazine which kills microfilariae.

* Received for publication June 5, 1961.

† My thanks are due to the Medical Research Council for a grant covering the cost of the coloured plates, to Mr. G. T. W. Cashell for reading the draft, and to the Principal Medical Officer, Curative Division, Ministry of Health, Northern Nigeria, for permission to publish this paper.

‡ I apologize for the amateur quality of the illustrations. They were painted direct from patients mostly in temporary mat shelters in remote villages. No artist being available, they were made by the author who has had no previous experience of ocular painting.

Microfilariae may be found emerging from a snip of bulbar conjunctiva mounted in normal saline or water. However, although this procedure has been advocated for routine diagnosis, I do not recommend it. The chance of finding microfilariae is considerably less in a conjunctival biopsy than in skin from the outer canthus. If confirmation is required of the presence of microfilariae in the vicinity of the eye, a skin snip from the latter site causes less alarm to the patient and is more likely to prove positive.

Cornea

(1) **Intra-corneal Microfilariae.**—These are seen, after their death, as refringent, wavy, linear opacities, about 0.3 mm. in length, lying in the substantia propria. They may occur in any position but are most frequent in the interpalpebral area, near Bowman's membrane and close to the limbus. Possible explanations for this distribution are:

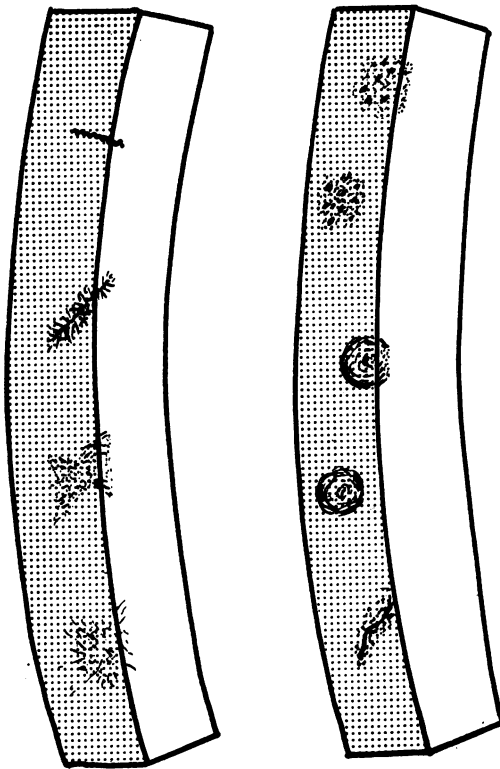


FIG. 1.

FIG. 2.

FIG. 1.—Diagram showing, from above down, stages in development of "cracked ice" corneal opacity around the body of a dead intra-corneal microfilaria.
 FIG. 2.—Diagram showing, from above down, two "snow-flake" corneal opacities, two nummular opacities, and an epithelial scar.

(a) Microfilariae entering the cornea at the limbus are phototropic and do not penetrate freely.

(b) Microfilariae reaching the interpalpebral area are killed by exposure to light.

(2) **"Cracked Ice" Opacities** (Fig. 1) and **"Snow-flake" Opacities** (Fig. 2, and the excellent painting published by Choyce, 1958, p. 116).—The "cracked ice" lesions were more common in my African patients, whereas "snow-flake" opacities were more common in my European patients. It is sometimes convenient to classify the two types together as "fluffy" opacities. Like microfilariae these lesions are most common in the interpalpebral area, close to the limbus and in the superficial layers of the substantia propria. In early corneal involvement the opacities are large (0.5 mm. or more in diameter) and show up clearly against the normal corneal stroma. However, in long-

standing ocular infections, particularly after the development of onchocercal sclerosing keratitis, the fluffy reaction is smaller and less clearly defined and tends to be obscured by widespread corneal oedema and sclerosis. "Fluffy" opacities are associated with mild photophobia, excessive lacrimation, and sometimes with a temporary slight impairment of visual acuity.

On several occasions I have watched a "cracked ice" opacity slowly develop during a period of weeks around a dead microfilaria. At an intermediate stage of development an elongated "cracked ice" pattern is seen around a disintegrating microfilaria (Fig. 1). It would appear that the "cracked ice" appearance is due to separation of fibres of the corneal stroma by oedema developing around a dead microfilaria.

"Fluffy" opacities persist for a considerable time. This is well illustrated by patients who receive combined treatment with suramin and diethyl-carbamazine, which eliminates microfilariae from the body. "Fluffy" opacities remain for several months but eventually resolve leaving no trace. In untreated patients, individual "fluffy" opacities probably resolve but are replaced by fresh opacities so long as intra-corneal death of microfilariae continues. However, where massive death of microfilariae occurs sclerosing keratitis may follow.

"Fluffy" opacities are easily distinguished from sub-epithelial nummular opacities (Fig. 2, and Hissette, 1938, p. 76) which are discoid and have a clear-cut margin. Unlike "fluffy" opacities they are permanent lesions. Ridley (1945) used the term "nummular" to describe the punctate corneal opacities produced by onchocerciasis, although it is clear from his description that he referred to lesions which are here called "fluffy". True discoid opacities are common in Nigeria, particularly in the Northern Region, and the term nummular should perhaps be reserved for these lesions. Their incidence in different villages is not related to that of onchocercal infection. Lesions closely resembling the "fluffy" opacities produced by onchocerciasis can be caused by other agents, notably viruses. However, although "fluffy" opacities occur in villages where onchocerciasis is not endemic, their incidence is very low. In villages where onchocerciasis is endemic, the incidence of these lesions rises with increases in the incidence and intensity of skin infection in the community.

(3) **Sclerosing Keratitis.**—I have watched this lesion develop in an area of cornea where the death of large numbers of microfilariae had produced confluent "fluffy" opacities. A few superficial blood vessels would invade the area and fibrosis would lead to permanent irregular opacification. At a later stage oedema, pigment deposits, and eventually degenerative changes, occur in the overlying epithelium. The lesion appears typically as tongues in the 4 and 8 o'clock positions, and extends around the lower corneal margin. An area of cornea adjacent to the limbus at 12 o'clock is

almost invariably spared. This distribution follows that of the intra-corneal microfilariae from which the lesion is derived.

The appearance was described and illustrated by Hissette (1938, p. 78) and described by Ridley (1945) under the alternative name of pannus. In view of the characteristic paucity of vessels, which Ridley noted, the term sclerosing keratitis suggested by French ophthalmologists is perhaps preferable.

The occurrence of inflammatory intra-corneal lesions around fragments of dead microfilariae has been demonstrated histologically by Rodger (1960).

(4) Pigmentation in the corneal epithelium is common in African eyes (presumably produced by migration of pigmented conjunctival epithelium). It occurs in onchocerciasis but is of no diagnostic value.

Anterior Chamber

Microfilariae are well adapted to the human host and, whilst they are alive in the anterior chamber, they appear to cause no damage. They may be observed by the following methods:

- (a) By direct illumination with the beam of a slit-lamp. They are then seen as bright motile threads against the dark background of the pupil or iris.
- (b) By retro-illumination using the +25D lens of a direct ophthalmoscope. This is best performed with the pupil widely dilated. Microfilariae are then seen as dark motile threads against the bright red fundus reflex in the pupil area (Sarkies, 1951).

The former method gives greater magnification but, since the eye of an African villager, the microfilariae, and the slit-lamp beam may all be moving at the same time, it is often difficult to find the microfilariae and impossible to count them accurately. The latter method gives smaller magnification but, since it provides a greater depth of focus and a view of the entire pupil area, a count may be made of the number of microfilariae in this field at any one time. However, counts of microfilariae in the anterior chamber, even by this method, often vary markedly from minute to minute.

Uvea

(1) **Inflammation of the Anterior Uvea.**—This is usually mild. Total population surveys in five infected rural communities of Northern Nigeria and the Southern Cameroons showed that, although no therapy had been administered, the commonest sign of anterior uveitis was inflammatory pigment disturbance without posterior synechiae. However, plastic iritis

(characterized by posterior synechiae and sometimes evidence of severe exudate) was found with increasing frequency as the incidence and intensity of infection rose in the community.

The active phase presents ciliary injection (often somewhat masked by circum-corneal pigment), keratic precipitates, flare, and cells in the anterior chamber. There may be exudate and I have seen hypopyon on four occasions in heavily infected patients. The resultant lesions are:

- (a) *Inflammatory Iris Pigment Disturbance*.—In onchocerciasis this is diffuse rather than patchy. Both the posterior pigment epithelium and the stroma are affected. A dramatic clinical feature is loss of the frill of pigment at the pupillary border. The frill is normally well marked in the negroid eye (Fig. 3, overleaf). The crypts and irregularities of the anterior surface are smoothed over so that the iris loses its normal lustre. The dark brown colour also changes. The iris comes to look like golden yellow blotting paper. Eventually the grey trabecular fibres may be exposed, although this is more characteristic of senile atrophy. Fine uveal pigment is deposited on the corneal endothelium and on the anterior surface of the lens (illustrated by Hissette, 1938, p. 64).
- (b) *Posterior Synechiae and Gross Pigment Deposits* on the anterior lens capsule. The pupil is sometimes completely secluded by posterior synechiae.
- (c) *Organized Exudate* in the pupil area or the base of the anterior chamber. The pupil may be drawn towards the latter site so that its border becomes pear-shaped (illustrated by Hissette, 1938, pp. 64, 70; and by Ridley, 1945, p. 26).
- (d) *Secondary Glaucoma* is a late complication.
- (e) *Cataract* associated with onchocercal uveitis is discussed later.

(2) Inflammation of the Posterior Uvea.—As in the anterior uvea, the inflammation is usually of low grade and long standing. Choroidal sclerosis is produced. Focal choroiditis of conventional type, although far less common than plastic iritis, is sometimes seen when infection is heavy.

- (a) *Inflammatory Choroidal Sclerosis*.—The initial sign is oedema, usually at the posterior pole and often to the outer side of the macula. This causes an irregular retinal reflex (Figs 4 and 5, overleaf). Later pigment disturbance at the posterior pole produces a mottled appearance. Established choroidal sclerosis causes a marked tigroid appearance of the fundus which is usually generalized by the time the African seeks medical advice. The overlying retinal pigment epithelium may remain intact, although apparently deficient in pigment (Fig. 6, overleaf), but is often denuded over wide clearly demarcated areas. Here the large choroidal vessels are clearly seen displaying varying degrees of sclerosis (Bryant, 1935, p. 526; Hissette, 1938, p. 84; Toulant and Boithias, 1954, pp. 569, 570; d’Haussy, Rit, and Lagraulet, 1958, p. 342; Figs 7, 8, 9, overleaf).

Choroidal exposure often commences at the outer side of the macula, spreads over the posterior pole of the eye and in long standing cases may become generalized. Gross retinal pigment masses are commonly found overlying, or adjacent to, these areas of exposure; whereas fine bone corpuscle patterns are more common where the retinal pigment epithelium is not completely denuded. It should be noted that, although clearly defined areas of choroidal exposure and underlying sclerosis are frequently seen in onchocerciasis, the surrounding choroid is usually also sclerosed. Ridley's painting (1945, Plate III), showing a patch of advanced choroidal sclerosis at the posterior pole surrounded by normal retina, is not typical of lesions seen in Nigeria. Small haemorrhages are occasionally seen.

The patients usually suffer from night blindness and visual fields become progressively restricted. Fairly good central telescopic vision may sometimes be retained for many years.

- (b) *Focal Choroiditis* (Fig. 10, overleaf).—In my experience this lesion is seen in heavily infected patients, is uncommon, and is usually, if not always, superimposed on inflammatory choroidal sclerosis.

Nature and Aetiology of Uveal Lesions

Hissette (1932) and Ridley (1945) believed the lesions to be inflammatory and excited by local death of microfilariae. This interpretation of the anterior uveal lesions has not been seriously challenged. Alternative suggestions have been made as to the cause of inflammatory choroidal sclerosis*:

Bryant (1935) reported the histological findings in an eye with advanced choroidal sclerosis. There were no microfilariae or signs of inflammatory reaction in the choroid or elsewhere in the eye, but there was marked interstitial fibrosis in the choroid and atrophy of the cellular layers of the retina. Clark (1947) found a similar histological picture. Bryant contrasted these findings with the presence of microfilariae throughout the eye and the perivascular inflammation around choroidal vessels, both of which were found in patients with advanced onchocercal keratitis.

Rodger (1957, 1958, 1960) also distinguished two lesions in the choroid. He postulated that "exudative" and "degenerative" lesions were aetiologically, clinically, and histologically distinct. The "exudative" lesion was an acute focal choroiditis believed to be due to local death of microfilariae in the choroid. The "degenerative" lesion was characterized by fibrosis of the stroma which insidiously overgrew the choriocapillaris, arterioles, and arteries. However, Rodger found plasma cell infiltration and intimal hyperplasia in some "degenerative" cases. He believed that this lesion was excited by the co-existence of low vitamin A intake and circulating onchocercal toxin.

Choyce (1958) noted that the clinical appearance of choroido-retinal lesions in five onchocercal patients resembled generalized choroidal sclerosis of familial type. He suggested that choroido-retinal degeneration, previously attributed to onchocerciasis, was due to genetic disease.

* This lesion has been referred to as choroido-retinal degeneration, even by those who believed the underlying choroidal lesion to be inflammatory. As will be apparent from the discussion, the term inflammatory choroidal sclerosis reflects the usual histological findings more accurately.




FIG. 3.—Normal iris (on left). Onchocercal iris atrophy (on right).

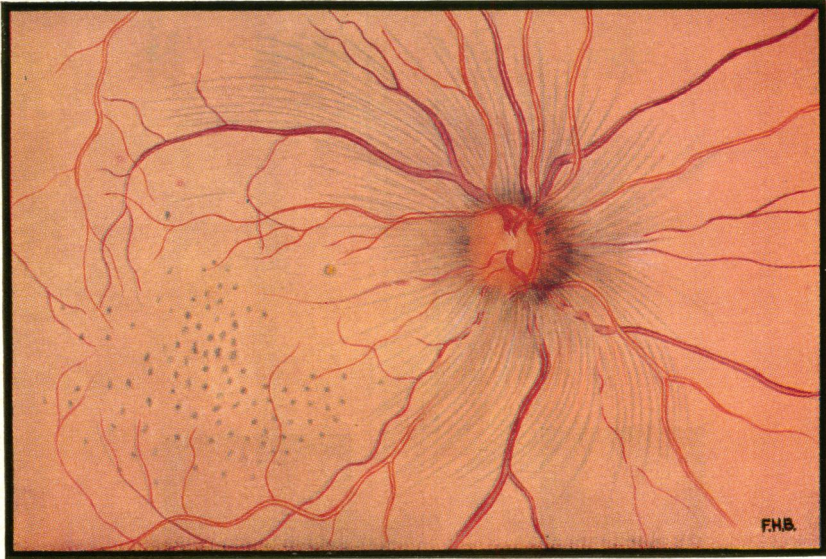


FIG. 4.—Right fundus of male African, 20 to 29-year age group (No. 474 Gangaran survey). Two microfilariae per microscope field at left iliac crest. Visual acuity in the right eye 6/9. Three dead microfilariae and eight fluffy opacities in cornea, one microfilaria in anterior chamber, early inflammatory iris pigment disturbance, but no keratic precipitates, flare, or synechia.

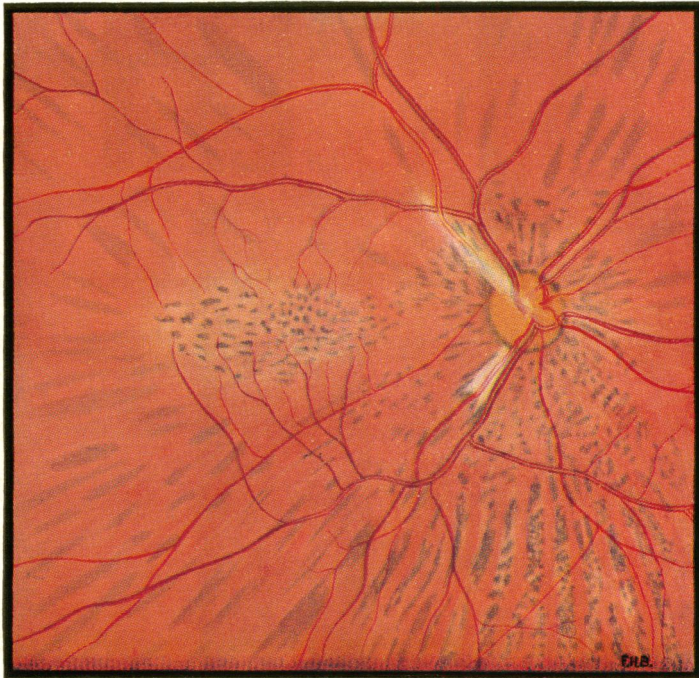

FIG. 5.—Right fundus of male African, 15 to 19-year age group (No. 494 Gangaran survey). Ten microfilariae per microscope field at left iliac crest, marked onchocercal depigmentation of shins. Visual acuity in the right eye 6/9. No signs of inflammation in anterior segment.



FIG. 6.—Left fundus of male African, 50 to 59-year age group (No. 527 Zagun survey). Three microfilariae per microscope field at left iliac crest. Visual acuity in the left eye perception of light. No signs of inflammation in anterior segment.

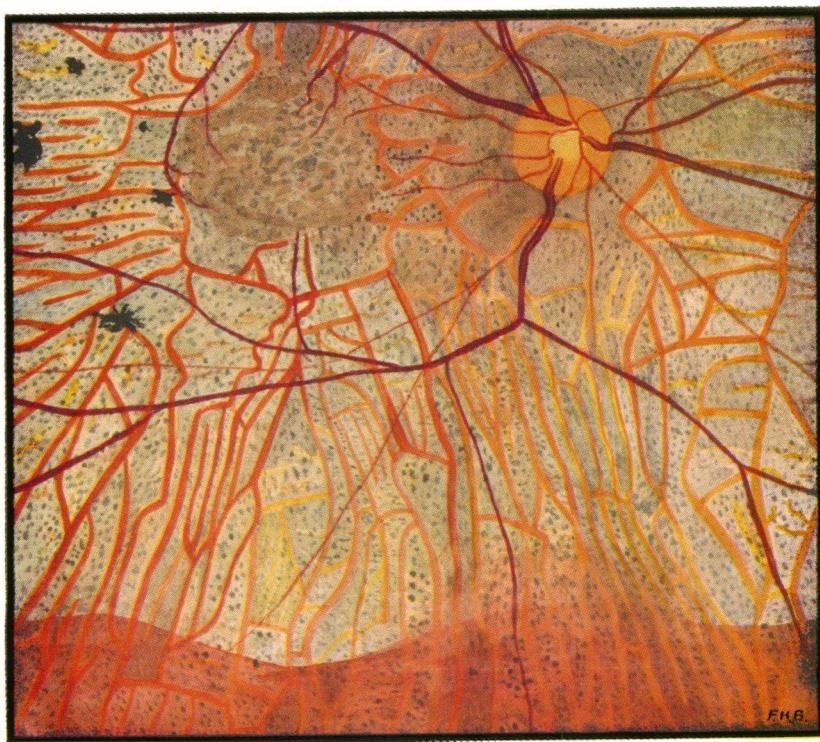

FIG. 7.—Right fundus of male African, 30 to 39-year age group (No. 206 Pyelanbirni survey). Three microfilariae per microscope field at left iliac crest. Visual acuity in the right eye 6/24. Sclerosing keratitis and gross inflammatory iris pigment disturbance.



FIG. 8.—Left fundus of male African, 40 to 49-year age group (No. 3360 Imbop survey). One microfilaria per field at iliac crest. No perception of light in left eye. No lesion of anterior segment.

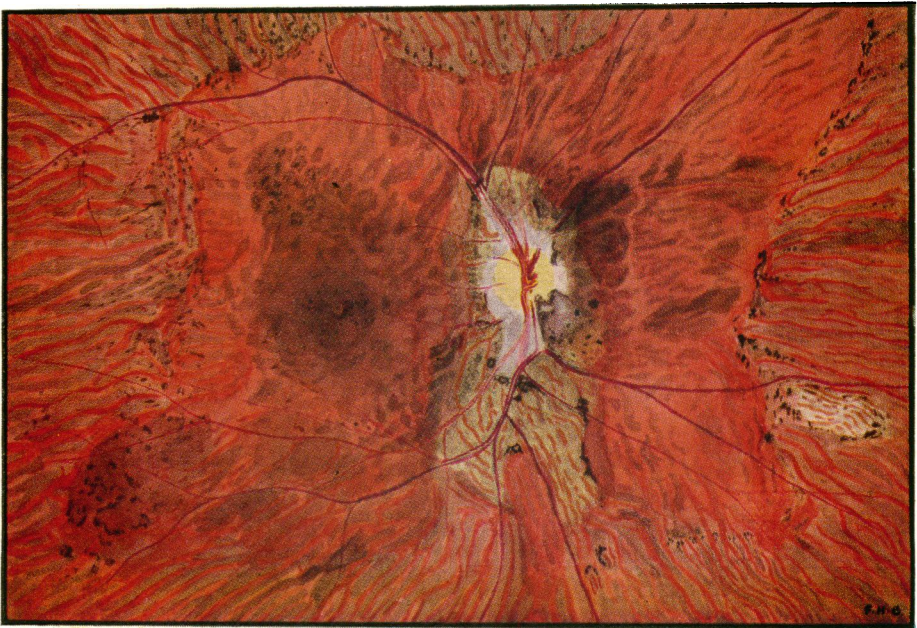

FIG. 9.—Right fundus of male African, 40 to 49-year age group (No. 3799 Kaduna clinic). Eight microfilariae per microscope field at left iliac crest. Visual acuity in the right eye hand movements only. Many fluffy opacities and sclerosing keratitis, many microfilariae in anterior chamber, inflammatory iris pigment disturbance.

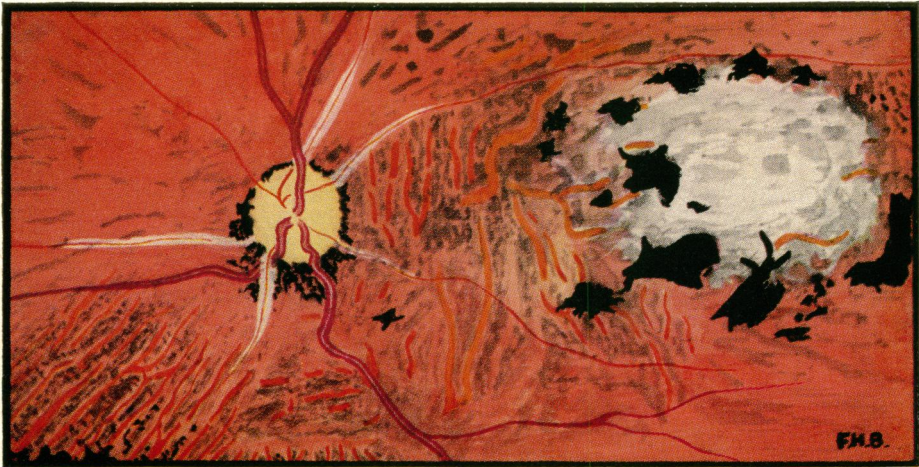

FIG. 10.—Left fundus of male African, 20 to 29-year age group (No. 551 Gardamna survey). Seven microfilariae per microscope field at left iliac crest. Visual acuity in the left eye hand movements only. Five fluffy corneal opacities, one microfilaria in anterior chamber, inflammatory iris pigment disturbance.

Further Epidemiological and Clinical Evidence

The following facts indicate a close association between inflammatory choroidal sclerosis and onchocerciasis:

- (a) The lesion is universally associated with onchocerciasis (d'Haussy and others, 1958).
- (b) The incidence of the lesion is directly related to the incidence of onchocercal infection in village communities of Northern Nigeria (Budden, 1955, 1958).
- (c) In villages where onchocerciasis is endemic I have found microfilariae more common in the cornea and anterior chamber of eyes presenting choroidal sclerosis than in eyes with normal fundi in the same age group.
- (d) The lesion tends to be more severe in the more heavily infected.

In contradistinction to Rodger's evidence, my investigations show that:

- (a) The "degenerative" and "exudative" lesions are not as distinct as Rodger suggests. At one extreme, when infection is low and the inflammatory reaction mild, a widespread choroidal sclerosis may be produced in the absence of gross retinal pigment disturbance. This has been likened in appearance to Sorsby's familial choroidal sclerosis (Choyce, 1958). At the other extreme a patch of focal choroiditis may be seen in heavily infected patients. Most lesions lie between these extremes, and focal choroiditis is usually superimposed on choroidal sclerosis.
- (b) The incidence of "degenerative" lesions is not related to low vitamin A intake. The lesions are in fact common in some places where there is a high consumption of vitamin A in the diet (*e.g.* in the Southern Cameroons).
- (c) Vitamin A therapy does not produce a significant improvement in visual acuity in these patients.

No familial pattern has been demonstrated in support of Choyce's evidence. Moreover, although the clinical fundal appearance, especially in light infections, may occasionally simulate appearances seen in the abiotrophies described by Sorsby (1939), Sorsby and Crick (1953), Sorsby and Davey (1955), Sorsby, Mason, and Gardener (1949), the full clinical picture is different (Budden, 1958; d'Haussy, 1960).

Further Histological Evidence

There have been many histological reports on the choroidal lesion in addition to those already quoted (*e.g.*, Hissette, 1932; Semadeni, 1943; Lavier, Lagraulet, and d'Haussy, 1956; Offret, Lagraulet, and d'Haussy, 1958; d'Haussy, Rit, and Lagraulet, 1958; Lagraulet, 1958, 1960; personal communications on eyes submitted to Schofield in 1956 and to Lagraulet in 1958). The finding common to these reports was round cell infiltration of the choroid, often most marked around the vessels, with associated periarteritis and sometimes endarteritis. Vascular sclerosis had developed in

many eyes. The overlying retinal pigment epithelium and outer layers of the retina showed degenerative changes. Microfilariae were not usually found in the choroid. However, Hissette (1932) states that microfilariae are found in the choroid, Bryant (1935) states that they are found in the choroid of patients with coincident onchocercal keratitis, and Rodger (1960) found them in some of his sections of the choroid. One of my male patients with early inflammatory choroidal sclerosis, whose age was estimated between 30 and 40 years, died after a surgical operation whilst the ocular lesions were still active. Ashton (personal communication, 1958) examined the eyes from this patient and found "two microfilariae in the choroid in relation to the round cell infiltration".

Discussion of Uveal Lesions

Koch's postulates have not been satisfied and it is just conceivable that some factor other than onchocerciasis is responsible for the lesions. However the epidemiological, clinical, and histological evidence quoted above indicates a cause and effect relationship between onchocerciasis and inflammatory choroidal sclerosis. There is parallel evidence for the iris lesions. The possibility that some uveal lesions attributed to onchocerciasis (particularly uncommon lesions, *e.g.* choroidal sclerosis with minimal massing of retinal pigment, and focal choroiditis) may be due to other causes must be remembered during clinical investigation and when interpreting histological material.

The factor immediately responsible for uveal lesions is not known. A circulating toxin or local liberation of toxin from dead microfilariae have been suggested. It is difficult to decide which is responsible. The presence of microfilariae in the eye usually reflects a high concentration of microfilariae in the body (Kershaw, Duke, and Budden, 1954) and probably also a high concentration of circulating toxin. Thus the association of local microfilariae with uveal lesions does not prove that they are causal. On the other hand, the absence of microfilariae at the time of clinical examination or excision does not prove that the uveal lesions were not initiated by the local presence of microfilariae. It must be remembered that microfilariae tend to disappear from the eye in burnt-out cases (Kershaw and others, 1954).

The reported histological findings in onchocercal patients presenting choroidal changes may be classified as:

- (a) Fibrosis of the stroma with obliteration of vessels but no inflammatory cells;
- (b) Round-cell infiltration of the stroma associated with varying degrees of perivascular inflammation and vascular sclerosis;
- (c) Focal exudative choroiditis as described by Rodger (1960).

The first finding is associated with light infection and the third with heavy infection; the second is the most usual.

When interpreting these histological differences it must be remembered that, not only were they associated with differences in clinical appearance which can be broadly related to differences in intensity of infection, but also that some material was collected during an active inflammatory phase whilst other material was collected during a late phase when inflammation may well have subsided. In particular, material falling into group (*a*) above may have been collected in a burnt-out phase.

Although it is convenient to describe the mild and severe uveal lesions separately, it should not be assumed that they are necessarily produced by different aetiological factors. Clinically and histologically one sees many gradations between the extremes and this suggests that they may be due to the same factor.

The commonest lesions, *i.e.* inflammatory iris pigment disturbance and inflammatory choroidal sclerosis, are characteristically widespread insidious inflammations not associated with clinical exudate. The lesions might well result from the peculiarly long-standing, low-grade inflammatory reaction that would be expected in response to the persistent presence of microfilarial toxin over many years (the toxin might be circulating or produced locally by microfilariae). The less common exudative lesions found in heavy infections may well result from more intense reaction to a higher concentration of toxin. On the other hand, Rodger believes that the "exudative" and "degenerative" lesions in the choroid are produced by different factors, although he draws no parallel distinction in the anterior uvea.

To sum up, lesions of both the anterior and posterior uvea, whether mild or severe, may be produced in the same way, *i.e.* by reaction to onchocercal toxin liberated locally or at a distance. This simple explanation may well be correct but reference is made to alternative suggestions.

Lens

Cataract.—The incidence is higher in villages where onchocerciasis is endemic (99 cataracts in 2,106 eyes) than in villages where it is not endemic (19 cataracts in 763 eyes). However, the cataracts seen in infected persons are usually of the senile type and complicated posterior cortical cataract is uncommon. It seems that onchocercal infection favours the development of the senile type of lens sclerosis.

Optic Nerve

(1) **Consecutive Optic Atrophy.**—This is associated with choroido-retinal lesions. It is illustrated in Ridley's fundus painting (1945, Plate III) and in Figs 6 and 7.

(2) **Papillitis.**—I have seen a number of young adults presenting with papillitis (Fig. 4) and heavy infection of the head region with microfilariae. The disc in these cases was hyperaemic and its margins blurred, the veins were dilated, and the surrounding retina was also oedematous. In my series swelling of the nervehead was never gross and no exudate or haemorrhage was seen around the disc. However, the gross post-neuritic optic atrophy commonly seen suggests that severe papillitis may occur.

(3) **Post-neuritic Atrophy.**—This is common. Although most cases are associated with choroido-retinal lesions, the presence of a neuritic element is obvious from the appearance of the disc margin (Figs 8, 9, and 10).

(4) **Primary Optic Atrophy.**—An atrophy which appears to be primary, for it is not associated either with choroido-retinal lesions or with signs of previous inflammation of the nervehead, is less common than the other types of atrophy. However, the incidence is significantly higher where onchocerciasis is endemic than in nearby villages where the disease is not endemic. I suspect this lesion is produced by perivascular onchocercal inflammation interfering with the blood supply to the optic nerve.

Retinal Vessels

(1) **Sheathing of Retinal Blood Vessels** (Sarkies, 1952, p. 87; Figs 5, 8, 9, 10).—Arteries are more commonly involved than veins. The sheath may extend up to three disc diameters beyond the disc. The lesion was found in 28 per cent. of fundi presenting choroido-retinal lesions.

(2) **Narrowing of Retinal Vessels.**—This is associated with sheathing and may also be marked whenever retinal atrophy is advanced (Figs 6 and 7).

Differential Diagnosis

Probably none of the lesions described is specific to onchocerciasis, and all may be simulated by lesions produced by other causes. However, the incidence of these lesions is high amongst sufferers from onchocerciasis, and the incidence of similar lesions in communities not exposed to onchocerciasis is low (Budden, 1958). Therefore the finding of any of these lesions in a person exposed to onchocercal infection should arouse the suspicion of ocular onchocerciasis. If onchocercal infection is confirmed by a positive skin snip or suggested by other ocular signs, dermal signs, subcutaneous nodules, a positive Mazotti test, a positive skin antigen test, or high eosinophilia (where other causes can be excluded), the diagnosis is strengthened. A knowledge of the epidemiology (Budden, 1956) and natural history (Budden, 1957) is of assistance in arriving at a probable diagnosis. For example, if a patient resident in an intensely infected area presented quiescent sclerosing keratitis and uveitis with negative skin snips, a diagnosis of ocular

onchocerciasis would be reasonable in an elderly person but unreasonable in a child or young adult.

Summary

The ocular lesions associated with onchocerciasis are described and illustrated; their aetiology and differential diagnosis are discussed.

REFERENCES

- BRYANT, J. (1935). *Trans. roy. Soc. trop. Med. Hyg.*, **28**, 523.
 BUDDEN, F. H. (1955). *Brit. J. Ophthalm.*, **39**, 321.
 ——— (1956). *Trans. roy. Soc. trop. Med. Hyg.*, **50**, 366.
 ——— (1957). *Brit. J. Ophthalm.*, **41**, 214.
 ——— (1958). *Trans. roy. Soc. trop. Med. Hyg.*, **52**, 500.
 CHOYCE, D. P. (1958). *Ibid.*, **52**, 112.
 CLARK, W. B. (1947). *Trans. Amer. ophthal. Soc.*, **45**, 461.
 D'HAUSSY, R. (1960). Lectures to Training Course on "Ophthalmological Aspects of Onchocerciasis", at Bamako (August, 1958), p. 157. World Health Organization, Geneva.
 ——— and seven others (1958). Letter to *Lancet*, **2**, 960.
 ———, RIT, J. M., and LAGRAULET, J. (1958). *Méd. trop.*, **18**, 340.
 HISSETTE, J. (1932). *Ann. Soc. belge Méd. trop.*, **12**, 433.
 ——— (1938). *Amer. J. trop. Med.*, **18**, Suppl., p. 58.
 KERSHAW, W. E., DUKE, B. O. L., and BUDDEN, F. H. (1954). *Brit. med. J.*, **2**, 724.
 LAGRAULET, J. (1958). *Bull. Soc. franç. Ophtal.*, **71**, 266.
 ——— (1960). Lecture to Training Course on "Ophthalmological Aspects of Onchocerciasis" at Bamako (August, 1958), p. 143. World Health Organization, Geneva.
 LAVIER, G., LAGRAULET, J., and D'HAUSSY, R. (1956). *Bull. Soc. Path. exot.*, **49**, 434.
 OFFRET, G., LAGRAULET, J., and D'HAUSSY, R. (1958). *Bull. Soc. Ophtal. Fr.*, p. 110.
 RIDLEY, H. (1945). "Ocular Onchocerciasis", *Brit. J. Ophthalm.*, Monograph Suppl. 10. Pulman, London.
 RODGER, F. C. (1957). *Brit. J. Ophthalm.*, **41**, 544.
 ——— (1958). *Ibid.*, **42**, 21.
 ——— (1960). *Amer. J. Ophthalm.*, **49**, 560.
 SARKIES, J. W. R. (1951). *Lancet*, **1**, 1205.
 ——— (1952). *Brit. J. Ophthalm.*, **36**, 81.
 SEMADINI, B. (1943). *Schweiz. med. Wschr.*, **73**, 75.
 SORSBY, A. (1939). *Brit. J. Ophthalm.*, **23**, 433.
 ——— and CRICK, R. P. (1953). *Ibid.*, **37**, 129.
 ——— and DAVEY, J. B. (1955). *Ibid.*, **39**, 257.
 ———, MASON, M. E. J., and GARDENER, N. (1949). *Ibid.*, **33**, 67.
 TOULANT, P., and BOITHIAS, R. (1954). *Arch. Ophtal.*, n.s., **14**, 567.