

## OCULOSPORIDIOSIS\* RHINOSPORIDIOSIS OF THE EYE

BY

E. T. KURIAKOSE

*Government Ophthalmic Hospital, Trivandrum, S. India*

RHINOSPORIDIOSIS is a local inflammatory condition, taking the form of a polypoid growth composed of granulation tissue. This is due to a fungus known as *Rhinosporidium seeberi* (first described by Seeber), which commences its life cycle as a parasite measuring  $8\mu$  but grows by nuclear division until it reaches a size of about 200 to 300  $\mu$  and contains over 4,000 nuclei, which form 16,000 spores. The mature parasite, now called *Sporangium*, presents a double-contoured chitinous envelope with a germinal spore through which the spores are discharged. Each spore subsequently develops into a separate *Sporangium*. This fungus occurring in the eye may give rise to oculosporidiosis, as its manifestations in the eye and its adnexa are more prevalent than that in the nose (rhinosporidiosis).

Rambo (1949) described the diagnosis and treatment of rhinosporidiosis of the lacrimal sac, but my own observations regarding this infection differ from those he describes. This article is therefore designed to illustrate the protean manifestations of oculosporidiosis in the eye and its adnexa in a series of 25 patients from the hospitals in Kerala.

**Sex Distribution.**—Males are more commonly affected. In the present series of 25 cases there were only two females.

**Age.**—One of the female cases was a girl aged 7 years, and the other was aged 61 years. Oculosporidiosis is rarely seen in females of child-bearing age, but in males it is noticed at all ages. In this series the youngest male was a boy aged 5 years and the oldest was 56 years. The largest number of conjunctival polypi were seen in males between ages of 10 and 25 years.

**Site.**—The conjunctiva, lacrimal sac, canaliculus, lid, and sclera are sites where this infection is observed (Table).

TABLE  
SITES OF INFECTION, BY SEX

Site	Total Cases		Females		Males	
	No.	Per cent.	No.	Per cent.	No.	Per cent.
Conjunctiva	16	64	1	4	15	60
Lacrimal sac	6	24	1	4	5	20
Canaliculus	1	4	0	0	1	4
Lid	1	4	0	0	1	4
Sclera	1	4	0	0	1	4
<b>Total</b>	<b>25</b>	<b>100</b>	<b>2</b>	<b>8</b>	<b>23</b>	<b>92</b>

\* Received for publication November, 7 1962.

*Conjunctiva.*—In sixteen cases the infection was manifested as a conjunctival polypus (Fig. 1), with a pedicular attachment to the conjunctiva varying in length from a few millimetres to a few inches. Two patients reported with a polypus 2 inches long protruding from the palpebral fissure. In two cases the polypus was attached to the bulbar conjunctiva, in thirteen to the sulcus subtarsalis of either the upper or the lower conjunctiva, and in one to the upper fornix.

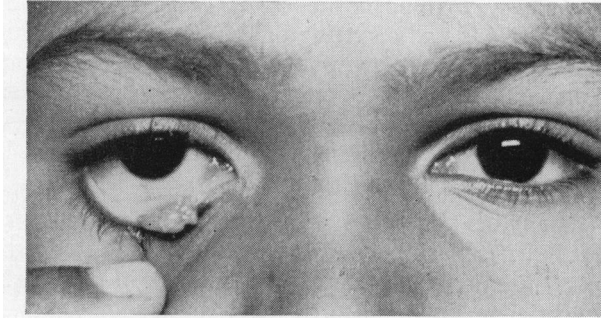


FIG. 1.—Granular oculosporidium polypus arising from the sulcus subtarsalis of the lower lid.

The polypi are usually long, slender, and fleshy with greyish-white granular spots scattered over the surface. These greyish-white spots which resemble small fish eggs are the mature *Sporangia*. These polypi tend to bleed at the slightest trauma, and when they are excised the bleeding from the pedicular attachment is fairly severe.

*Lacrimal Sac.*—In six cases the lacrimal sac was infected. All these patients reported with swelling of the lacrimal sac region which extended to a varying degree to the lower lid (Fig. 2).

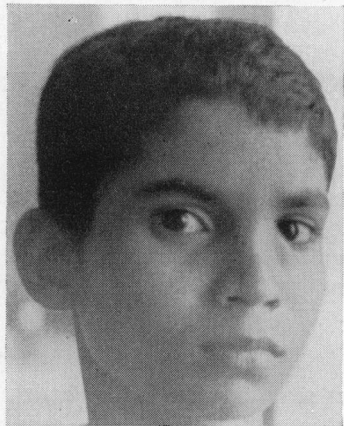


FIG. 2.—Oculosporidium infection of the lacrimal sac. The swelling is baggy and there is a history of bleeding from the nose.

Oculosporidiosis of the lacrimal sac presents the following peculiarities:

- (1) The swelling is soft and fluctuating to the touch.
- (2) It is painless.
- (3) There is often a history of bleeding from the nose.

- (4) Though there is regurgitation from the sac, the lacrimal passage was seldom completely obstructed as may be proved by syringing the lacrimal passages or by the fluorescein test.
- (5) Greyish-white spots are seen on the skin surface in long-standing cases.
- (6) The lesion recurs after operation.
- (7) There is severe bleeding during operation.
- (8) Infected tissue in and around the sac shows papillary growth.

My experience in treating rhinosporidiosis of the lacrimal sac differs from that of Rambo (1949). Incision and curetting of the lacrimal sac region and packing with sulphonamides gave only temporary relief, and the administration of penicillin or sulphonamides gave only temporary reduction in the swelling.

Oculosporidiosis of the lacrimal sac presents a difficult problem to the ophthalmic surgeons here, as recurrence is always the rule, and often a lacrimal fistula results, which is very resistant to further treatment.

*Canaliculus.*—One patient reported with a very tiny polypus protruding from the lower canaliculus. It was removed twice and recurred twice within a month. Finally the punctum was syringed with silver nitrate solution "3 gr. per oz." after removing the polypus from the canaliculus, but it is too soon to assess the result of this procedure.

*Lid.*—This may be the result of imperfect removal of a conjunctival polypus. In one patient both the upper and lower lids of the right eye were involved, and he also had rhinosporidiosis. The nasal polypus was removed three times by the E.N.T. surgeon, but after the third time did not recur. This patient has had the infection for the past 20 years, and has been seen by most ophthalmologists in South India from time to time and subjected to all sorts of treatment. The whole upper and lower lids and the bulbar conjunctiva are all infiltrated with the organism. He has a mechanical ptosis in the affected eye, for which infiltration of the levator palpebrae also may be responsible.

*Sclera.*—Involvement of the sclera is very rare, and the case included here was seen at the District Hospital, Ernakulam. The patient was a man of about 50 years, who had had a rhinosporidium polypus of the bulbar conjunctiva 2 years previously with two recurrences at the same spot at intervals of 6 months. When first seen he had severe chemosis of the bulbar conjunctiva in the lower half, and as this was not subsiding, an attempt was made to excise the chemotic conjunctiva. When the conjunctiva was dissected a circular punched-out hole (as if made by a 2 mm. trephine) was seen on the sclera where the recurrent rhinosporidium polypus was previously attached. The excess conjunctiva was excised and sutured, but 6 months later he reported with a localized circumscribed scleral staphyloma. The visual acuity is still 6/9, though the staphyloma may rupture at any time and cause the loss of the eye.

#### **Microscopical appearance**

A number of *Sporangia* of varying sizes may be seen in the oedematous sub-epithelial tissue. The larger ones contain a number of spores, some of which burst, and the surrounding tissue shows a granulomatous reaction with a number of giant cells and mononuclear cells (Fig. 3, opposite).

Attempts to culture this organism in the Medical College bacteriology department here have not yet been successful.

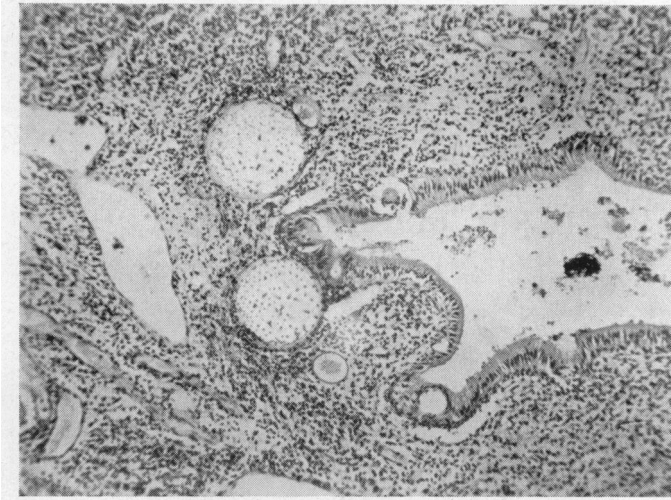


FIG. 3.—Photomicrograph of section, showing *Sporangia*, some of which are lying close to the surface epithelium.

### Treatment

Early excision of the oculosporidium polypus along with the surrounding conjunctiva followed by cauterization of the area with 2 per cent. silver nitrate solution is found to be the most satisfactory treatment of the conjunctival polypi. Recurrence is rare after excision and silver nitrate cautery. Complete excision is very difficult in lacrimal sac infections, especially because of the severe bleeding, but even here excision followed by washing the cavity with silver nitrate solution gives some improvement. After repeated excisions the swelling may disappear, leaving behind a lacrimal fistula which discharges a slimy mucoid fluid which is quite characteristic of this condition.

### Summary and Conclusions

*Sporidium* infection of the eye and its adnexa is more common than that of the nose, so that when this fungus infection occurs in the eye it should be called "oculosporidiosis".

The commonest site of infection is the conjunctiva, but the lacrimal passages, lid, and sclera may be involved.

Its granular appearance and tendency to bleed are the characteristics of this lesion. Males are more commonly affected than females.

No treatment can be claimed to be 100 per cent. effective, but excision followed by silver nitrate cautery is the best method so far discovered

I gratefully acknowledge my thanks to Dr. P. A. Velyudhan Pillai, Professor of Ophthalmology, for permitting me to study his cases and for assistance in the preparation of this article. My thanks are also due to Dr. Balaraman Nair, Pathology Department, Medical College, for making the pathological examinations and for assistance with the photomicrographs.

### REFERENCE

RAMBO, V. C. (1949). *Proc. All-India ophthal. Soc.*, **10**, 72.