

Tuberculous arthritis of the elbow joint: A case report

Ayten Yazıcı¹, Gökçen Kayan², Selçuk Yaylacı³, Mustafa Volkan Demir³, Engin Karakeçe⁴, Ali Tamer³, Oğuz Karabay²

Abstract

Tuberculous arthritis of the elbow joint is rare. A 57-year-old male patient presented with swelling, pain, and redness of the elbow. The symptoms first appeared one month ago; he was given antibiotic treatment after the diagnosis of septic arthritis at another center. The patient who did not improve with treatment was diagnosed with tuberculous arthritis according to the culture and was started on antituberculosis treatment. Tuberculous arthritis usually presents with chronic arthritis. However, it can also present in patients with septic arthritis.

Keywords: Tuberculosis, septic arthritis, elbow joint

Introduction

Tuberculosis is an airborne infectious disease. One-third of the world's population has tuberculosis, and approximately two million people die due to tuberculosis each year. There are approximately 30 million active tuberculosis cases worldwide. Although the lung is the primary tuberculosis involvement site, skeletal system involvement is seen in 1–3% of the patients. Vertebral involvement is most common in case of skeletal system involvement. The hip, knee, foot, elbow, hand, shoulder joints, and bursae may be involved. Skeletal system involvement of tuberculosis usually manifests as monoarthritis, but 10% of the patients may have polyarthritis. Tuberculosis of the upper limb is rare. Elbow joint involvement is observed in 1–5% of the patients with skeletal system involvement (1–5). We aim to present the case of a 57-year-old man who presented with septic arthritis to a clinic but who was diagnosed with tuberculosis of the elbow.

Case Presentation

A 57-year-old male patient was admitted to our clinic with complaints of pain, swelling, redness, and limitation of movement of his right elbow. His symptoms started two months ago. There was no history of trauma. The patient was admitted to the orthopedic clinic, and cefuroxime–axetil and naproxen sodium treatment was started. Because of continued complaints, he was referred to our rheumatology outpatient clinic. There was pain, swelling, redness, and limitation of movement of his right elbow. His medical history revealed pulmonary tuberculosis (30 years ago). His familial history showed that his father had lung tuberculosis and lung cancer. His blood analysis was as follows: leukocyte count, 7400/mm³; platelet count, 372000/mm³; hemoglobin level, 12.1 g/dL; glucose level, 149 mg/dL; creatinine level, 0.6 mg/dL; alanine transaminase level, 18 IU/L; aspartate aminotransferase level, 22 IU/L; sodium level, 138 mmol/L; potassium level, 4.6 mmol/L; erythrocyte sedimentation rate, 105 mm/h; C-reactive protein level, 51 mg/L (normal range: 0–5); and rheumatoid factor level, 32.8 IU/mL (normal range: 0–20). Contraction in the elbow joint and erosive degenerative changes in the proximal ulna were seen in his direct elbow graphy. Bilateral sequelae changes in the apex of the lung were seen in his direct lung graphy. Changes in bone density, thickening of synovial structures, and contrast enhancement of the medullary bone marrow and effusion were seen on magnetic resonance imaging (MRI) of the elbow (Figure 1). A significantly increased joint fluid level was detected in the sonographic examination of the right elbow. Joint fluid aspiration was performed, and it was purulent. Acid-resistant and gram staining and cell count, culture, and mycobacterial culture were studied. Leukocytes were abundant in cell count. The acid-resistant staining was positive. Isoniazid, rifampicin, pyrazinamide, and ethambutol therapy was started with the diagnosis of tuberculous arthritis. On the fifth day of antituberculosis treatment, loss of color vision was detected, and ethambutol was replaced with streptomycin. Despite treating the tuberculosis, there was no clinical improvement, and the effusion and purulent appearance increased. New cultures were studied. On the eighth day of treatment, vancomycin was added to the antituberculosis treatment, with septic arthritis kept in mind. After orthopedic consultation, as the patient showed no improvement with antituberculosis treatment, drainage was performed. The diagnosis of tuberculous arthritis was confirmed when the mycobacterial culture was positive and *Mycobacterium tuberculosis* bacilli were stained from the culture on the 30th day of follow-up (Figure 2, 3). The patient was



1 Department of Internal Medicine, Division of Rheumatology, Kocaeli University School of Medicine, Kocaeli, Turkey

2 Clinic of Infection Diseases, Sakarya Training and Research Hospital, Sakarya, Turkey

3 Department of Internal Medicine, Sakarya Training and Research Hospital, Sakarya, Turkey

4 Department of Clinic Microbiology, Sakarya Training and Research Hospital, Sakarya, Turkey

Address for Correspondence:
Ayten Yazıcı, Department of Internal Medicine, Division of Rheumatology, Kocaeli University School of Medicine, Kocaeli, Turkey

E-mail: burakdefy@hotmail.com

Submitted: 30.07.2015

Accepted: 18.10.2015

Available Online Date: 01.02.2016

Copyright 2016 © Medical Research and Education Association

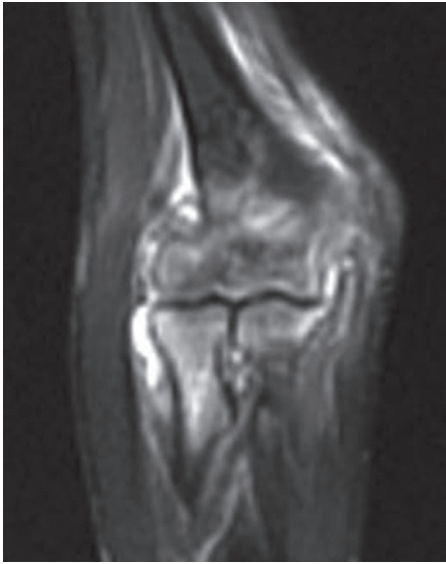


Figure 1. Elbow magnetic resonance imaging (MRI) Density change, marked contrast enhancement, changes in bone density, thickening of synovial structures, and contrast enhancement of the medullary bone marrow and effusion

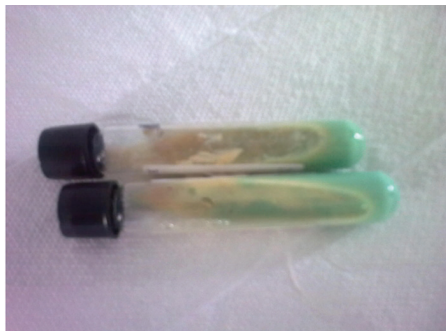

Figure 2. Positive mycobacterial culture

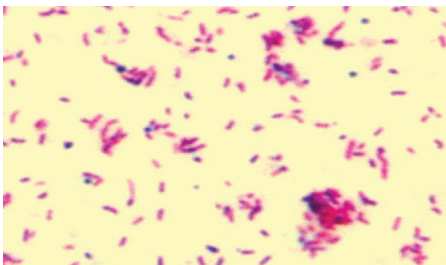


Figure 3. *Mycobacterium tuberculosis* bacilli

finally discharged with quadruple antituberculosis therapy. After two months, the patient had no complaint except limitation of elbow

motion. Informed consent was obtained from the patient.

Discussion

Musculoskeletal tuberculosis tends to be uncommon and accounts for around only 1–3% of all cases of tuberculosis. The spine is the most common site for musculoskeletal involvement, followed by the pelvis, hip and femur, knee and ribs. Elbow joint involvement is rarely reported in literature (4-7). Because of human immunodeficiency virus (HIV) infection, the number of osteoarticular tuberculosis patients has been increasing in recent years (1).

Osteoarticular tuberculosis is difficult to clinically diagnose (3, 5, 7, 8). The most important steps in the diagnosis of tuberculosis are clinical suspicion and good history. Symptoms are usually nonspecific. Edema, redness, warmth, pain, and limitation of motion can be seen (8, 9). Fever, malaise, anorexia, weight loss, night sweats, and tachycardia may also occur. Many patients have higher erythrocyte sedimentation, but this is not diagnostic (4, 7, 8).

The positivity of acid-resistant staining of the joint fluid and positivity of *M. tuberculosis* bacilli cultures are diagnostic. Despite the presence of tuberculosis infection, aspiration material is not stained or reproductive. In this condition, performing a biopsy is important for diagnosis (8, 9).

Radiological investigations include radiographs and MRI examinations; however, radiographic changes are not specific. Effusion and soft tissue edema can be seen early in the magnetic resonance imaging (MRI) examinations. Monitoring methods are not possible to separate patients with septic arthritis from those with joint tuberculosis (8, 9).

After the diagnosis of tuberculosis, treatment should be initiated very quickly and maintained for long. In total, 90–95% of the patients will recover if treatment is started in the early period (2, 7, 8, 9). There are indications for surgical debridement in the presence of intensive effusion, severe pain, limitation of joint movement, or drug-resistant (10).

Tuberculosis should be considered in the diagnosis of monoarthritis in developing countries. In patients with antibiotic-resistant septic arthritis, acid-resistant staining should be performed and *Mycobacterium* culture should be taken. The most important step is remembering tuberculous arthritis.

Ethics Committee Approval: N/A.

Informed Consent: Written informed consent was obtained from the patient.

Peer-review: Externally peer-reviewed.

Author Contributions: Concept - A.Y., G.K.; Design - A.Y., S.Y.; Supervision - A.T., O.K.; Materials - M.V.D., E.K.; Data Collection and/or Processing - A.Y., G.K.; Analysis and/or Interpretation - A.Y., G.K.; Literature Review - A.Y., G.K.; Writer - A.Y., S.Y.; Critical Review - A.Y., G.K.

Conflict of Interest: No conflict of interest was declared by the authors.

Financial Disclosure: The author declared that this study has received no financial support.

References

1. Golden MP, Vikram HR. Extrapulmonary tuberculosis: an overview. *Am Fam Physician* 2005; 72: 1761-8.
2. Ludwig B, Lazarus AA. Musculoskeletal Tuberculosis. *Dis Mon* 2007; 53: 39-45. [\[CrossRef\]](#)
3. Novatnack ES, Protzman NM, Kannagara S, Busch MF. Elbow mycobacterium tuberculosis in america. *J Glob Infect Dis* 2015; 7: 44-5. [\[CrossRef\]](#)
4. Jung SS, Lee MK, Lim SH, Kwon YM, Choi SS. Elbow pain proven to be tuberculous arthritis - A case report. *Korean J Anesthesiol* 2010; 58: 211-4. [\[CrossRef\]](#)
5. Domingo A, Nomdedeu M, Tomas X, Garcia S. Elbow tuberculosis: an unusual location and diagnostic problem. *Arch Orthop Trauma Surg* 2005; 125: 56-8. [\[CrossRef\]](#)
6. Rahman MS, Brar R, Konchwalla A, Sala MJ. Pain in the elbow: a rare presentation of skeletal tuberculosis. *J Shoulder Elbow Surg* 2008; 17: 19-21. [\[CrossRef\]](#)
7. Sagoo RS, Lakdawala A, Subbu R. Tuberculosis of the elbow joint. *JRSM Short Rep* 2011; 2: 17. [\[CrossRef\]](#)
8. Erdem H, Baylan O, Simsek I, Dinc A, Pay S, Koçoglu M. Delayed diagnosis of tuberculous arthritis. *Jpn J Infect Dis* 2005; 58: 373-5.
9. Tuli SM. General principles of osteoarticular tuberculosis. *Clin Orthop Relat Res* 2002; 398: 11-9. [\[CrossRef\]](#)
10. Wilkinson MC. Tuberculosis of the hip and knee treated by chemotherapy, synovectomy, and debridement. A followup study. *J Bone Joint Surg Am* 1969; 51: 1343-59.