

MALIGNANT MELANOMATA OF THE CHOROID*

MONTGOMERY MEMORIAL LECTURE, 1961

BY

J. FRANÇOIS

Ghent, Belgium

It is indeed an unusual honour to have been invited to give the Montgomery Memorial lecture. My gratitude goes to the president and Council of the Royal College of Surgeons in Ireland, as well as to the President, Council, and Members of the Irish Ophthalmological Society.

Although malignant melanomata of the uvea are relatively rare, they nevertheless constitute the majority of all malignant neoplasms of intra-ocular or peri-ocular localization. During the period 1950–1960, we had occasion to examine seventy such cases.

Bilateral cases are highly exceptional, only ten or twelve instances being found in the literature. The tumour can occur in both choroids, either simultaneously (Landesberg, 1896) or at an interval (Dixon, 1878, 6 months; Hirschberg, 1881, a year; Reese, 1951, 8 years). In some cases, the iris of one eye and the choroid of the fellow eye are affected (Shine, 1930; Cordes and Cook, 1949).

Familial occurrence is not uncommon. Pflugst and Graves (1921), Reese (1951), and Paton and Thomas (1959) saw a malignant melanoma of the choroid or of the ciliary body in brothers and sisters. Irvine (1957) observed a malignant melanoma of the bulbar conjunctiva in a man whose sister showed a malignant melanoma of the choroid. Silcock (1892) demonstrated dominant transmission from grandfather to mother to daughter. Davenport (1927) described seven cases involving three generations.

Microscopical Examination

Metastases.—Uveal malignant melanomata usually metastasize *via* the blood vessels. In some cases histological examination shows small groups of tumour cells infiltrating the lumen of the blood vessels. Metastasis *via* the lymph vessels is, however, also possible.

Microradiographic studies after thorotrast injection (Figs 1 and 2, opposite) have shown that the tumour grows by concentric layers around a central nucleus which degenerates very quickly (François, Neetens, and Collette, 1963). The cortical region of the tumour is the most richly vascularized; there is a very dense capillary network with blood sinuses. The sudden passage without

* This paper summarizes the lecture and gives essentially the results of our own research, made in collaboration with Dr. Rabaey, Dr. Neetens, and Dr. Hanssens.

FIG. 1.—Microradiograph of malignant melanoma of the choroid after thorotrast injection. Hilar region and base of the tumour, showing heavy vascularization.

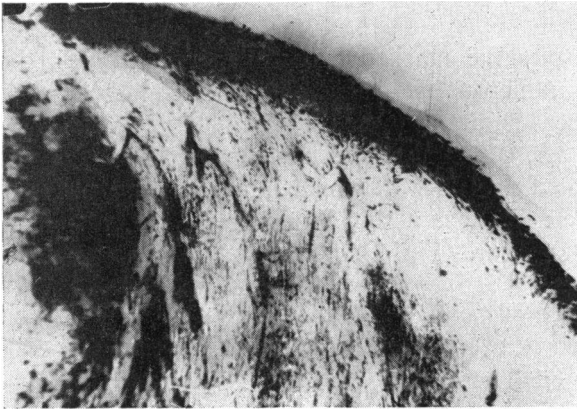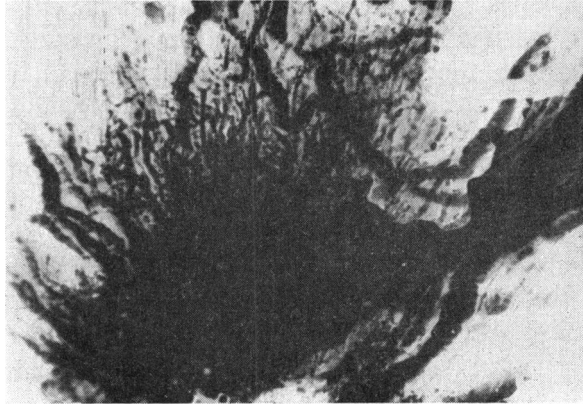


FIG. 2.—Microradiograph of malignant melanoma of the choroid after thorotrast injection. Cortical region. Zone of necrosis with an interruption of the vessel walls.

transition between the sinuses and the capillaries produces a slackening of the circulation, which explains the degeneration of the oldest and the most central layers. In the central and intermediary zones there exist a canalicular network and blood lakes without endothelium, so that blood often circulates freely among the tumour cells. This fact explains the frequency of blood-borne dissemination.

It is also well known that cells from a malignant melanoma penetrate the blood-vessel walls very early (Wintersteiner, 1906; Fuchs, 1917; Wätzold and Goytoku, 1928; Papolczy, 1937; Reese, 1951). It is therefore probable that—early in the disease, before enucleation—the whole body is deluged with tumour cells. Why then, do not all patients show metastases? Are there certain defensive substances in the body which restrain the metastatic cells for a period of years, and does this apparent immunity finally diminish in some cases with ageing of tissues, resulting in the appearance of metastatic lesions? Nobody knows (Dunphy, 1957).

Histological Structure.—These melanomata are highly polymorphous. Pigment formation is perhaps the only constant characteristic.

Reese and Ehrlich (1958) studied tissue cultures of uveal melanomata and concluded that they all arose from Schwann cells. Their cultures showed a growth ranging from a branching polygonal pigment-bearing cell of the stromal melanoblast type, to long bipolar spindle-shaped cells, with or without pigment. The latter had the characteristics of Schwann cells. All gradations between these two extremes can be found, and regardless of the cell type of the tumour cultured, transition is seen from one cell type to the other.

A classification of practical clinical value and prognostic significance was presented by Callender, Wilder, and Ash (1942 a, b), who divided uveal malignant melanomata into groups according to three histological criteria, which have also a prognostic value:

- (1) Cell type (spindle, fascicular, epithelioid, mixed, and necrotic)
- (2) Reticulin concentration
- (3) Pigment concentration.

Electron Microscopy.—Despite the marked differences in cell types, the electron microscope reveals numerous similar characteristics indicating a common origin (François, Rabaey, and Lagasse, 1959).

The nuclei are generally large, of homogenous structure, and surrounded by a sometimes deeply-indented double wall which in various views shows unmistakable gaps. The nucleoli are as a rule large, irregular and, nearly always, of a typical reticular structure (Fig. 3).

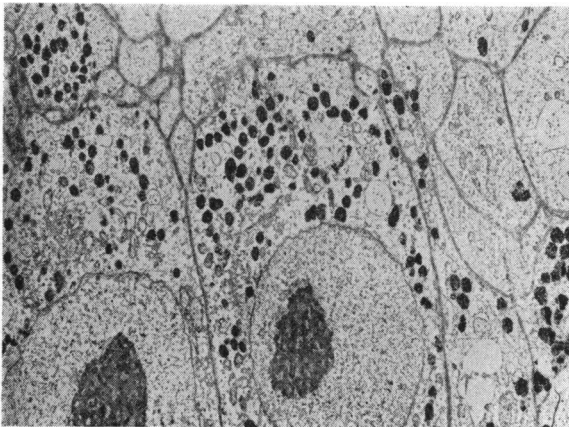


FIG. 3.—Electron-microscopic examination.

The cytoplasm generally contains numerous mitochondria. These are sometimes enlarged, showing irregular swelling and loss of internal structure. The Golgi apparatus varies in size but is usually hypertrophic.

The endoplasmic reticulum is well developed. The membranes of the ergastoplasm are of the rugose type, and here and there embrace large spaces. In various cells there are corkscrew formations of ergastoplasm, or concentric lamellae in the centre of which a dense granular mass is seen. In

some cells the development of rugose lamellae is so marked that the cytoplasm is almost completely filled with them. Surprisingly, these cells never contain pigment granules.

The form in which the melanin-bearing elements occur in the tumour cells is widely diverse.

In some tumours, numerous cells contain many small pigment granules with marked opacity to the electron beam. The finely granular material of which these pigment granules consist shows marked differences in density. The small dark granules may be round but sometimes show an unmistakably linear arrangement. The width of such bands is approximately the same as that of the septa in the mitochondria. Some of the pigment granules are surrounded (at least partly) by a fine smooth membrane.

In other cases the tumour cells show an entirely different arrangement of the pigment. The cytoplasm then contains very large, peculiar, more or less well-defined round areas, around which a fine smooth membrane is occasionally visible. In these areas we find numerous dark melanin-bearing masses (Fig. 4), generally of about the same size as normal mitochondria. These dark granules are found in a more or less clear substance which is structurally quite different from the cytoplasm. In the same tumour or in the same cell, dark melanin-bearing granules may also be found scattered in the cytoplasm. The peculiar linear arrangement of the melanin is again seen in these cases.

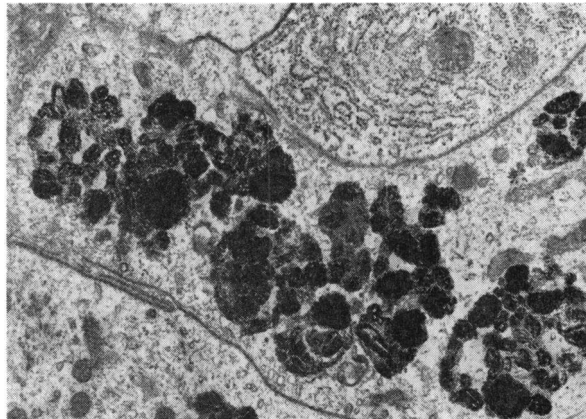


FIG. 4.—Electron-microscopic examination. Numerous dark melanin-bearing masses.

It should be mentioned that none of the uveal sarcomata examined contained particles with the characteristics of a virus such as are seen in various types of transferable tumours.

Prognosis.—This depends not only on the cell type, the reticulin concentration, and the pigment content, but also on the *basophilia of the tumour*. The basophilia of a tissue can be measured by quantitative determination of the absorption of basic staining substances (methylene blue; François and Rabaey, 1953).

The basophilia of malignant melanomata of the uvea (Figs 5 and 6) is more conspicuous than that of normal tissues. It varies widely from one tumour to another and is directly proportional not to the pigment content but to the nucleic acid concentration of the cell. The latter is known to be directly correlated with the growing capacity of the tissue; basophilia thus supplies information regarding the malignancy and prognosis of malignant melanomata (François and Rabaey, 1953).

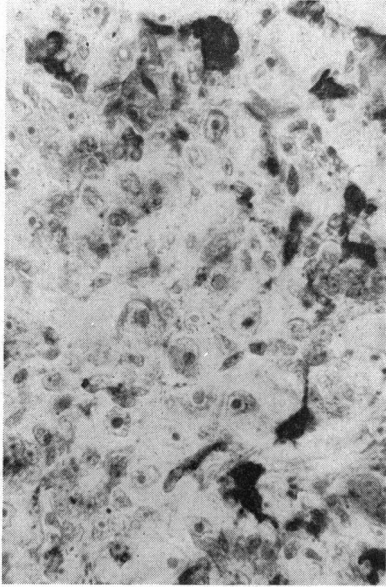


FIG. 5.—Tumour stained by methylene blue, showing conspicuous basophilia.

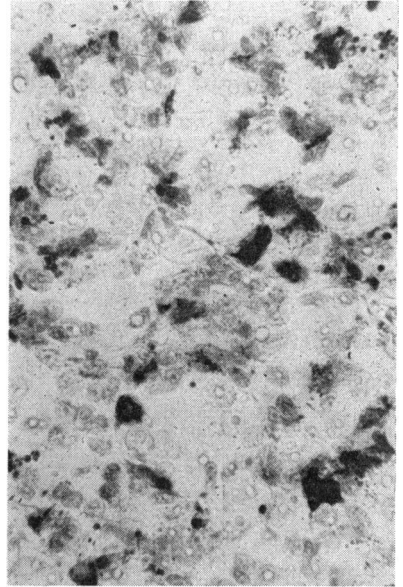


FIG. 6.—Same tumour stained by methylene blue and treated by ribonuclease. The cytoplasm has disappeared.

Diagnosis.—Because metastases may occur while the tumour is still in its earliest stage, early diagnosis is of paramount importance (Duke-Elder, 1947), but malignant melanomata of the choroid are sometimes overlooked or diagnosed very late. Neame and Ali Khan (1925) made microscopic examinations of 402 eyes enucleated for glaucoma; forty (10 per cent.) of these eyes contained malignant melanomata, and in fifteen (4 per cent.) there had been no suspicion of a tumour.

Makley and Teed (1958), in a series of 1,000 cases of intra-ocular malignant melanoma, found 212 eyes with opaque media, in 113 of which the tumour had been unsuspected.

The non-recognition of the tumour is usually due to the fact that the patient is seen at a late stage, when complications such as detachment of the retina, glaucoma, iridocyclitis, haemorrhage into the anterior chamber or into the vitreous, corneal opacity, etc., have already occurred.

The following should always be borne in mind :

(1) An eye lost as a result of intra-ocular hypertension often masks a malignant melanoma. In the unsuspected cases the incidence of glaucoma is very high (88 per cent. according to Makley and Teed, 1958).

(2) A malignant melanoma, if of the necrotic type, may produce inflammatory processes and cause iridocyclitis and opacification of the media.

(3) Detachment of the retina without tears is always suspicious.

(4) Melanomata can be found even in phthisical eyes (degeneration or necrosis of a malignant melanoma with inflammation).

Consequently, a painful blind, atrophic, or glaucomatous eye should always be removed (Neame and Ali Khan, 1925; Chance, 1934; Terry, 1939).

Only histological examination can establish with certainty whether or not a malignant melanoma is present. No clinical symptom is enough, at least in the early stages. Various special examinations may be made by scleral transillumination, measurement of the radioactive phosphorus uptake, and especially biomicroscopy and retro-illumination.

(1) *Biomicroscopy* (Pischel, 1949; Busacca, Goldmann, and Schiff-Wertheimer, 1957).—In the initial stage the retina is normal and translucent, so that the beam of light directly reveals the opaque irregularly-pigmented choroid mass. The vitreous is normal. In more advanced cases the retina is detached. The light, which passes not only through the retina but also through the subretinal fluid, is arrested by the opaque tumour.

Even in more advanced cases, the tumour margin is usually still clearly defined from the normal choroid. The retina shows degenerative changes: irregular surface with cystic degeneration, haemorrhages, a whitish formation of connective tissue between the detached retina and the tumour, small retinal folds and, in case of a macular tumour, cystic oedema of the macula.

(2) *Indirect Biomicroscopy* (Fig. 7).—This is the most useful aid to correct diagnosis. With indirect light the tumour margin can be well visualized, the tumour appearing black.

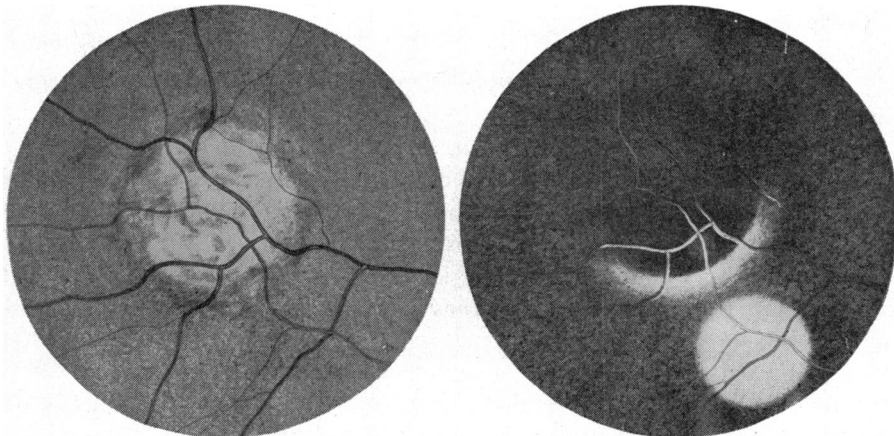


FIG. 7.—Retro-illumination (after Reese and Ehrlich, 1958).

(3) *Retro-illumination*.—With the aid of an ophthalmoscope (Reese and Jones, 1957), the lesion may be examined through a well-dilated pupil, while a very bright light is directed below its lower margin. It is important to move the head and the light until the rays reflected from the choroid reach the examiner's eye. If the lesion is a melanoma, the reflected rays do not penetrate it, and the margin is seen as an opaque or dark zone. Light is transmitted by this method in inflammatory processes, macular degeneration, metastatic carcinoma, serous detachment of the retina, and haemangioma of the choroid.

Treatment

Enucleation.—This is always the safest treatment of malignant melanomata of the choroid.

Radiotherapy.—This is never able to arrest the primary growth and is of no value as a postoperative prophylactic measure. It has even been suggested that metastases occur earlier after irradiation (Burch and Camp, 1943).

When the lesion is still small, and particularly when there is little or no vision in the fellow eye, conservative methods may be resorted to.

Trans-scleral Diathermo-coagulation (Weve, 1939).—This may be used in small lesions, particularly those of peripheral localization. Weve treated seventeen patients in this way, only two of whom died as a result of metastases within five years.

Photo-coagulation.—This is less difficult in application and can be repeated as often as necessary, but for this technique certain requirements must be fulfilled:

- (i) There should be no detachment of the retina.
- (ii) The tumour should be not more than 5 or 6 disc diameters in width and not more than 9 or 10 dioptres thick.
- (iii) In all cases, the tumour must first be isolated by coagulating around it; only after this can the tumour itself be coagulated.

Results of Photo-coagulation

We have treated thirty cases during the past 4 years. In 22 cases (70 per cent.) apparently complete clinical cures were obtained (in seven for more than 3 years). In sixteen cases coagulation had to be done two to five times, and in six cases six to ten times.

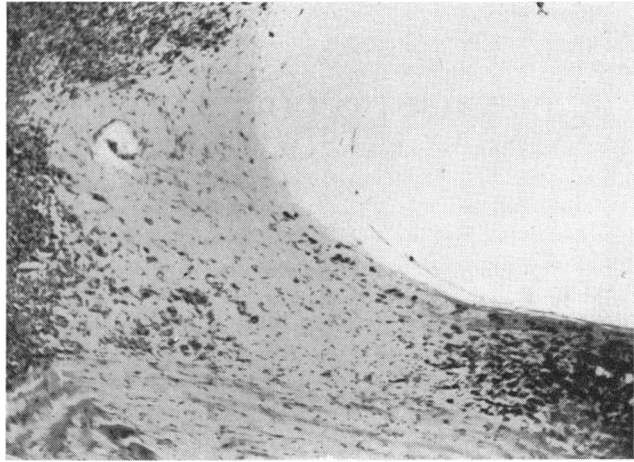
Three cases (10 per cent.) developed a local recurrence at the periphery of the lesion originally coagulated. In one (Fig. 8, opposite) the primary tumour had been completely destroyed, but in the transitional zone between the site of the primary tumour and the relapse, small foci of tumour cells are seen (François and Hanssens, 1961); the question arises whether these cells were overlooked at the time or whether they have arisen from a recurrence. In any case this observation demonstrates that coagulation must be extended considerably beyond the visible limits of the tumour if recurrences are to be avoided.

In three cases we had diffuse vitreous haemorrhages which did not clear up, so that we were obliged to remove the eye. This haemorrhage never

FIG. 8.—Malignant melanoma of the choroid.

Right, primary tumour completely destroyed by photocoagulation.

Left, recurrence. The transitional zone shows several tumour cells.



appeared immediately after the first photocoagulation, but only after five or six coagulations, so that it is very difficult to say what can be done to avoid it.

Enucleation was necessary in one case because of progressive growth of the tumour, and in another for a retinal detachment.

It is too early to give final conclusions regarding this method of treatment, as we are still at the experimental stage.

REFERENCES

- BURCH, F. E., and CAMP, W. E. (1943). *Trans. Amer. Acad. Ophthalm.*, **47**, 335.
- BUSACCA, A., GOLDMANN, H., and SCHIFF-WERTHEIMER, S. (1957). "Biomicroscopie du corps vitré et du fond de l'oeil". Masson, Paris.
- CALLENDER, G. R., WILDER, H. C., and ASH, J. E. (1942a). *Ibid.*, **46**, 223.
- (1942b). *Amer. J. Ophthalm.*, **25**, 962.
- CHANCE, B., (1934). *Ibid.*, **17**, 48.
- CORDES, F. C., and COOK, R. D. (1949). *Trans. Amer. ophthalm. Soc.*, **47**, 80.
- DAVENPORT, R. C. (1927). *Brit. J. Ophthalm.*, **11**, 443.
- DIXON, L. S. (1878). *Trans. Amer. ophthalm. Soc.*, **2**, 432.
- DUKE-ELDER, S. (1940). "Text-book of Ophthalmology", vol. 3, p. 2507. Kimpton, London.
- DUNPHY, E. B. (1957). *Amer. J. Ophthalm.*, **44**, 313.
- FRANÇOIS, J., and HANSENS, M. (1961). *Bull. Soc. belge Ophtal.*, No. 128, p. 292.
- , NEETENS, A., and COLLETTE, J. M. (1963). *Ophthalmologica (Basel)*, **195**, 257.
- and RABAËY, M. (1953). *Bull. Soc. belge Ophtal.*, No. 104, p. 301.
- , and LAGASSE, A. (1959). *Ophthalmologica (Basel)*, **137**, 65.
- FUCHS, E. (1917). *v. Graefes Arch. Ophthalm.*, **94**, 43.
- HIRSCHBERG, J. (1881). *Arch. Ophthalm. (N.Y.)*, **10**, 55.
- IRVINE, A. R. (1957). *Trans. Pacif. Cst oto-ophthal. Soc.*, **38**, 115.
- LANDESBERG, M. (1869). *v. Graefes Arch. Ophthalm.*, **15**, pt 1, p. 210.
- MAKLEY, T. A., and TEED, R. W. (1958). *Arch. Ophthalm. (Chicago)*, **60**, 475.
- NEAME, H., and ALI KHAN, W. (1925). *Brit. J. Ophthalm.*, **9**, 618.
- PAPOLCZY, F. VON (1937). *Klin. Mbl. Augenheilk.*, **99**, 518.
- PATON, D., and THOMAS, L. B. (1959). *A.M.A. Arch. Ophthalm.*, **62**, 645.
- PFINGST, A. O., and GRAVES, S. (1921). *Arch. Ophthalm. (N.Y.)*, **50**, 431.
- PISCHEL, D. K. (1949). *Amer. J. Ophthalm.*, **32**, 68.
- REESE, A. B. (1951). "Tumors of the Eye". Hoeber, New York.
- and EHRLICH, G. (1958). *Amer. J. Ophthalm.*, **46**, no. 5, pt 2, p. 163.
- and JONES, I. S. (1957). *Arch. Ophthalm. (Chicago)*, **58**, 477.
- SHINE, F. W. (1930). *N.Y. Eye Ear Inf. Clin. Rep.*, **1**, 31.
- SILCOCK, A. Q. (1892). *Brit. med. J.*, **1**, 1079.
- TERRY, T. L. (1939). *Arch. Ophthalm. (Chicago)*, **22**, 989.
- WÄTZOLD AND GYOTOKU, K. (1928). *v. Graefes Arch. Ophthalm.*, **120**, 209.
- WEVE, H. (1939). *Trans. ophthalm. Soc. U.K.*, **59**, 43.
- WINTERSTEINER, H. (1906). *Ber. ophthalm. Ges.*, **33**, 345.