

HEREDITARY GLAUCOMA* OCCURRENCE IN FIVE GENERATIONS OF AN EDINBURGH FAMILY

BY

A. L. CROMBIE AND J. F. CULLEN

Department of Ophthalmology, University of Edinburgh

A REGULAR Mendelian dominant pattern of inheritance is characteristic of so-called juvenile glaucoma and some hundred genealogies have been recorded (François, 1961), two-thirds showing one or two affected generations and the other third three to six generations. However, in a condition of such high prevalence as primary glaucoma, two successive affected generations are not sufficient to prove a dominant inheritance, because pseudo-dominance, which occurs in an otherwise recessive pattern as a result of a marriage between a homozygote and heterozygote, can produce a similar picture in the genealogical tree.

Juvenile glaucoma is no longer considered to be a separate clinical entity, but occurs either as a late-developing congenital glaucoma or as an early-developing open-angle or closed-angle glaucoma, the open-angle type predominating. The only true juvenile glaucoma is Sugar's pigmentary glaucoma, which is extremely rare.

The purpose of this paper is to report on an Edinburgh family in which five generations have been affected by glaucoma in early life, and to record some unusual manifestations of the condition in this genealogy.

Material

Twelve members of five generations of the "L" family have been investigated. The information regarding the first and second generations has been obtained from the only surviving member of the third, a grandmother now aged 82. Her son and four grandchildren make up the entire fourth and fifth generations and all have been examined by us.

The family tree is shown in Fig. 1. Brief reports on the six members of the first three generations (not examined by us) are followed by more detailed reports on the six members of the fourth and fifth generations.

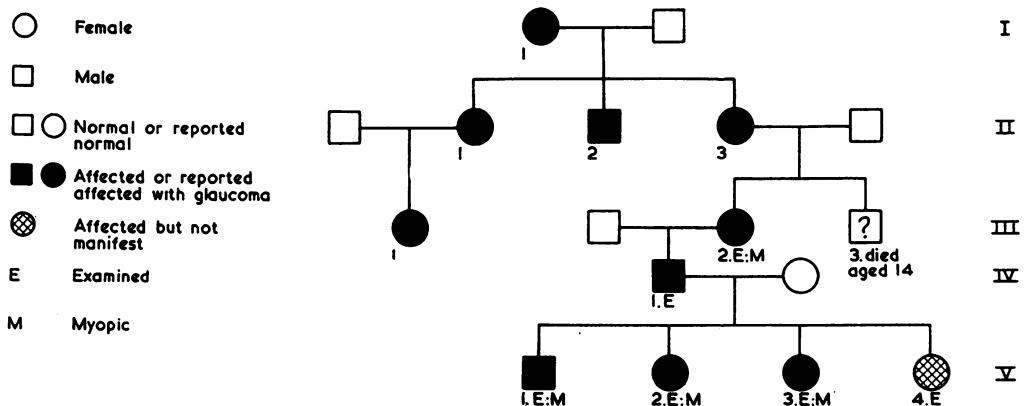


FIG. 1.—Pedigree of "L" family with dominant pattern of inheritance of so-called juvenile glaucoma.

* Received for publication August 19, 1963.

(A) REPORTS ON CASES NOT EXAMINED

- Generation I*, 1. (F) Reported to have had glaucoma, both eyes being enucleated in early adult life.
- Generation II*, 1. (F) Reported to have had glaucoma, blindness occurring at about the age of 20.
 II, 2. (M) Reported to have had glaucoma, blindness occurring at about the age of 30.
 II, 3. (F) Reported to have had glaucoma, but was not blind by the time she died in childbirth at the age of 32.
- Generation III*, 1. (F) Reported to have had glaucoma, but was not blind.
 III, 3. (M) Died as the result of an accident at the age of 14. Glaucoma affection had not been noted by that time.

(B) REPORTS ON CASES EXAMINED

Generation III, 2, a woman aged 82 (from whom the information regarding the previous cases was obtained), complained of haloes at the age of 19 and, because of these symptoms, was seen by an ophthalmologist. Glaucoma was diagnosed and at the age of 25 both eyes were trephined. The trephines are still functioning now, 57 years later.

In 1955 the visual acuity in the right eye was hand movements, and in the left 6/12, with -2.75 D cyl., axis 90°. She read J 4 with reading correction. The intra-ocular pressure was recorded as 25 mm. Hg (Schiötz) in the right eye and 13 mm. Hg in the left. The visual field in the left eye was reduced to 5 degrees with a 15/2000 white target on the Bjerrum screen, and there was also a temporal island of vision remaining peripherally.

She was examined by us in December, 1962, when the right eye was found to be blind with a deeply cupped optic disc, and the intra-ocular pressure was 26 mm. Hg (Schiötz). The visual acuity in the left eye was 6/60 and N 6. The left optic disc was also deeply cupped, but a fair visual field remained on the temporal side. A good draining trephine bleb was noted and the intra-ocular pressure was 23 mm. Hg (Schiötz).

Generation IV, 1, a man aged 52 (the only child of Case III, 2), is now working in the Royal Blind Asylum, Edinburgh. His left eye was noted to be enlarged from a very early age and was "always blind". At the age of 20 he started to have haloes in the right eye, but did nothing about them; 2 years later, when he was examined by an ophthalmologist, the right eye was also found to be blind with absolute glaucoma. At the age of 49 the buphthalmic left eye was enucleated because of a suspected malignant melanoma of the conjunctiva; a section of this eye is shown in Fig. 2 (opposite).

A pathological examination was carried out by Dr. B. A. Bembridge who reported as follows:

Adjacent to the limbus at one side is a collection of heavily pigmented epithelial-type cells lying beneath the conjunctival epithelium. These cells vary in size and they surround groups of unpigmented naevus cells of fairly uniform size. There is also one collection of proliferating pigmented cells within the conjunctival epithelium. The histological picture is, therefore, that of a compound melanoma. It is confined to the subconjunctival tissue and shows no evidence of deep extension into the scleral fibres.

There is some infiltration of anterior corneal lamellae with polymorphonuclear leucocytes. No other histological changes are present in the cornea. The anterior chamber appears abnormally deep, and there is the formation of a false angle by a delicate pigmented fibrous network extending from the iris into the angle of the anterior chamber. The canal of Schlemm appears to be present, for an endothelial-lined channel is seen in at least one section. In other sections this channel is difficult to identify. There are pigment deposits on the anterior surface of the lens.

The ciliary body shows hyaline changes, and there is evidence of choroido-retinal degeneration. The optic disc is deeply cupped and the nerve atrophic.

COMPOUND MELANOMA OF CONJUNCTIVA
 PERIPHERAL ANTERIOR SYNECHIAE
 CHRONIC GLAUCOMA

When this patient was seen recently the intra-ocular pressure in the remaining right eye was 70 mm. Hg (Schiötz). The anterior chamber was deep, a complete cataract was present, and there was rubeosis of the iris. This eye is symptomless.

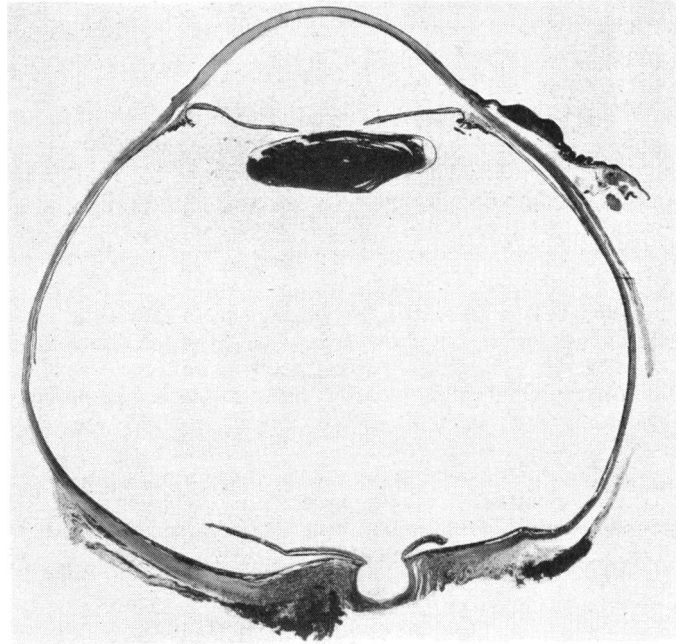


FIG. 2.—Generation IV, 1. Section of eye showing deep anterior chamber, cupped disc, and conjunctival melanoma.

Generation V, 1, a young man aged 22, was first seen at the Eye Department at the age of 11 because of haloes. The visual acuity in both eyes was 6/5 unaided. Both discs were normal, but the intra-ocular pressure was 40 mm. Hg (Schiötz) in the right eye and 35 mm. Hg in the left. The tension was not controlled by medical treatment and, after 4 months, bilateral scleral trephines were carried out. He was discharged from hospital after operation with a tension of 10 mm. Hg (Schiötz) and a visual acuity of 6/6 partly in each eye. At this time there was no field defect in the right eye but there was an early arcuate scotoma in the left to a 2/2000 white target, which persisted for 2 years after the operation, gradually decreasing until only a nasal step remained.

He was last seen in November, 1962, when the corrected visual acuity in the right eye was 6/9 and N 5, with -0.5 D sph., $+0.5$ D cyl., axis 90° , and in the left 6/9 and N 5, with -1 D sph., $+0.5$ D cyl., axis 180° . No cupping of the discs was noted and the tension was 24 mm. Hg (Schiötz) in the right eye and 20 mm. Hg in the left. Gonioscopy showed wide open angles with many peripheral anterior synechiae at the trephine sites. There was no defect in either the central or peripheral field. The patient had not been using drops for the past 10 years.

Generation V, 2, a girl aged 16, was first seen at the age of 9 because of the family history of glaucoma. At that time the visual acuity was 6/5 unaided in each eye, both discs were normal, and the tension was 17 mm. Hg (Schiötz) in each eye.

She reported again in August, 1962, complaining of poor distance vision for the previous 2 months. Now the visual acuity in the right eye was 6/9, with -2 D sph., and 6/9 + in the left, with -2.5 D sph. Both discs were cupped and the intra-ocular pressure was 55 mm. Hg (Schiötz) in each eye. Gonioscopy showed wide open angles. The central visual fields showed a large lower arcuate scotoma in the right eye to a 2/2000 white target, extending to within 10° of fixation, and a similar scotoma in the left up to 15° of fixation. As the tension was not controlled by miotics she was admitted to hospital, where phasing showed intermittent rises of pressure up to 36 mm. Hg (Schiötz) in each eye despite full medical treatment. Bilateral corneo-scleral trephines were therefore carried out, and the tension has since remained at about 12 mm. Hg (Schiötz) in each eye, and the field defects have almost disappeared. Both trephines are draining well and the visual acuity is 6/6 partly in each eye with correction.

Generation V, 3, a schoolgirl aged 13, was first seen at the age of 5 years because she was complaining of haloes. Both discs were normal at that time, but the intra-ocular pressure was 32 mm. Hg (Schiötz) in the right eye and 36 mm. Hg in the left. As the tension was not controlled by miotics, bilateral scleral trephines were carried out in February, 1955, and she was discharged from hospital with a tension of 17 mm. Hg (Schiötz) in each eye.

She was examined by us in March, 1963, when the visual acuity in the right eye was 6/6 and N 5, with -0.5 D cyl., axis 180°, and in the left 6/6 and N 5 with the same correction. The visual fields were full and gonioscopy showed wide open angles. The tension in both eyes again measured 17 mm. Hg (Schiötz); both trephines were draining satisfactorily. The left optic disc looked paler than the right, but no cupping was noted.

Generation V, 4, a schoolgirl aged 11, was examined at the age of 3 years because of the family history of glaucoma, but showed no evidence of the disease at that time. She was re-examined by us in March, 1963, when the visual acuity in both eyes was 6/5 and N 5 unaided and there was no refractive error. The intra-ocular pressure was 14 mm. Hg (Schiötz) in both eyes and no field defects were recorded. Gonioscopy showed wide open angles and both discs were normal. On a provocative water-drinking test, there was a significant rise in tension in each eye from 17 to 24 mm. Hg (Schiötz) in the right after 45 minutes, and from 14 to 20 mm. Hg (Schiötz) in the left after 45 minutes. Tonography done in combination with the water-drinking test showed an outflow coefficient of 0.17 in both eyes. It is felt that this child has also some evidence of glaucoma and will probably develop other signs of the disease in the future.

Discussion

The usual mode of inheritance of so-called juvenile glaucoma is dominant, affecting both sexes equally and rarely missing a generation, whereas that of congenital glaucoma is recessive, affecting males in the ratio of 2:1 and missing at least one generation, if not two or even three.

The pattern of inheritance of glaucoma in the "L" family is obviously dominant, but there are more affected members in each generation than would be expected if a simple dominance existed. The possibility that this has occurred by chance through simple dominance is remote but possible. The more likely explanation for the involvement of the whole of the fifth generation at least, is that their father (Generation IV, 1) is homozygous for the glaucoma gene in this family. This presupposes that both his parents were affected but, unfortunately, no information is available about his father. Furthermore, we are unable to obtain any details regarding the other individuals who married into the family, apart from knowing that the mother of the four children of the fifth generation died at the age of 45 from disseminated sclerosis and was certified as blind as a result of optic neuritis.

The father (Generation IV, 1) is interesting from another point of view. His left eye was buphthalmic and was enucleated a few years ago. His right eye did not develop manifest glaucoma until he was about 20 years of age, and this eye, which now shows absolute glaucoma, is not buphthalmic. Duke-Elder (1940) stated that buphthalmos and simple glaucoma do not occur together, but this man does appear to have harboured both conditions.

The "L" family shows a high incidence of myopia; two-thirds of the members examined were affected as against the 30 to 50 per cent. expected incidence previously reported (François, 1961) in this type of glaucoma.

The presenting symptom in four of the five manifest cases examined was haloes,

the exception being Generation V, 2, who complained of blurring of vision. Gonioscopic examination has been carried out on all members of the fifth generation and all, without exception, show deep anterior chambers with open angles, no evidence of congenital malformation of the angles being noted.

The type of glaucoma which this family exhibits is, therefore, the open-angle variety which does not usually give rise to haloes as a presenting symptom. The haloes occurred in V, 1 and V, 3 at the ages of 11 and 5 respectively, in the tension range of 30 to 40 mm. Hg (Schiötz), while V, 2 had blurred vision at the age of 16 in the tension range of 50 to 60 mm. Hg (Schiötz). This suggests that haloes can be a symptom of early-developing open-angle glaucoma, and that the young cornea is more liable to be so affected by slowly-developing raised intra-ocular pressure than the more adult one.

Summary

Twelve members from five generations of a family showing a high incidence of hereditary so-called juvenile glaucoma of the open-angle variety are described. The precise mode of inheritance is discussed but has not been fully elucidated. The finding of low myopia in a majority of the involved members is noted, and the significance of haloes as a presenting symptom in this type of glaucoma is also discussed.

We are indebted to Prof. G. I. Scott for permission to report this family, and for his advice in the preparation of the paper.

REFERENCES

- DUKE-ELDER, S. (1940). "Text-book of Ophthalmology", vol. 3, p. 3332. Kimpton, London.
FRANÇOIS, J. (1961). "Heredity in Ophthalmology", pp. 225-238. Mosby, St. Louis.