

CONJUGATE DEVIATION OF THE EYES AFTER *Cannabis indica* INTOXICATION*

BY

HARI MOHAN AND G. C. SOOD

From the Department of Ophthalmology, Maulana Azad Medical College, New Delhi

Cannabis indica or *Sativa* (also known as Indian hemp and marihuana) is an easily available cheap intoxicant used by certain communities in India. Cannadiol ($C_{21}H_{30}O_2$) and cannabinol ($C_{21}H_{26}O_2$) in pure crystalline forms have been isolated from it (Adams, 1942). A highly effective compound similar to tetrahydrocannabinol (Adams, 1942) has been isolated from the natural source (Loewe and Modell, 1941). The principal site of action of *Cannabis indica* is the brain, particularly the cerebral cortex (Chopra, Chopra, and Chopra, 1942; Allentuck, 1944; Loewe, 1944); it causes excitation in some cases, and depression of higher functions in others.

After ingestion of the drug the subject experiences a feeling of euphoria and exaltation with extravagant dream fantasies and loses his sense of time (Walton, 1938), but acute poisoning by *Cannabis indica* is extremely rare (Walton, 1938) and no fatality has been reported (Walton, 1938; Loewe, 1944; Sollmann, 1957). The effect is usually transitory and wears off in 3 to 5 hours, though it may persist for 12 hours or more with no lasting ill-effects (Loewe, 1944). The margin between the effective and fatal dose is wide, the intravenous fatal dose for dogs being a hundred times the narcotic dose (Sollmann, 1957). Mises-Reif (1936) reported temporary blindness, ulcers of the cornea, and swelling of the lids in a woman who worked in a field of *Cannabis indica*. Other ocular signs include congestion of the conjunctiva and lids (Allentuck, 1944; Walsh, 1947; Sollmann, 1957), dilatation of the pupils (Walsh, 1947; Sollmann, 1957) corneal areflexia (Loewe, 1944), and visual hallucination (Chopra and others, 1942; Allentuck, 1944; Walsh, 1947).

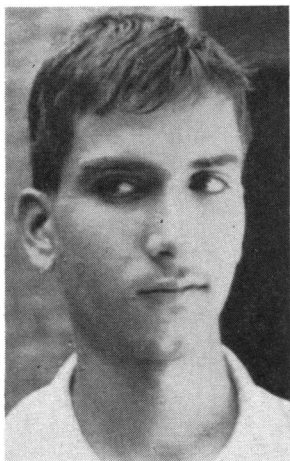


FIG. 1.—Eyes deviating to the right and head tilted to the left one week after taking *Cannabis indica*.

The case of *Cannabis indica* poisoning presented below is interesting because of the conjugate deviation of the eyes, not reported before, and the long duration of the intoxication.

Case Report

An 18-year-old Hindu male ate food containing *Cannabis indica* after which he felt giddy and sleepy, and the giddiness persisted for some days. He had difficulty in turning his eyes to the left and this increased until after a week his eyes remained fixed in the

* Received for publication June 7, 1963.

dextroverted position. To look forwards he had to compensate by turning his head to the left (Fig. 1). At this time all the ocular movements were absent, but the fundi were normal, and systemic and laboratory investigations were negative.

The patient was given vitamin B₁ and B₁₂ intramuscularly, and he slowly recovered until he was completely well after about 6 weeks (Fig. 2). There was no residual weakness of the extra-ocular muscles.

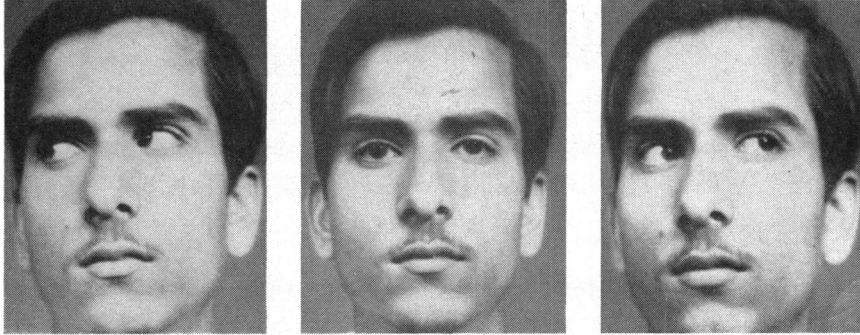


FIG. 2.—Normal eye movements 6 weeks later.

Summary

A case is reported in which conjugate deviation of the eyes resulted from *Cannabis indica* intoxication and the effects of the drug lasted for 6 weeks.

REFERENCES

- ADAMS, R. (1942). "The Harvey Lectures 1941-1942", series 37, p. 168.
 ALLENTUCK, S. (1944). In "The Marihuana Problem in the City of New York", p. 35. Jaques Cattell Press, Lancaster, Pennsylvania.
 CHOPRA, R. N., CHOPRA, G. S., and CHOPRA, I. C. (1942). *Indian J. med. Res.*, **30**, 155.
 LOEWE, S. (1944). In "The Marihuana Problem in the City of New York", p. 149. Jaques Cattell Press, Lancaster, Pennsylvania.
 ——— and MODELL, W. (1941). *J. Pharmacol. exp. Ther.*, **72**, 27.
 MIESES-REIF, M. (1936). *Z. Augenheilk.*, **89**, 226.
 SOLLMANN, T. (1957). "A Manual of Pharmacology", 8th ed. Saunders, Philadelphia.
 WALSH, F. B. (1947). "Clinical Neuro-ophthalmology". Williams and Wilkins, Baltimore.
 WALTON, R. P. (1938). "Marihuana, America's New Drug Problem". Lippincott, Philadelphia.