

COMMUNICATIONS

EPIDEMIC KERATO-CONJUNCTIVITIS*

REPORT OF AN OUTBREAK WHICH RESULTED IN WARD CROSS-INFECTION

BY

SIDNEY I. DAVIDSON

Birmingham and Midland Eye Hospital

IN April 1961 it became apparent that an increasing number of patients was attending the out-patients department of the Birmingham and Midland Eye Hospital with a follicular conjunctivitis, and an associated pre-auricular adenitis, which often proceeded to a keratitis. This was soon recognized as an outbreak of epidemic kerato-conjunctivitis and therefore precautionary measures were immediately taken to prevent iatrogenic spread, *e.g.* cessation of tonometry, tonography, and gonioscopy. Altogether about 500 patients were affected but the unusual feature of this outbreak was the spread of the disease to involve the in-patients of the hospital, a serious degree of cross-infection occurring in the wards. The main purpose of this paper is to report this unusual feature of the outbreak of epidemic kerato-conjunctivitis but mention will be made of how the disease affected the out-patients.

Epidemic kerato-conjunctivitis has long been recognized as a clinical entity since the early descriptions of outbreaks (Stellwag von Carion, 1889; von Reuss, 1889; Fuchs, 1889; Adler, 1889; and others). An adequate historical review has been provided by Hogan and Crawford (1942), who designated the disease "epidemic kerato-conjunctivitis" (EKC) and thus allowed differentiation from the many other causes of superficial punctate keratitis. EKC is a severe viral kerato-conjunctivitis which is widespread in sporadic and epidemic form throughout the world, the greatest incidence being in the Far East. The evidence for incrimination of adenovirus type 8 as the causal agent has been outlined by Jawetz (1962) and includes:

Growth of the virus in cell culture (Jawetz, Thygeson, Hanna, Nicholas, and Kimura, 1956; Hanna, Jawetz, Mitsui, Thygeson, Kimura, and Nicholas, 1957; Bennett, Law, Hamilton, and Macdonald, 1957);

Demonstration in convalescents of neutralizing antibody to adenovirus type 8 (Jawetz, Thygeson, Hanna, Nicholas, and Kimura, 1956; Sommerville, 1958);

Experimental inoculation of volunteers (Mitsui, Hanna, Minoda, Ogata, Kurihara, Okamura, and Miura, 1959);

Accidental laboratory infections (Jawetz, Hanna, Sonne, and Thygeson, 1959);

Vaccination (Ogata, Kurihara, Okamura, Tanaka, and Wakae, 1960).

The incubation period of the disease is about one week, the onset being sudden. A unilateral follicular conjunctivitis characterizes the conjunctival phase with lymphocytes predominating in the scant, watery discharge. Most patients show an associated moderate degree of swelling and tenderness of the pre-auricular lymph node. Pseudo-membrane formation occasionally occurs. The corneal phase is diagnostic, appearing 7 to 10 days after the onset of the follicular conjunctivitis, and is accompanied by marked discomfort and photophobia. It is characterized by a

* Received for publication March 24, 1964.

punctate epithelial keratitis, proceeding to combined epithelial and subepithelial lesions followed by healing of the epithelial component, leaving coarse round subepithelial infiltrates which persist for months but usually disappear without formation of nebulae. (An excellent description of the keratitis has been given by Jones, 1960). It is generally recognized that the disease can occur as a conjunctivitis alone and, except in connexion with a known epidemic, such cases can then be confused with a number of other forms of acute follicular conjunctivitis. There are rarely any systemic signs, except in children when respiratory and abdominal symptoms with fever may often be present.

Observations

Out-Patients

When it became apparent that there was an outbreak of EKC a group of fifty out-patients was selected and studied. Defaulting and other causes reduced this number to 34, and this total included fifteen patients who had been attending the glaucoma clinic. This group of patients was followed up for almost 3 years with particular reference to visual acuity, corneal sensation, and persistence of corneal nebulae. Cultures for bacterial growth were negative from all eyes.

Incubation Period.—In general the incubation period conformed to the expected 7 to 10 days, but seven patients were unusual in that their symptoms did not develop until 2 weeks or more after their last visit to the glaucoma clinic.

Clinical Features.—The patients usually presented with a complaint of discomfort and redness in one eye with minimal discharge; in the glaucoma patients the conjunctivitis was bilateral at onset. The conjunctivitis was follicular and associated with pre-auricular adenitis. Of the group of 34 patients, 25 (73·5 per cent.), including all the glaucoma patients, developed the typical subepithelial infiltrates of EKC which usually became inactive within 2 weeks.

Complications.—In six (17·6 per cent.) patients the keratitis proceeded to marked stromal oedema associated with many folds of Descemet's membrane and two of them developed a severe anterior uveitis which subsided slowly. One had extensive pseudo-membrane formation. Corneal sensation was reduced in those patients who suffered a massive superficial keratitis.

Follow-up.—The visual acuity returned to normal in all patients with corneal involvement except for a youth who had suffered a massive superficial keratitis, and whose visual acuity remains at 6/12 in the affected eye. Though no permanent impairment of vision had occurred in the other patients who had developed keratitis, the majority complained of blurring and distortion; this gradually resolved as the corneal opacities resulting from the subepithelial infiltrates cleared in the succeeding months. When seen recently, almost 3 years after the epidemic, only a few of the affected patients had small faint residual nebulae apparent in the superficial layers of the corneal stroma and in none has the corneal sensation been permanently reduced.

In-Patients

Soon after the recognition of the outbreak of epidemic kerato-conjunctivitis in the out-patients department, sporadic cases appeared in the wards and later produced an explosive outbreak of cross-infection.

The case notes of 791 in-patients over the 4-month period covered by May to August, 1961, showed that the overall incidence of conjunctivitis in the wards was 8.5 per cent. Its presumed breakdown into viral and bacterial origin is indicated in Table I, and Table II shows the pattern of the disease.

TABLE I
CONJUNCTIVITIS IN IN-PATIENTS

Total Number of In-Patients		791
Conjunctivitis	Total Number of Cases	67 (8.5 per cent.)
	Bacterial confirmed by culture Probably bacterial, <i>i.e.</i> response to antibiotics without evidence of EKC	8 } 3 } 11 (1.4 per cent.)
	Presumed viral	56

TABLE II
VIRAL CONJUNCTIVITIS

Total Number of Cases		56
Type of Infection	(a) Sub-epithelial infiltrates (b) Only follicles and pre-auricular adenitis (c) Follicular conjunctivitis alone (d) Suggestive history and clinical description, but no pathogenic organisms grown and available details insufficient to allow placing in groups (a), (b), or (c).	16 (28.6 per cent.) 9 6 25

Owing to its prevalence, as the epidemic progressed both in the out-patients department and in the wards, the disease was summarily described in the notes as "EKC". This accounts for the large number in Group d of Table II and also for the infrequency of cases with observed keratitis. There were 56 cases of viral conjunctivitis and eleven of bacterial origin distributed among a variety of surgical patients (Table III).

TABLE III
ANALYSIS OF CASES OF CONJUNCTIVITIS

Diagnosis	Infection	
	Viral	Bacterial
Cataracts	18	5
Glaucoma	10	2
Retinal Detachment	8	1
Secondary Glaucoma	7	—
Diurnal Variations	5	1
Squints	4	1
Injuries	2	—
Needling	—	1
Miscellaneous	2	—
Total No. of Cases	56	11

Examination of the weekly (Fig. 1) and monthly (Fig. 2) incidence of conjunctivitis shows that the peak incidence of virus conjunctivitis was reached at the end of May and during the month of June, tailing off to August, and thereafter only a sporadic case was noted. The frequency of cases of EKC was not related to the admission rate which remained more or less steady and was in fact reduced because of the epidemic.

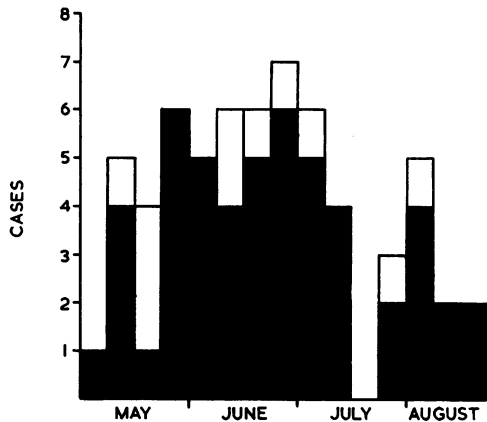


FIG. 1.—Weekly incidence of conjunctivitis.
 ■ Viral conjunctivitis
 □ Bacterial conjunctivitis

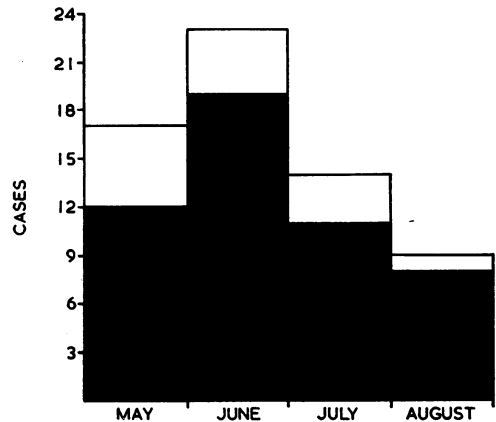


FIG. 2.—Monthly incidence of conjunctivitis.
 ■ Viral conjunctivitis
 □ Bacterial conjunctivitis

The various cases of EKC were equally distributed in the wards with the exception of the children's ward where the incidence was proportionately very low. No particular member of the medical staff attended an unduly large number of cases.

One house surgeon and the theatre sister became infected and both developed some degree of keratitis. The house surgeon was infected in April before the cross-infection in the wards began, and the theatre sister in July long after the majority of cases had occurred in the wards. On incurring the infection both were immediately considered unfit for duty. A consultant, who had retired from hospital service but continued in private practice, developed a severe kerato-conjunctivitis which necessitated treatment with a cycloplegic to relieve symptoms.

Virological Investigations

Cases serologically investigated for Complement-fixing Antibodies.—Of 39 cases investigated, sixteen showed a four-fold or greater rise in titre of antibodies fixing complement with adenovirus group antigen. Among the 39 cases, eighteen sera were quite negative (no rise or titre of 1:8 only), and five further sera gave a weak rise, but not to more than 1:16.

Results of Neutralization Tests against Adenovirus Type 8.—Neutralization tests were performed in cynomolgus (*Macaca irus* species) kidney cell cultures, using 100TCD₅₀ of virus as test inoculum. These cells were used for neutralization tests in preference to HeLa cells in which the growth of this virus was erratic. Their sensitivity to the virus appeared probably less than that of HeLa cells but their behaviour was found to be more predictable. In the great majority of patients

tested, neutralizing antibodies were present in levels of at least 1:16 in the first serum. In most cases the infection had been present for at least 7 to 10 days, and often longer, when first investigated, so that rising neutralization titres were difficult to demonstrate.

Sixteen pairs of sera were investigated: seven had neutralization titres of 1:96, one at 1:48, and four at 1:16; two gave partial neutralization at 1:16, and two neutralized at 1:4 only. Further samples of serum from these patients made it possible to demonstrate a four-fold or greater rise in neutralizing antibody titre in only two cases. Two first sera gave only partial neutralization at 1:4 and no neutralization at 1:16, and three sera were completely negative.

The sera were also investigated for the presence of neutralizing antibodies to adenovirus type 3, because a type 3 had been isolated from the conjunctiva of one patient. Though most had neutralizing antibodies, it was not possible to demonstrate any rise in titre against this virus in any patient.

Attempts were made at isolating virus from conjunctival swabs (using cotton-wool tufts at the end of orange sticks), but adenovirus type 8 was not isolated in either HEpII cells or HeLa cells or human embryo fibroblasts, although adenovirus type 3 was isolated from one patient. It has, however, been shown that isolation of adenovirus type 8 necessitates a conjunctival scraping after topical anaesthesia (Mitsui, Hanna, Hanabusa, Minoda, Ogata, Kurihara, Okamura, and Miura, 1959). One has to be "bloody, bold, and resolute" when taking specimens for culture (Flewett, 1962).

Treatment

Therapy was directed towards the relief of symptoms which were sometimes severe when the cornea became involved. Zinc sulphate drops were found to help a number of patients and when infiltrates became extensive oily achromycin drops provided some relief, though it should be noted that these drops on occasion caused distress. When the keratitis had become extensive, a cycloplegic helped to relieve the symptoms.

Discussion

Virology

It has generally been found that a positive complement-fixation test for adenovirus antigen with rising titre in the course of EKC can be demonstrated in the sera of most patients, and this was confirmed in our own patients whose sera were investigated for complement-fixing antibodies. (It is to be noted that the test fails to detect a proportion of adenovirus infections.) Neutralizing antibodies to type 8 virus can be regularly demonstrated in the convalescent sera of patients with EKC while the acute phase sera rarely contain any antibodies (Jawetz and others, 1956; Mitsui, Hanabusa, Minoda, and Ogata, 1957; Sommerville, 1958). Our results of neutralization tests against adenovirus type 8 support Sommerville's opinion that the neutralization test was more reliable than the complement-fixation test. Since neutralizing antibodies against adenovirus type 8 are rarely found in the general population, it would seem reasonable to conclude from our results that the outbreak was due to type 8 adenovirus.

Tonometry

Adenovirus type 8 differs biologically from the other adenoviruses in that, although there is a low yield of infective virus in cell cultures, such cultures have a high antigen content—indicating that the greater part of synthesized virus is non-infective, at any rate for tissue cultures (Jawetz, Hanna, Nicholas, and Hoyt, 1958). These findings help to explain the epidemiology of the disease.

The low infectivity of the virus on normal contact explains the absence of spread in the general population and even in the families of affected patients. It would seem that successful transmission requires a large inoculum placed directly in the eye from infected persons or objects, probably aided by minor trauma (Jawetz, 1962). This situation is especially found in the instrumentation and examination that occurs in the out-patients departments of eye hospitals and explains the largely iatrogenic spread of the disease under these circumstances.

Outbreaks of EKC affecting patients attending eye hospitals and clinics have been reported by Hobson (1938) sixteen cases: Cockburn, Nitowsky, Robison, and Cheever (1953) nine cases: Schneider, Kornzweig, and Feldstein (1956) twenty cases: and Dawson and Darrell (1963) 27 cases, amongst others. There have also been several reports from Japan (Okamura and Mitsui, 1941; Aoki and Kasahara, 1941; Mitsui and Tanaka, 1950). In the main these outbreaks have been attributed to transmission of the virus through contaminated eye-drops or tonometers, particularly the latter. Sterilization of tonometers is usually accomplished by chemicals (ether or alcohol), flaming (Dreisler, 1955), or ultra-violet radiation (Rosner, 1955), and ultra-violet light was used for sterilization of the tonometers which were responsible for the spread of the disease in the glaucoma clinic as reported in this paper. While it is true that type 8 adenovirus is destroyed by ultra-violet light, this does not mean that the radiation will be able to penetrate within the socket of the tonometer wherein the plunger resides during indentation of the cornea. Moreover, a zero-reading should always be verified on the test-block before using the instrument, so that the artificial cornea must also be sterilized adequately between readings. Either or both of these weaknesses in the ultra-violet mode of sterilization may have been responsible for the iatrogenic spread of the virus in the glaucoma clinic. Of the group of out-patients studied (*vide supra*), just under half attended the glaucoma clinic where tonometry was routinely performed on arrival. These patients had a bilateral conjunctivitis from the onset and all developed the characteristic keratitis, thus explaining the higher incidence of keratitis (73·5 per cent.) in this epidemic as compared with a lesser figure in most other outbreaks.

Cross-Infection in the Wards

A search of the literature failed to elicit any reports on the incidence of conjunctivitis affecting in-patients in the wards of eye hospitals. Accordingly, in order to obtain comparative figures for the normal incidence of conjunctivitis in the wards of the Birmingham and Midland Eye Hospital, the case notes of 1,056 in-patients admitted during the months of May, June, July, and August, 1962, were examined. In all, twelve cases of conjunctivitis (ten occurring after squint surgery and two after cataract extraction) were observed during the period under scrutiny, giving an incidence of 1·1 per cent. This figure compares very closely with that for bacterial conjunctivitis

(1·4 per cent.) noted during the outbreak of epidemic kerato-conjunctivitis (see Table I), confirming the identification of the cases of viral conjunctivitis. It therefore becomes apparent that an incidence of conjunctivitis of 8·5 per cent. in the wards of an eye hospital (see Table I) indicates an explosive outbreak of cross-infection.

The cross-infection of in-patients as reported in this paper appears to be unique, no previous similar report having been found. Brief reference to a few post-operative patients who developed EKC was made by Feigenbaum, Michaelson, and Kornblüth (1945) but no details were provided. Leopold (1957) gave an account of seventeen persons affected with EKC in a certain hospital, of whom eleven were medical staff, three patients, two nurses, and one an occupational therapist; the spread of this outbreak was mainly attributed to the common use of an electric ophthalmoscope in the hospital by the medical staff.

There can be no doubt that the spread of the epidemic from the out-patients department to the wards must have been iatrogenic, but it was not possible to establish conclusively the mode of cross-infection in the wards. Tonometry, tonography, and gonioscopy were suspended during the outbreak. Transmission of the virus by contaminated solutions appeared unlikely as during this period the majority of patients had their individual drops, sterile droppers being used at each instillation, and moreover no solution was common to the affected patients. It is possible that some cases occurred after the use of contaminated fomites, *e.g.* goggles or temporary spectacles, but the most likely cause of spread of the disease was by direct finger to eye transmission by both medical and nursing staff. It is to be noted that attending ophthalmologists are frequently infected before the true nature of the disease becomes apparent, probably through direct finger to eye transmission (Thygeson, 1948). Thygeson (1957) believed finger to eye transmission to be the most frequent mode of spread of the epidemics of EKC he had studied, and attributed the infection of 32 physicians and 40 nurses (despite ordinary hand-washing with soap and water between patients by the ophthalmologists) to this cause. Extra-meticulous washing of the hands with soap and water is necessary before adequate decontamination of the adenovirus type 8 can be assured.

Relatively few children in the wards (four following squint surgery) were affected during the outbreak of cross-infection. This finding is interesting in view of observations that childhood infection with EKC results in a mild atypical form of the disease accompanied by respiratory and gastro-intestinal symptoms (Mitsui, Tanaka, and Yamashita, 1955; Mitsui, Hanna, Minoda, and others, 1959). The juvenile form of the disease is very infectious and is characterized by a follicular conjunctivitis and often by pseudomembrane formation without pre-auricular adenitis or keratitis.

Summary

An account is given of an outbreak of epidemic kerato-conjunctivitis, the spread of which was due in part to tonometry in a glaucoma clinic. The tonometers had been sterilized by ultra-violet radiation.

The unique feature of this epidemic was its progression to produce a serious degree of cross-infection in the wards. An incidence of conjunctivitis of 8·5 per cent. was

recorded as opposed to a normal figure of 1·1 per cent. The most likely mode of spread of the disease in the wards appeared to be finger to eye transmission.

Virological investigations indicated that the causal organism was adenovirus type 8.

I should like to thank the consultant surgeons of the Birmingham and Midland Eye Hospital for permission to report this outbreak and for their interest and encouragement. I am also grateful to Dr. T. H. Flewett for the virological investigations and much helpful criticism.

REFERENCES

- ADLER, H. (1889). *Zbl. prakt. Augenheilk.*, **13**, 289.
- AOKI, H., and KASAHARA, C. (1941). *Acta Soc. ophthal. jap.*, **45**, 573.
- BENNETT, F. M., LAW, B. B., HAMILTON, W., and MACDONALD, A. (1957). *Lancet*, **2**, 670.
- COCKBURN, T. A., NITOWSKY, H., ROBISON, T., and CHEEVER, F. S. (1953). *Amer. J. Ophthal.*, **36**, 1367.
- DAWSON, C., and DARRELL, R. (1963). *New Engl. J. Med.*, **268**, 1031.
- DREISLER, K. K. (1955). *A.M.A. Arch. Ophthal.*, **53**, 860.
- FEIGENBAUM, A., MICHAELSON, I. C., and KORNBÜTH, W. (1945). *Brit. J. Ophthal.*, **29**, 389.
- FLEWETT, T. H. (1962). *J. med. Wom. Fed.*, **44**, 112.
- FUCHS, E. (1889). *Wien. klin. Wschr.*, **2**, 837.
- HANNA, L., JAWETZ, E., MITSUI, Y., THYGESON, P., KIMURA, S. J., and NICHOLAS, A. (1957). *Amer. J. Ophthal.*, **44**, 66.
- HOBSON, L. C. (1938). *Ibid.*, **21**, 1153.
- HOGAN, M. J., and CRAWFORD, J. W. (1942). *Ibid.*, **25**, 1059.
- JAWETZ, E. (1962). *Trans. ophthal. Soc. U.K.*, **82**, 613.
- , HANNA, L., NICHOLAS, A., and HOYT, R. (1958). *Amer. J. Hyg.*, **67**, 276.
- , ———, SONNE, M., and THYGESON, P. (1959). *Ibid.*, **69**, 13.
- , THYGESON, P., HANNA, L., NICHOLAS, A., and KIMURA, S. J. (1956). *Proc. Soc. exp. Biol. (N.Y.)*, **93**, 91.
- , ———, ———, ——— (1957). *Amer. J. Ophthal.*, **43**, No. 4, pt. 2, p. 79.
- JONES, B. R. (1960). *Trans. ophthal. Soc. U.K.*, **80**, 665.
- LEOPOLD, I. H. (1957). *Amer. J. Ophthal.*, **43**, No. 4, pt. 2, p. 93.
- MITSUI, Y., HANABUSA, J., MINODA, R., and OGATA, S. (1957). *Ibid.*, **43**, No. 4, pt. 2, p. 84.
- , HANNA, L., HANABUSA, J., MINODA, R., OGATA, S., KURIHARA, H., OKAMURA, R., and MIURA, M. (1959). *A.M.A. Arch. Ophthal.*, **61**, 891.
- , ———, MINODA, R., OGATA, S., KURIHARA, H., OKAMURA, R., and MIURA, M. (1959). *Brit. J. Ophthal.*, **43**, 540.
- and TANAKA, C. (1950). *Acta Soc. ophthal. jap.*, **54**, 346.
- , ———, and YAMASHITA, K. (1955). *Amer. J. Ophthal.*, **39**, 540.
- OGATA, S., KURIHARA, H., OKAMURA, R., TANAKA, R., and WAKAE, K. (1960). *Acta Soc. ophthal. jap.*, **64**, 1202.
- OKAMURA, K., and MITSUI, Y. (1941). *Ibid.*, **45**, 108 (cited by LEOPOLD, 1957).
- REUSS, A. VON (1889). *Wien. klin. Wschr.*, **2**, 665.
- ROSNER, R. S. (1955). *A.M.A. Arch. Ophthal.*, **53**, 889.
- SCHNEIDER, J., KORNZWEIG, A., and FELDSTEIN, M. (1956). *Amer. J. Ophthal.*, **42**, 266.
- SOMMERVILLE, R. G. (1958). *J. Hyg. (Camb.)*, **56**, 101.
- STELLWAG, VON CARION, K. (1889). *Wien. klin. Wschr.*, **2**, 613.
- THYGESON, P. (1948). *Trans. Amer. ophthal. Soc.*, **46**, 366.
- (1957). *Amer. J. Ophthal.*, **43**, No. 4, pt. 2, p. 98.