

INHERITED VARIATION IN RIEGER'S MALFORMATION*

BY

W. G. PEARCE AND C. B. KERR

*Nuffield Laboratory of Ophthalmology and Oxford Eye Hospital, and
M.R.C. Population Genetics Research Unit, Oxford*

RIEGER (1935) gave the accurate and self-explanatory name "dysgenesis mesodermalis corneae et iridis" to an inherited malformation involving the angle of the anterior chamber, iris stroma, and peripheral cornea. The basic feature of this abnormality was the presence of strands of iris stroma which passed from the iris root across the angle to the trabecular meshwork and to a congenital corneal opacity at the end of Descemet's membrane, known as posterior embryotoxon. Other less suitable names given to the abnormality include congenital hyaline membrane on the posterior surface of the cornea (Mann, 1933), dysgenesis mesostromalis (Hagedoorn, 1937), posterior marginal dysplasia (Streiff, 1949), and Axenfeld's syndrome (Axenfeld, 1920). As these different terms suggest, there were various opinions on the developmental origin and characteristic features of the malformation. Embryological studies, notably those by Allen, Burian, and Braley (1955), suggested that Rieger's malformation was due to dysplasia of primitive angle mesoderm from which the trabecular meshwork and iris stroma are derived. Clinical and genetic features have been reviewed by Waardenburg, Franceschetti, and Klein (1961), who had difficulty in classifying reports of isolated and familial cases because of the great variability in clinical findings. In certain families the malformation was associated with dental and other ectodermal anomalies (Kittel, 1956; Gassler and Berthold, 1960). Where two or more generations could be studied, Rieger's malformation was apparently due to a dominant gene, but Waardenburg showed that there was not enough information to draw conclusions on the variability of gene effect among members of the same family. This problem has been examined further in the present investigation of a family living in the Oxford area.

Methods of Investigation

The family (Fig. 1) was ascertained through III₄, a man who had received treatment for bilateral glaucoma; 36 members were examined in the Oxford Eye Hospital under constant conditions of illumination and equipment. The skin, dentition, hair distribution, and sense of smell were also examined in detail. Ocular examination consisted of: determina-

* Received for publication December 28, 1964.

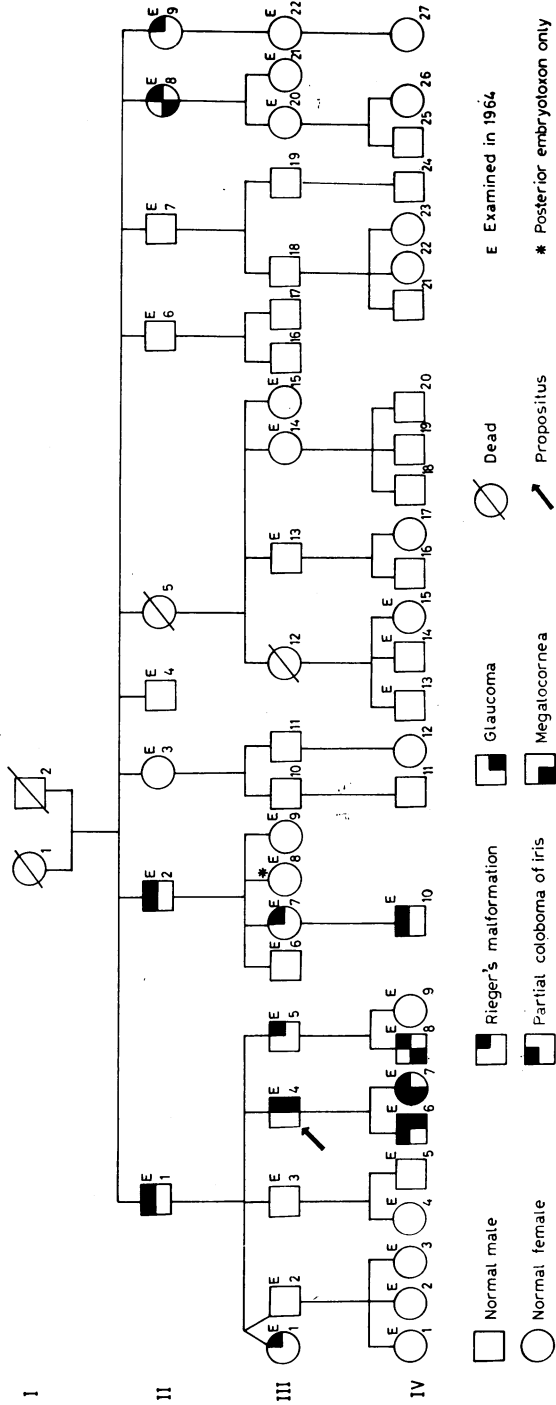


FIG. 1.—Pedigree of family with Rieger's malformation.

tion of visual acuity, fundus examination, photography of the anterior segment, slit-lamp examination, and (in those aged 6 years and over) applanation tonometry and gonioscopy.

Clinical Findings

The results are given in the Table. Twelve members had Rieger's malformation in both eyes. No abnormality of the fundus was noted and applanation tonometry readings were less than 17 mm. Hg. Gonioscopy showed that the angles of the anterior chamber were wide open in all members. Additional anterior chamber anomalies were detected as follows: partial coloboma of the iris in one eye in five patients; megalocornea in both eyes in three patients; glaucoma in three eyes in two patients. There was no evidence of ectodermal dysplasia on examination of the skin or hair, nor any relevant abnormality in the number, characteristics, and eruption of teeth. One man (II₂) had partial anosmia which was not congenital but secondary to atrophic rhinitis caused by gas warfare in 1917.

One woman (III₆) had a posterior embryotoxon in both eyes unaccompanied by any other ocular abnormality.

Genetic Findings

As shown in Fig. 1 every affected person in Generations III and IV had an affected parent. Excluding the propositus (III₄) and the deceased (II₅), the ratio of affected to unaffected in six sibships was 12 : 10, and among the affected the sex ratio was approximately equal, 5 females to 7 males. Therefore the malformation is due to an autosomal dominant gene with varying expression in the heterozygous state.

Discussion

In order to diagnose Rieger's malformation it is necessary to observe iris strands crossing the angle and the posterior embryotoxon to which they adhere. These structures are always visible on gonioscopy.

Anatomically, posterior embryotoxon is a prominence of the anterior border ring of Schwalbe (Allen and others, 1955). A prominent ring is quite commonly encountered in the eyes of normal persons with a frequency in the general population estimated at between 15 per cent. (Burian, Braley, and Allen, 1955) and 32 per cent. (Forsius, Eriksson, and Fellman, 1964). In the present study, one woman (III₆) had a posterior embryotoxon visible on gonioscopy, but in contrast to the twelve individuals with Rieger's malformation there were no adhesions between the embryotoxon and the iris root. Therefore this woman was regarded as showing the prominent border ring of normal individuals, and in the absence of adhesions she could not be classified as having the malformation.

In addition to the typical features of Rieger's malformation, other anterior chamber anomalies were found among the affected. Five of 24 eyes had a partial coloboma of the iris, giving the pear-shaped appearance previously described by Axenfeld (1920), Rieger (1935), Braendstrup (1948), and Paufique, Etienne, and Bonnet (1950). Partial colobomata present in two members of Generation II were not detected in their affected offspring, but reappeared in three members of Generation IV. In

TABLE
CLINICAL FEATURES OF AFFECTED MEMBERS OF FAMILY

Pedigree Number	Sex	Age in 1964 (yrs)	Visual Acuity	Posterior Embryotoxon Visible on External Slit-lamp Examination	Pupils	Iris Stromal Atrophy	Type of Adhesion bridging Angle from Iris Root to Trabecular Meshwork and Posterior Embryotoxon	Other Features
II ₁	M	65	R 6/5 L Counting fingers	Complete ring both eyes	R Central L Partial coloboma 3 o'clock	Marked	Broad	L divergent with immature senile cataract
II ₂	M	63	R 6/18 L Counting fingers	Complete ring both eyes, partially detached in right	R Central L Partial coloboma 10 o'clock	Very marked	Broad	L early immature senile cataract
II ₆	F	49	R 6/6 L 6/9	Nasal portion Right Temporal portion Left	Central	Slight	Fine	Megalocornea diameter 12.5 mm. both eyes
II ₉	F	50	R 6/5 L 6/5	Temporal portion both eyes	Central	Slight	Broad and fine	
III ₁	F	43	R 6/5 L Counting fingers	Complete ring both eyes	Central	Moderate	Broad and fine	L convergent squint since childhood
III ₄	M	36	R 6/6 L 6/6	Complete ring both eyes	Central (before operation)	Marked	Broad and fine	Bilateral glaucoma R Trepphine 1959 L Trepphine 1960
III ₅	M	32	R 6/5 L 6/5	Nil either eye	Central	Nil	Fine	
III ₇	F	37	R 6/5 L 6/6	Complete ring both eyes	Central	Slight	Broad and fine	
IV ₆	M	12	R 6/24 L 6/6	Complete ring both eyes	R partial coloboma 4 o'clock L central	Moderate	Broad and fine	L glaucoma Iridocyclitis 1961
IV ₇	F	10	R 6/6 L 6/6	Complete ring both eyes	R central L partial coloboma 7 o'clock	Moderate	Broad and fine	Megalocornea diameter 14 mm. both eyes
IV ₉	M	6	R 6/6 L 6/6	Complete ring both eyes	Central	Slight	Fine	Megalocornea diameter 13.5 mm. R, 13 mm. L
IV ₁₀	M	6	R 6/9 L 6/24	Complete ring both eyes	R central L partial coloboma 3 o'clock	Slight	Medium	
*III ₅	F	28	R 6/5 L 6/5	Nasal portion Right embryotoxon nasally L normal	Central	Nil	Nil	

* Normal variation in female without Rieger's malformation (see text)

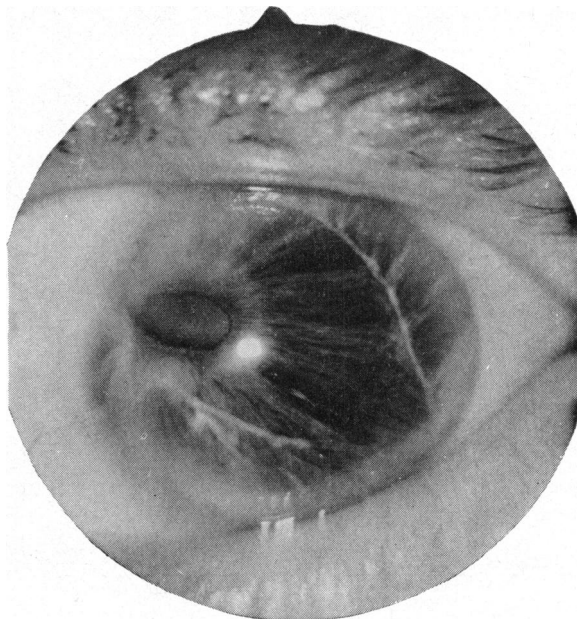


FIG. 2(a).—Left eye of II_2 , male aged 63 with partial coloboma at 10 o'clock, iris atrophy, and displaced posterior embryotoxon.

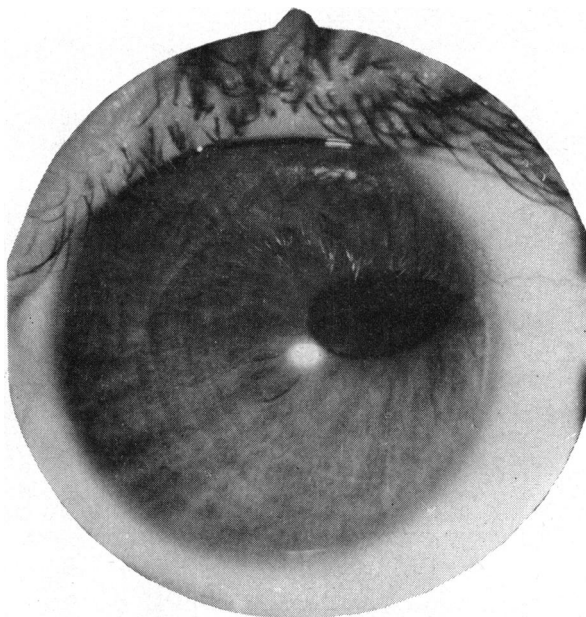


FIG. 2(b).—Left eye of IV_{10} , male aged 6 with partial coloboma at 3 o'clock and thickened posterior embryotoxon at apex of coloboma.

addition to this variability of expression, the anomaly was not confined to any particular segment of the iris. Two examples are given in Fig. 2. Displacement of the pupil results from traction on the pupil margin by adhesions running from the iris stroma to the prominent border ring of Schwalbe. A true slit-pupil is formed only if the points of attachment are symmetrically opposed (Rieger, 1935; Falls, 1949; Forsius and others, 1964). Corectopia results from pupil displacement when the points of attachment are within 180° of each other (Busacca and Pinticart, 1948; Falls, 1949; Collier, 1962).

The degree of iris hypoplasia appeared directly proportional to the quantity of adherent stroma observed bridging the angle. Hypoplasia was most marked in eyes with dense adhesions but was minimal when fine strands were seen in the region of the angle. Localized full-thickness iris atrophy producing significant defects in the iris (Falls, 1949; Kittel, 1956; Forsius and Eriksson, 1964) was not observed.

Glaucoma has been reported in patients with Rieger's malformation, occurring typically in eyes where angle dysgenesis was most marked (Rieger, 1935; Rossano, 1934; Gasteiger, 1939; Braendstrup, 1948; Kittel, 1956; Busch, Weiskopf, and Busch, 1960). However, the three glaucomatous eyes in the present series appeared to have iris adhesions no more dense than those without increased tension. One patient (IV₆) had had symptoms when 8 years old and can thus be classified as having "juvenile" glaucoma. There was no enlargement of the globe which would be expected if the onset had been at an earlier age. Despite a common developmental background, the angle abnormality in Rieger's malformation is different from that in true "congenital" glaucoma. Gallenga and Matteucci (1964) have proposed the term "congenital dysplasia of the irido-corneal angle" to emphasize the embryological relationship of these two dissimilar conditions.

Variations in corneal diameter have been reported with a frequency similar to glaucoma. Megalocornea was detected in five of ten patients by Burian, Rice, and Allen (1957) and in eight of twelve by Falls (1949), whereas microcornea appears to be less common (Kayser, 1922; Braendstrup, 1948). Three patients in the present series had megalocornea in both eyes with diameters ranging from 12.5 to 14 mm. (II₈, IV₇, IV₈).

The range and type of variation found in the present family has not been previously described. In particular, it appeared to be a random matter as to which combination of anomalies would occur in the offspring of affected persons, although there was an impression that density of iris adhesions remained fairly constant from one generation to the next. Varying expressivity of a dominant gene is of course well known in other conditions, such as Waardenburg's syndrome and osteogenesis imperfecta. The family described by Braendstrup (1948) is most similar to the present one in that seven affected members had classical features of Rieger's malformation, but in addition four had abnormalities in the posterior segment and two had microcornea. The family recorded by Burian and others (1957) differed in that only four of ten affected persons had posterior embryotoxon with iris adhesions. All twelve affected members of the family examined by Falls (1949) had Rieger's malformation, but five had additional ectodermal anomalies of the anterior segment including ectopia lentis.

Posterior embryotoxon in the absence of iris adhesions as detected in III_g (who had a 50 per cent. chance of being affected) cannot be entirely excluded as evidence of minimal gene expression. However, posterior embryotoxon is sufficiently frequent in the general population to have been observed in association with developmentally unrelated ocular abnormalities (Forsius, 1964). In addition, there has been no report of an affected parent of persons with Rieger's malformation who has not possessed the minimal diagnostic requirements of iris adhesions and posterior embryotoxon. In view of these observations it is probable that posterior embryotoxon in III_g represents a normal variation unrelated to the inherited malformation.

Rieger's malformation has been associated with disorders of dentition (Rieger, 1935; Lemmingson and Riethe, 1958), facio-mandibular dysgenesis (Kittel, 1956), and generalized features of ectodermal dysplasia (Gassler and Berthold, 1960). None of these anomalies was detected in the present study.

Summary

A family is described in which twelve members had characteristic features of Rieger's malformation. Additional anterior segment anomalies were detected in eight members (partial coloboma of iris in five eyes, megalocornea in six eyes, and glaucoma in three eyes), causing wide variation in clinical features. The malformation was due to a dominant gene with variable expression. One member with posterior embryotoxon and no iris adhesions was regarded as showing a variation present in about 15–30 per cent. of the normal population and unrelated to the gene for Rieger's malformation. Anomalies were localized to mesodermal derivatives of the anterior segment and there was no association with dental or ectodermal defects reported in previous family studies.

We are very grateful to Miss K. Major for assistance with locating and transporting members for investigation, and also to Mr. E. Allen, senior optician of the Oxford Eye Hospital, for photographic assistance. One of us (C.B.K.) was supported by the Post-Graduate Medical Foundation, University of Sydney.

REFERENCES

- ALLEN, L., BURIAN, H. M., and BRALEY, A. E. (1955). *Arch. Ophthalm. (Chicago)*, **53**, 783; 799.
 AXENFELD, T. (1920). *Ber. dtsh. Ophthal. Ges.*, **42**, 301.
 BRAENDSTRUP, J. M. (1948). *Acta ophthal. (Kbh.)*, **26**, 495.
 BURIAN, H. M., BRALEY, A. E., and ALLEN, L. (1955). *Arch. Ophthalm. (Chicago)*, **53**, 767.
 ———, RICE, M. H., and ALLEN, L. (1957). *Ibid.*, **57**, 651.
 BUSACCA, A., and PINTICART DE W. E. (1948). *Ophthalmologica (Basel)*, **115**, 283.
 BUSCH, G., WEISKOPF, J., and BUSCH, K. T. (1960). *Klin. Mbl. Augenheilk.*, **136**, 512.
 COLLIER, M. (1962). *Ann. Oculist. (Paris)*, **195**, 512.
 FALLS, H. F. (1949). *Amer. J. Ophthalm.*, **32**, no. 6, pt. 2, p. 41.
 FORSIUS, H. (1964). *Acta ophthal. (Kbh.)*, **42**, 97.
 ——— and ERIKSSON, A. (1964). *Ibid.*, **42**, 42.
 ———, ———, and FELLMAN, J. (1964). *Ibid.*, **42**, 68.
 GALLENGA, R., and MATTEUCCI, P. (1952). "Idroftalmo". *Cited by Duke-Elder, S.* (1964), vol. 3, pt 2, p. 558. Kimpton, London.
 GASSLER, H., and BERTHOLD, H. (1960). *Klin. Mbl. Augenheilk.*, **136**, 52.
 GASTEIGER, H. (1939). *Ibid.*, **102**, 876.
 HAGEDOORN, A. (1937). *Arch. Ophthalm. (Chicago)*, **17**, 223.
 KAYSER, B. (1922). *Klin. Mbl. Augenheilk.*, **68**, 82.
 KITTEL, V. (1956). *Ibid.*, **129**, 464.

- LEMMINGSON, W., and RIETHE, P. (1958). *Ibid.*, **133**, 877.
- MANN, I. (1933). *Brit. J. Ophthalm.*, **17**, 449.
- PAUFIQUE, L., ETIENNE, R., and BONNET, J. L. (1950). *Ann. Oculist. (Paris)*, **183**, 81.
- RIEGER, H. (1935). *Albrecht v. Graefes Arch. Ophthalm.*, **133**, 602.
- ROSSANO, R. (1934). *Bull. Soc. Ophtal. Paris*, **46**, 8.
- STREIFF, E. B. (1949). *Ophthalmologica (Basel)*, **118**, 815.
- WAARDENBURG, P. J., FRANCESCHETTI, A., and KLEIN, D. (1961). In "Genetics and Ophthalmology", vol. I, p. 570. Van Gorcum, The Netherlands.