

ELECTRO-OCULOGRAM FINDINGS IN PATIENTS TREATED WITH ANTIMALARIAL DRUGS*

BY

HELGA KOLB

Department of Experimental Ophthalmology, Institute of Ophthalmology, University of London

WITHIN the last few years it has become increasingly evident that the antimalarial drugs cause eye damage. First developed as a cure for malaria, these drugs are now widely used in the treatment of the chronic collagenoses for which the dosages are very large and may be prolonged for many years. In this time the drugs accumulate in the body and reach toxic levels. This often results in severe visual disturbances. Corneal deposits of the drugs may temporarily impair the optical properties of the eye, but are of minor importance as they are easily reversible when drug treatment ceases (Hobbs and Calnan, 1958; Zeller and Deering, 1958; Calkins, 1958; Hobbs and Calnan, 1959; Kersley and Palin, 1959; Pau, 1959; Rogers, 1959). However, in a small percentage of patients, permanent retinal damage may result. Many reports have appeared in the literature during the last 4 years describing the fundus appearance and visual defects associated with chloroquine retinopathy (Cambiaggi, 1957; Hobbs, Sorsby, and Freedman, 1959; Sternberg and Laden, 1959; Hobbs, Eadie, and Somerville, 1961; Ellsworth and Zeller, 1961; Rebello, 1961; Smith, 1962; Henkind and Rothfield, 1963).

The earliest sign of a retinopathy is said to be a pigmentary disturbance of the macula advancing to give the "bull's-eye" appearance (Henkind and Rothfield, 1963). The retinal changes often progress after discontinuation of therapy and visual acuity drops and central scotomata result. In advanced cases the arteries are attenuated and there may be peripheral pigmentation and considerable areas of field loss.

Examination of the fundus oculi gives no indication of the toxic effects of the drugs until irreversible damage has occurred. Also the earliest signs of the retinopathy are extremely difficult to assess.

Animal experiments and histopathological examination of human eyes, after long-term antimalarial therapy, have indicated that the drugs selectively damage the pigment epithelium and receptor cells of the retina (Potts, 1963; Wetterholm and Winter, 1964; Bernstein and Ginsberg, 1964).

* Received for publication January 5, 1965.

The electro-oculogram is a test of the efficiency of the pigment epithelium and rods of the human eye (Arden and Kelsey, 1962; Arden, Barrada, and Kelsey, 1962). It was considered that this test would prove a diagnostic tool for assessing the effects of antimalarial drugs on the retina (Arden, Friedmann, and Kolb, 1962).

This investigation was carried out to establish the efficacy of the electro-oculogram for detecting early drug damage to the retina before ophthalmoscopic changes were evident. In addition, other electrodiagnostic tests were performed on patients receiving antimalarials to confirm and extend the information provided by the electro-oculogram.

Investigation

Eighty patients were tested in this survey. This total can be divided in the following manner:

- 47 patients receiving antimalarials at the time of testing.
- 13 patients tested a few months after cessation of therapy.
- 4 patients with advanced chloroquine retinopathies.
- 7 patients with rheumatoid arthritis and 9 with chronic discoid lupus erythematosus who had never received antimalarials, provided 16 controls.

All these patients were tested repeatedly with the electro-oculogram (EOG). Details of the procedure and use of the EOG have been published elsewhere (Arden and Kelsey, 1962; Arden, Barrada, and Kelsey, 1962; Arden and Barrada, 1962).

In addition, some of the patients were investigated by the electroretinogram and dark-adaptation tests.

All the patients were examined periodically by an ophthalmologist, and tests included funduscopy and perimetry. The H-R-R colour plates and Amsler charts were shown to all the patients.

Electroretinography.—A large scleral contact lens was used and the recordings displayed on a Mingograph. The amplifier time constant employed was 2 seconds and top cuts could be used as desired. The stimulating light was a tungsten filament lamp (250 V) housed in a modified camera, with a hand-operated shutter. The single camera lens magnified the filament image to give an intense stimulus covering the whole pupil. Neutral density filters could be used to reduce the stimulating light intensity.

Dark-adaptation Tests.—The Goldmann-Weekers dark adaptometer was used. The flashing stimulus falls upon an 11° area of retina adjacent to the macula.

Results

Electro-oculography

Fig. 1 shows the frequency distribution of the EOG ratios of the total number of patients (47) receiving antimalarials at the time of testing, compared with the distribution for a group of 47 normal patients. It is evident that this is a skew distribution with extreme values at 140 and 270. Even the log transformation is too skewed to allow normal distribution statistics to be applied. The mean EOG value of the group is 187 SE 3.9 (mode 175). Compared with the normal mean (238 SE 3.7), the main bulk of the antimalarial group falls well outside normal limits, and in a pathologically low range.

Applying a *t* test to the normal and antimalarial groups $t = 9.0$ (significant to $P = 0.0001$ for 45 degrees of freedom). This is a highly significant difference.

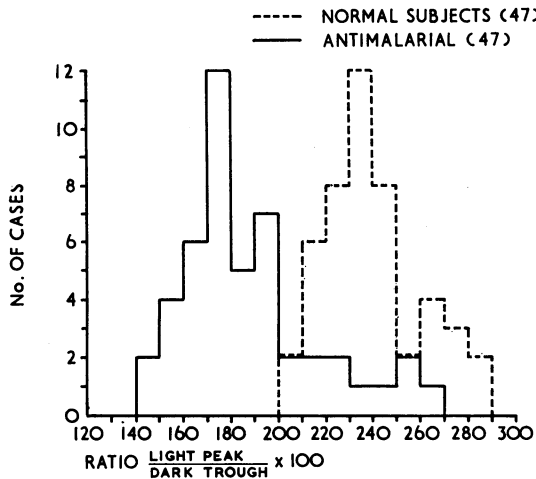


FIG. 1.—EOG ratios for 47 normal subjects and 47 antimalarial-treated patients. Linear plot.

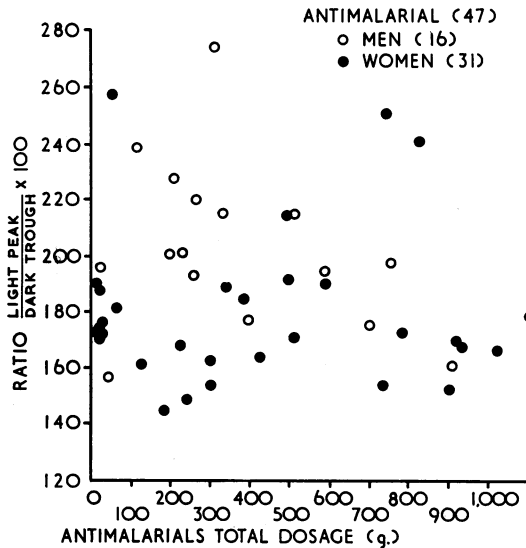


FIG. 2.—EOG ratios related to total dosage of antimalarial drug taken by each patient, by sex.

It was thought that the EOG ratios for patients taking antimalarials would be related to the total dosage of drugs received up to the time of testing, but no relationship could be established (Fig. 2). The correlation is insignificant; $R = -0.04$ for 45 degrees of freedom.

Even dividing the data into groups does not indicate a progressive decrease of the EOG with duration and increasing dosage (Table I).

TABLE I
EOG VALUES, BY DOSAGE GROUPS

Total Dosage (g.)	0-200	200-500	500+
Mean EOG Value	188	187	187
No. of Cases	16	15	16

These findings could mean that:

- (1) The EOG is depressed almost immediately antimalarial therapy begins.
- (2) The group is composed of too many variables that should be considered independently, *i.e.* sex, age, disease, individual tolerance.
- (3) Some factor other than the drug is contributing to the depression of the EOG in these patients.

There was no correlation between the EOG value and dosage for patients with rheumatoid arthritis only ($R = -0.013$; $N = 9$). Neither was there a correlation between EOG and dosage for patients with chronic discoid lupus erythematosus ($R = -0.101$; $N = 38$).

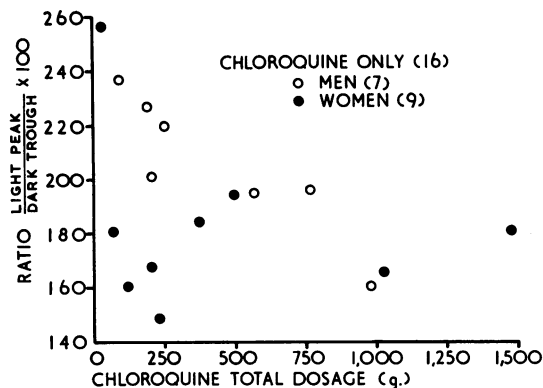


FIG. 3.—EOG ratio related to total dosage for patients who had taken chloroquine only, by sex.

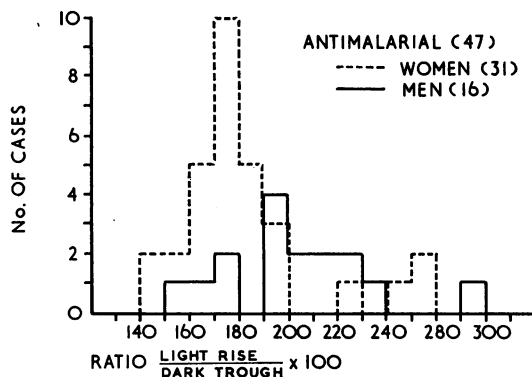


FIG. 4.—EOG ratios for 16 men and 31 women on antimalarial therapy. Linear plot.

No correlation could be established for EOG/age for patients taking the drug.

Most of the patients tested had received all the commonly used antimalarials at some time or other, and unfortunately it was not possible to assess the effects of each individual drug separately.

Sixteen patients of the total antimalarial-treated group had received only the single antimalarial, chloroquine (Fig. 3). The correlation coefficient is insignificant ($R = -0.286$; significant to $P = 1.5$). The results in this group, small though it is, do not differ from those in the large group of patients treated with a combination of the various drugs. In fact, there is no reason to suppose that any one antimalarial differs from the others in its overall effect on the eye. Possibly some drugs react somewhat faster than others, but the end-result is undoubtedly the same.

Sex Differences in the EOG Value.—When Figs 2 and 3 are considered carefully, it is apparent that the EOG values for male patients lie in a higher range than those for female patients.

Fig. 4 shows the frequency distribution and it is evident that all the women lie within the range 140–200 (mean 179), whereas the largest proportion of men lie between 200 and 240 (mean 203). The scatter is greater in the male group, possibly due to the smaller sample size.

A *t* test applied to these two groups showed a highly significant difference between them ($t = 2.8$, which for 45 degrees of freedom is significant to $P > 0.001$).

These results suggest that the antimalarial drugs affect men and women differently.

Controls.—Nine patients with chronic discoid lupus erythematosus and seven with rheumatoid arthritis acted as controls for comparison with the patients taking antimalarials. In all cases the EOG was tested twice to eliminate the possible error of a single recording.

Fig. 5 shows the frequency distribution of these sixteen untreated controls compared with the 47 patients treated with antimalarials and the 47 normal subjects. The controls lie within the range of the lowest limit of normal (mean 200 SE 11.1).

A *t* test applied to the EOG values of the normal/control groups and drug-treated/control groups gave the results shown in Table II.

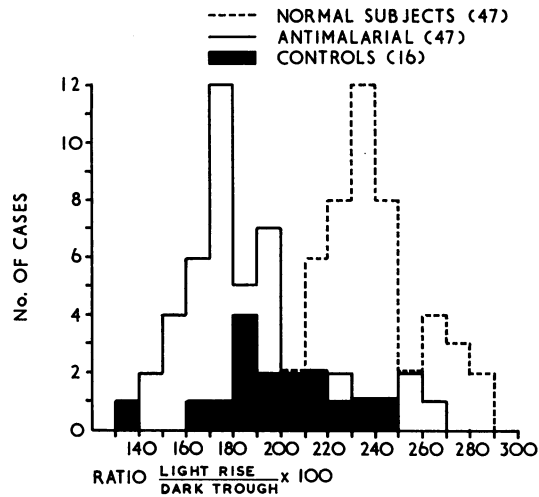


FIG. 5.—EOG ratios for 47 normal subjects, 16 control untreated patients, and 47 patients on antimalarial therapy. Linear plot.

TABLE II
SIGNIFICANCE OF RELATIONSHIP BETWEEN FUNCTIONS MEASURED

Variables	No. of Patients	<i>t</i>	Significance (per cent.)
Normal Subjects/Untreated Controls	60	6.1	1
Antimalarial Treated/Untreated Controls	60	1.4	15

For the small number of controls tested the results indicate that this is a significantly abnormal group of the population. It is tempting to explain this by suggesting that these patients' collagenoses are affecting the eye.

The difference between the controls and the patients treated with antimalarials is not significant, but this is probably because there are too many variables affecting the results. In this same series of results the patients with lupus erythematosus proved to have an even lower mean EOG value (mean 192) than those with rheumatoid arthritis (mean 208).

It is only in the cases of rheumatoid arthritis that a significant difference between untreated and treated patients emerges:

Rheumatoid Patients		
Untreated	Antimalarial Treated	
Mean EOG Ratio	Mean EOG Ratio	Mean Total Dosage (g.)
208	175	250

The difference between the two means is statistically significant; $t = 2.2$; significance $P = 0.05$ for 10 degrees of freedom.

Thus it can be seen that the effect of the antimalarials on the EOG is more strikingly evident if homogeneous groups are studied and it is only in this manner that the evidence has statistical significance.

Difference between Patients with Chloroquine Retinopathies and those without Retinopathies.—In a later section of the results the ophthalmoscopic findings are dealt with and the number of patients having severe and early retinopathies described.

A t test carried out on the EOG findings of patients with early and advanced retinopathies compared with those of patients without retinopathies revealed the statistically significant difference in EOG values shown in Table III.

TABLE III
EOG FINDINGS IN PATIENTS WITH AND WITHOUT RETINOPATHY

Mean EOG		t	Significance
Patients with Retinopathy	Patients without Retinopathy		
166	193	3.0	$P = 0.01$

A comparison of the EOG, the state of the retina, and the total amount of drug ingested, gave the following results:

Retinopathy	Mean EOG	Mean Dosage (g.)
Present	159	515
Early	171	493
Absent	193	343

Although the earlier results have not shown a statistical EOG/dosage relationship, the grouping of the results in this manner indicates a progressive decrease in the EOG with increasing retinal damage.

Improvement of the EOG on Withdrawal of Drug Therapy

(1) *Patients treated while taking the Drug and at Intervals after Cessation of Treatment.*—Twenty-five cases were closely followed by serial EOG testing, and the following results were observed:

- 11 (44 per cent.) improved steadily to reach normal values (Fig. 6).
- 7 (28 per cent.) improved rapidly during the first 2 months but then declined.
- 3 (12 per cent.) remained unchanged over a period of 6 months.
- 4 (16 per cent.) showed a decrease in the EOG value.

The findings in the seven cases in which the EOG eventually declined in value was at first puzzling, until five of them were found to be in extreme exacerbation of their disease. One of these cases is summarized below and in Fig. 7.

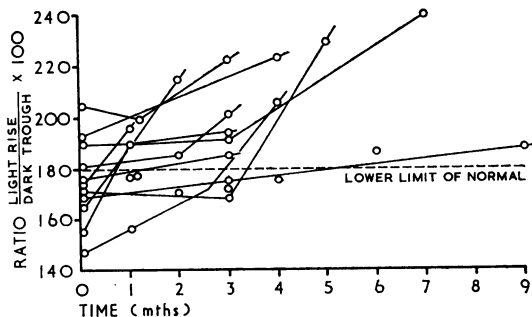


FIG. 6.—Improvement in the EOG value when anti-malarial therapy was discontinued in 11 cases. Dotted line shows lower limit of normal EOG value.

A 63-year-old woman with chronic discoid lupus erythematosus had received over 900 g. of various antimalarials during the preceding 8 years. When first seen she was taking Propoquin, 200 mg. daily. On withdrawal of this drug the EOG showed some improvement within a month. Camoquin (250 mg. daily) was then administered and within 3 months the EOG had fallen to pathologically low values and fundus examination revealed early macular pigment mottling. Therapy was discontinued and within the month the EOG had risen to normal values, but it fell again to the lower limit of normal soon afterwards. At this time the patient suffered a very marked exacerbation of the skin disease; she requested to be treated with Camoquin again and this resulted in an improvement of the skin lesion but a further fall in the EOG to pathological values.

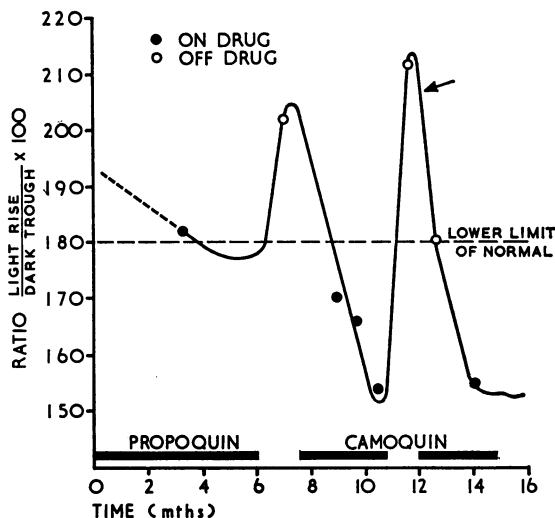


FIG. 7.—Serial EOG ratios in a single patient. The EOG returns to normal levels when drug therapy is discontinued. A large fall in the EOG ratio (arrowed) is probably due to recrudescence of the collagen disease. Pathological EOG values are recorded when the patient is receiving an antimalarial drug, particularly Camoquin.

(2) *Patients who had received Extensive Courses of Antimalarials in the Past.*—Thirteen patients were sent to the electrodiagnostic clinic for assessment by the EOG although they were no longer receiving antimalarials. These patients were tested at

least twice. Fundus and field examinations were performed but none showed any signs of a retinopathy. The total amount of antimalarial drugs ingested in the past was known. Table IV summarizes the EOG findings. The mean EOG of this group is 208, and is significantly higher than that of patients currently on antimalarials.

TABLE IV
EOG FINDINGS IN PATIENTS RECEIVING ANTIMALARIALS AND THOSE NO LONGER TAKING DRUGS

<i>t</i>	Mean EOG		Significance
	Patients on Antimalarials	Patients at least 6 mths after Antimalarial Treatment	
3.18	187	208	P = 0.001

Results of Electroretinography and other Tests

Particular attention was paid to cases of early and severe retinopathies and patients with low EOG readings. The number of ERGs recorded was too small for detailed statistical analysis, but some interesting facts emerged.

The frequency distribution of *a* and *b* wave amplitude in microvolts of patients receiving antimalarials is compared with the normal distribution in Fig. 8. It is apparent that the amplitudes of the *a* and *b* waves overlap to a greater extent in the drug-treated patients.

In four cases with definite chloroquine retinopathy the ERG waveform was abnormal with an enlarged *a* wave and a reduced *b* wave. In the severest retinopathy, where the EOG showed no light rise at all, the *a* wave was absent and the *b* wave was only 30 μ V in amplitude.

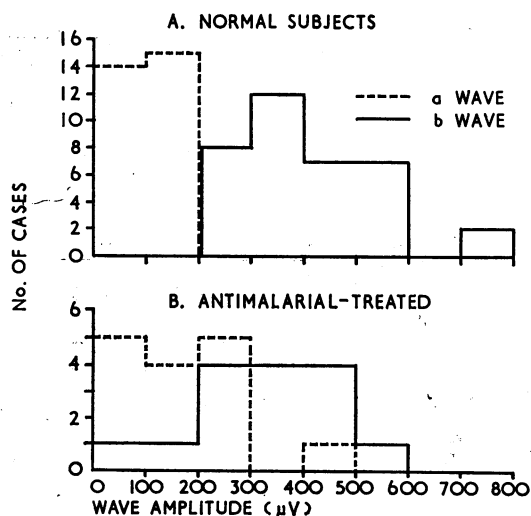


FIG. 8.—Distribution of *a* and *b* waves in normal electroretinograms (A) and in antimalarial-treated patients (B).

In nine cases with early macular changes the ERG was suggestive of retinal pathology. The *a* waves were enlarged and the *b* waves slightly reduced compared with normal values.

In seven other patients with no fundus changes, who had received extensive courses of antimalarials, the ERGs ranged from normal to an unusual waveform with enlarged *a* waves. The results are summarized in Table V.

TABLE V
MEAN VALUES OF *a* AND *b* WAVES COMPARED WITH NORMAL WAVEFORMS

Cases Tested		Normal Subjects	Patients Treated with Antimalarials		
			Retinopathies (4)	Macular Changes (9)	No Fundus Changes (7)
Wave Forms	Mean Size <i>b</i> Wave (scotopic)	393 μ V	229 μ V	241 μ V	397 μ V
	Mean Size <i>a</i> Wave (scotopic)	111 μ V	109 μ V	106 μ V	217 μ V
	<i>a</i> Wave as Percentage of <i>b</i> Wave	28 per cent.	48 per cent.	44 per cent.	55 per cent.
Mean Total Dosage of Antimalarial (g.)		0	515	493	412

The first sign of antimalarial toxicity appears as an increasing negativity of the ERG, *i.e.* the *a* wave becomes deeper. At the stage of an early retinopathy both *a* and *b* waves are reduced in amplitude (to the lower normal range). When retinopathy develops a further decrease in the *b* wave has occurred and the *a* wave is absent. The final stage is seen in a severe retinopathy in which the *b* wave is reduced to a minimal electro-positive deflection.

No statistical correlation of the ERG amplitude with drug dosage has been attempted, although the mean dosages for the groups suggest a possible relationship between dosage and ERG.

Ophthalmoscopic Findings

(1) In all four of the patients currently receiving antimalarials who were found to have definite retinopathies (Table VI), the EOG was grossly depressed, or even flat as in Case IV. Dark adaptation and the ERG were affected in all but Case I, in which the retinopathy was localized to a macular degeneration only. Case III is interesting in that the EOG rose to normal values within 3 months of withdrawal of the drug; this case also showed no changes in the fundus although there were definite scotomata and a drop in visual acuity.

(2) Nine of the other forty-three patients currently receiving antimalarials proved to have macular changes which were considered to be due to drug therapy. In all these the antimalarials were immediately withdrawn and the patients examined routinely. Table VII summarizes the findings in these cases.

Case 2 was the most severely affected, the macula resembling the typical "bull's eye" lesion. This patient has been followed for over 18 months and has had no

TABLE VI
FINDINGS IN FOUR PATIENTS WITH CHLOROQUINE RETINOPATHY

Case No.	Age (yrs)	Sex	Drug	Total Dosage (g.)	Visual Acuity	Visual Fields	Fundus	ERG	Dark Adaptation	EOG
I	50	F	Ch*	500	Right 20/30 Left 20/25	Pericentral and central scotomata H-H-R plates not seen	Patchy depigmentation of macula No foveal reflex	Right eye b wave 270 μ V a wave 120 μ V } scotopic	Normal	R 151
II	74	M	Ch	200 +	Right 6/9 Left 6/24 corrected	Peripheral fields constricted Central field L eye constricted to 5°-10° Dark-adapted fields Bilateral marked ring scotoma	Attenuated arteries	No increase in b wave with dark adaptation b wave 300 μ V } scotopic a wave 275 μ V }	Monophasic, high	R 153 L 140
III	32	F	Ch	1,000	Right 6/60 Left 6/9	Right bits of ring scotoma Dark-adapted fields, marked depression of central fields, R ring scotoma to 5°	Keratopathy No fundus defect	Slow increase of b wave with dark adaptation Scotopic b wave 315 μ V Scotopic a wave 45 μ V Photopic a wave 175 μ V	Biphasic R eye elevated 2 LU above normal L eye elevated 1 LU	Off chloroquine 3 mnths later R 185 R 250 L 165 L 228
IV	36	F	Ch	360	Right 6/9 Left 6/9 2 years later Right 6/24 Left 6/24	Central scotoma Ring scotoma breaking through to periphery Colour blindness	Pa ₁ discs, narrow arteries Pigment around macula	Minute b wave 30 μ V No a wave No change with dark adaptation	Biphasic L eye elevated 2 LU R eye elevated 1½ LU	No change with light

* Ch = Chloroquine

TABLE VII
FINDINGS IN NINE PATIENTS WITH EARLY CHLOROQUINE RETINOPATHIES

Case	Age (yrs)	Sex	Drugs	Total Dosage (g.)	Visual Acuity	Visual Fields	Symptoms	Fundus	Dark Adaptation	ERG	EOG R L
1	49	F	Ch* Pr†	730	Right 6/5 Left 6/4 corrected	Amsler blurring around central spot	Blurring Sees double flashes and bright spots	Macular mottling Early "bull's-eye" No foveal reflex	Slightly elevated	Scotopic b wave 296 μ V Scotopic a wave 92 μ V	166 164
2	35	F	Ch* Pr† Ca§	930 +	Right 6/6 Left 6/9 corrected	No defect	None	"Bull's-eye" macula	Normal		170
3	63	F	Ch Pr Ca Pr	900 +	Right 6/6 Left 6/6 corrected	No defect	None	Slight macular mottling			155
4	62	F	Ch	1,012	Right 6/5 Left 6/5	No defect	None	Hudson-Stahli line Macular pigmentation Absent foveal reflex			160 175
5	44	M	Ch Pr Ca Pr Ca	700	Right 6/24 Left 6/6	No defect	Photophobia Difficulty in reading	Macular pigmentation	Normal	Scotopic b wave 150 μ V Scotopic a wave 30 μ V	180 171
6	57	F	Ch Pr	420	Right 6/9 Left 6/9 corrected	Constricted	Flashes and blurring Difficulty in reading Colour defect	Pale discs	Elevated I LU	b wave 250 μ V a wave 60 μ V	167 177
7	41	F	Pr Ch Pr	582	Right 6/12 Left 6/12 corrected	Central field constricted	Blurring	Pigment mottling of maculae Some peripheral pigmentation	Normal	b wave 310 μ V a wave 150 μ V	198 186
8	52	F	Pr	180	Right 6/6 Left 6/6 corrected	No defect	Difficulty in reading	Dotted pigment at macula			146
9	49	F	Ch	1,643	Right 6/6 Left 6/18 corrected	No defect	Blurring and muzziness	Absent foveal reflex Pigment stippling			184 180

* Ch = Chloroquine † Pr = Plaquenil ‡ Pr = Propoquin § Ca = Camoquin || Bitemporal recording

visual symptoms at any time. The EOG rose to within lower limits of normal 6 months after withdrawal of drug therapy. The macula has since become a more pronounced "bull's eye" and some peripheral pigmentation has appeared.

Case 7 is interesting in that she showed a definite diminution in visual acuity, a slight central field defect, and some peripheral pigmentation as well as the early "bull's eye" lesion. She complained of slight reading difficulty only. The EOG was within the range of the lower limit of normal while she was still receiving anti-malarial treatment. On cessation of treatment the EOG rose very rapidly to normal values.

Case 9 showed progressive visual deterioration after chloroquine therapy was stopped. Visual acuity fell during the following 3 months from 6/6 both eyes to 6/9 in the right eye and 6/18 in the left eye with correction. The fundus was at first thought to be suspicious but not definitely abnormal. In the following 3 months the EOG deteriorated and the macula became more obviously pigmented as in the early "bull's eye" lesion.

The results of these fundus examinations have revealed some interesting points about early and late chloroquine retinopathies:

(i) Some patients show definite visual field defects unaccompanied by ophthalmoscopic changes in the fundus oculi.

(ii) "Bull's eye" lesions of the macula may occur with no visual disturbance.

(iii) The "bull's eye" lesion may progress after discontinuation of drug therapy, and may be accompanied by a decrease in visual acuity and an increase in pigmentation of the peripheral fundus.

(iv) In most cases of early retinopathy, even where visual field defects are detectable, the EOG improves from pathological to normal values within 9 months of cessation of drug therapy.

Discussion

EOG Values of Patients taking Antimalarial Drugs

It is now well known, from various animal investigations and from pathological examination of human eyes, that chloroquine or its metabolites accumulate in the ocular tissues (Zvaifler, Bernstein, and Rubin, 1962; Bernstein, Zvaifler, Rubin, and Mansour, 1963; Wetterholm and Winter, 1964; Bernstein and Ginsberg, 1964). As the EOG is a test of retinal function, the fact that the values have been proved to be abnormally low in all patients undergoing antimalarial therapy suggests that it may measure drug toxicity.

Particular evidence of the effect of antimalarial therapy on the eye is provided by the comparison of a group of rheumatoid patients receiving chloroquine with a similar group who had never received any antimalarials. The difference in mean EOG values appears too great to be explained by factors other than the effect of the drug on the retina.

Therefore, the most important conclusion to be drawn from this investigation is that the accumulation of antimalarials in the retina is indicated by the abnormally low EOG values recorded for all patients undergoing drug therapy.

EOG in Patients with Collagen Diseases

Drug toxicity does not appear to be the sole explanation of the pathologically low values recorded in all the patients. Even patients who have never received antimalarials have lower than normal EOG ratios. These findings are inexplicable unless the basic collagen disease is considered to be the underlying cause.

We may, therefore, be dealing with two interacting factors resulting in low EOG values in drug-treated patients—the basic pathology of the collagen disease and the toxic effect of antimalarial drugs on the retina.

The low EOG values recorded in patients with untreated collagen disease may indicate some deficiency in the metabolism of the pigment epithelium rod complex, and the striking decrease in the EOG that occurs when patients have an exacerbation of their disease suggests a flare-up of the collagen disease factors influencing the retinal metabolism directly or indirectly.

In patients with lupus erythematosus an anti-DNA antibody is present as is evidenced by the L.E. phenomenon. There is a possibility that some inhibition of the DNA system is also occurring in the cells of the retina. The relatively frequent finding of lupus retinopathy in untreated patients (25 per cent. according to Ballantyne and Michaelson, 1962) suggests some underlying pathology. In addition, ocular lesions associated with rheumatoid arthritis occur in 6 per cent. of patients (Smith, 1957) in the form of uveitis, keratitis, episcleritis, choroiditis, and (rarely) retinal detachment. Electron-microscopy has shown that the capillaries of the dermis are grossly disorganized in patients with collagen diseases (Alexander, Slocumb, and Brown, 1964). It is possible that such pathology is widespread in the choriocapillaris.

The ocular manifestations of the collagen diseases must not be confused with the retinopathy directly due to antimalarial toxicity. Before these drugs came into use there was no report in the literature of retinal changes in any way resembling chloroquine retinopathy. However, an interesting point is that so far no research workers have managed to produce a retinopathy in animal eyes, perhaps because normal undiseased eyes are being used as a test for antimalarial toxicity. It could be that the changes associated with chloroquine retinopathy only become apparent when the drugs are acting upon a retina which already has some underlying metabolic pathology.

The EOG and Total Drug Dosage

No correlation between EOG ratio and drug dosage could be established in this investigation. This is an unexpected finding because it was assumed that the EOG would decrease in value as the accumulation of the drug or its metabolite in the retina gradually increased. The explanation of the inability to establish an EOG/dosage relationship for the total number of patients must lie in the heterogeneity of the sample. Unfortunately, when the patients are subdivided to eliminate as many of the variables as possible, the groups become too small to allow good statistical analysis. Nevertheless, some interesting results emerged when these subgroups were considered, and the reasons for the poor total group analysis became obvious.

One of the most significant variables was the difference in EOG ratios found in men compared with women. The average EOG for men receiving antimalarials

was considerably higher than that for women. This may mean that antimalarial drugs have more pronounced toxic effects on women. The collagenoses primarily affect women patients but the aetiology is not yet established. Both rheumatoid and L.E. factors have a specificity for certain gamma globulins, which are possibly female sex-linked or even hormone-controlled.

The total group comprised patients taking Camoquin, Mepacrine, chloroquine, or hydroxychloroquine. All these drugs have different toxicities and thus a statistical analysis will not prove any EOG/dosage relationship if all the patients are considered in one group. The difficulty is further increased by the fact that the greatest proportion of the patients had received most of the commonly used antimalarials at some time or other. When a small group receiving chloroquine alone was studied, a correlation of EOG ratio compared with total drug dosage was found to be significant only to the 15 per cent. probability level.

The variability of drug dosage for each individual must also be a cause of the inconsistent EOG findings. It is known from rat experiments that tissue uptake of chloroquine does not have a linear relationship to dosage. A 3-fold increase of drug ingestion results in as much as a 20-fold increase in drug deposition in the tissues of the body. Cannot the same effect be occurring in human therapy? No consideration of body weight is taken into account in antimalarial therapy at present. Unfortunately not enough information was provided with each patient in this survey to allow a body weight/dosage analysis to be carried out. It is obvious that a small person may in effect be taking greater dosages of the drugs compared with a larger person taking the same amount. Also a great proportion of patients undergoing antimalarial therapy suffer loss of weight in consequence, so that, if the patient is maintained on the same dosage, he will be ingesting relatively increasing amounts of the drug. This would explain the number of retinopathies described in the literature when the patient has taken what seems to be a small amount of antimalarial drug. If an EOG/dosage relationship is ever to be proved, a carefully controlled group of patients of the same age, sex, and disease, and with a constant ratio of dosage to body weight must be studied. The extreme difficulty of such an analysis is obvious.

EOG Ratios for Patients with and without Retinopathies

Although it has not been possible to prove by statistical analysis that the EOG decreases in value relatively with increased dosage of antimalarials, gross averaging of the data has revealed some positive results. The patients are noted to fall into three groups, showing a progressive decline in the EOG values from patients without retinopathies to patients with severe retinal changes. The mean dosage shows a corresponding increase. There is, in fact, a statistical difference between patients with ophthalmoscopically evident changes and those without, indicating that the EOG value decreases as damage to the retina increases.

It must be emphasized that this is by no means a conclusion that can be applied to every case undergoing antimalarial therapy, because the variations are too great. It appears that the final stage of EOG deterioration, in severe retinopathies, is a flat EOG as in Case IV of Table VI in this investigation (Arden and Fojas, 1962), and in less severe retinopathies, where much of the peripheral field is still intact, minimal light rises are recorded.

In cases with early macular changes (referred to as early retinopathies in this survey) the EOG value is on average lower than in patients with no changes. The latter can have EOGs ranging from low normal to grossly abnormal values, and these do not seem to bear any relationship to the duration of therapy or the total amount of drug ingested.

The dosage/retinopathy relationship appears to be as variable as the EOG/dosage relationship. With the present system of antimalarial therapy it is impossible to suggest a limiting dosage beyond which a particular patient is more likely to develop a retinopathy. The mean dosage calculated for the cases of retinopathy in this survey is 515 g., which closely coincides with the mean dosage calculated from the cases reported in the literature.

Improvement of the EOG on Cessation of Drug Treatment

Arden, Friedmann, and Kolb (1962) reported on a patient whose EOG reading improved from subnormal to normal values when chloroquine therapy was discontinued. Therefore, in this investigation, a number of patients was tested periodically after cessation of antimalarial treatment in order to establish whether the EOG always showed such improvement.

In a proportion of the patients treatment was discontinued at our suggestion, because of EOG values that were considered to be grossly abnormal. Most of these showed progressive improvement of the EOGs, in a linear fashion, and reached normal values within a few months of cessation of treatment. There was some individual variation in the time needed for the return to normal but the average result indicates a gradual improvement over a 9-month period.

A few of the patients showed an immediate rise in the EOG ratio followed by a dramatic fall associated with recrudescence of their collagen disease.

Even patients with macular changes showed a reversibility of the EOG value, but this did not necessarily correspond with an improvement of the macula.

These results explain the findings of Gouras and Gunkel (1963), who reported the EOG to be normal in cases of mild retinopathy, in which the visual field defects did not involve large areas of peripheral retina. However, their cases were tested one year after discontinuation of antimalarial therapy.

In this investigation it was also possible to test a group of patients who had not received antimalarials for at least 6 months before testing. Their EOGs were in the low normal range. It is thus apparent that the majority of patients show an improvement of the EOG ratio to normal levels within 6 to 12 months of the cessation of antimalarial treatment.

The ERG and other Tests

The ERG changes seen in this survey closely agree with those described by Schmidt and Müller-Limmroth (1962). The first sign of antimalarial damage to the retina is indicated by an enlarged *a* wave. This is seen in patients without ophthalmoscopic evidence of changes in the retina who have received an average dosage of 343 g. of antimalarial drugs, but it is also noted in patients who have received as little as 200 g. In patients with early macular changes both the *a* and *b* waves are usually reduced in amplitude, and in patients with moderate to severe retinopathies the

ERG is correspondingly reduced. The final stage in a severe retinopathy (Case IV in Table VI) is a minute pathological ERG, with extreme reduction of both photopic and scotopic systems.

Dark adaptation was usually normal in cases with macular changes and was abnormal only in severe retinopathies. Colour testing revealed no changes except in two cases with central field defects and in patients with advanced retinopathies. Okun, Gouras, Bernstein, and von Sallmann (1963), consider colour loss to be an early sign of retinopathy, but only one of the patients in this survey can be compared with any of their cases.

It seems unlikely that electroretinography, dark adaptation, or colour testing will give any indication of the onset of a chloroquine retinopathy, or be considered of great diagnostic use as screening tests. However, in combination with the electro-oculogram and fundus examination, these tests may provide increased information on the extent of antimalarial damage to the retina.

Funduscopy revealed that the earliest changes occurred at the macula in most patients. These changes took the form of pigmentation or mottling and early "bull's eyes", as described by Henkind and Rothfield (1963). It is possible that loss of foveal reflex is an even earlier sign that precedes the eventual pigmentary disturbance. However, a minority of the patients investigated showed visual field defects with no macular changes. It must still be borne in mind that chloroquine retinopathy does not always begin at the macula, a fact that is further substantiated by the few cases reported in the literature.

Theoretical Conclusions to be Drawn from the Data

The results of this investigation have shown some interesting theoretical possibilities. The abnormally low EOG values recorded in most drug-treated patients suggest that the antimalarials affect the pigment epithelium and the receptors. However, a combination of the drugs and some underlying metabolic deficiency due to the basic collagen disease may be giving rise to a more pronounced effect on the EOG.

The improvement of the EOG in most cases when drug therapy is discontinued suggests that the pigment epithelium is relinquishing the drug, although small areas of rods and cones may be irreversibly damaged. This would explain the normal EOGs seen in cases of field defect and mild retinopathies when the drug has been discontinued. The very earliest sign of antimalarial damage to the retina is a reduction of the EOG ratio very soon after the commencement of therapy. The drug probably accumulates in the pigment epithelium, upsetting the metabolism of the rods and visual purple cycle. The next stage would be damage to the receptors in small localized areas. One of the earliest ophthalmoscopic signs is the appearance of pigment dispersion at the macular region forming the so-called "bull's eye". At this stage the damage is still localized to isolated regions of the retina and the EOG is reversible when therapy is stopped. Later, if the drug treatment is continued, greater and greater areas of retina are involved in widespread damage, and field defects become apparent. There may be obvious macular changes in an asymptomatic patient until an irreversible central scotoma results. Some patients may show peripheral pigmentation and field defects at first, rather than macular damage.

The ERG findings suggest damage to both rods and cones.

The antimalarial drugs appear to cause widespread damage to the receptors throughout the retina at the final stage of the retinopathy. This is probably because these drugs have an affinity for pigment cells and interfere with the metabolism of the pigment epithelium and photopigments of the rods and cones.

The Electro-oculogram as an Electrodiagnostic Tool in Detecting Chloroquine Retinopathy

The diagnostic efficacy of the EOG as the *sole* means of detecting the onset of a chloroquine retinopathy has not been proved by the results of this investigation. It is a sensitive test of the early accumulation of antimalarials in the retina, but the values are too varied in each individual for any limit to be considered indicative of an imminent retinopathy. The EOG may be only doubtfully pathological in cases with early retinopathies. Henkind, Carr, and Siegel (1964) report normal EOGs in some cases with macular lesions, although this was not seen in the present study.

However, it is suggested that the results of EOG testing combined with thorough ophthalmoscopic examination may prove to be of value, especially in cases in which the diagnosis is doubtful. Unfortunately, there is still much individual difference of opinion among ophthalmologists concerning which are the earliest signs of retinopathy, so that an objective measure of the retinal deterioration is still essential.

The EOG has obvious advantages over the ERG for this purpose and is a short test, comfortable and easy for the patient. However, as has been proved by this survey, the variations are too great for the result of a single test to provide any useful information. If a pre-drug baseline value of the EOG were established for all patients about to begin antimalarial therapy, the usefulness of the EOG as a diagnostic tool would be greatly increased. The progress of the EOG deterioration can then be followed for each patient during therapy in combination with thorough examinations of the fundus oculi.

The EOG alone may be useful for assessing the results of intermittent courses of therapy, where it might indicate the progressive accumulation of the drugs in the retina. The gradual decrease in EOG value could be followed to a level at which it was considered pathological (say 170), and therapy could then be interrupted for a while, and the improvement of the EOG followed until the drug therapy could safely be resumed.

This work was supported by a grant from Bayer Ltd.

The author is indebted to Dr. Paul Henkind for valuable help in performing the ophthalmoscopic examinations, to Dr. Anne Maguire for providing the patients for this survey, and to Dr. G. B. Arden for criticism and advice.

REFERENCES

- ALEXANDER, S. T., SLOCUMB, C. H., and BROWN, A. L. (1964). *Arthr. and Rheum.*, **7**, 286.
 ARDEN, G. B., and BARRADA, A. (1962). *Brit. J. Ophthalm.*, **46**, 468.
 ———, ———, and KELSEY, J. H. (1962). *Ibid.*, **46**, 449.
 ——— and FOJAS, M. R. (1962). *Arch. Ophthalm. (Chicago)*, **68**, 369.
 ———, FRIEDMANN, A., and KOLB, H. (1962). *Lancet*, **1**, 1164.
 ——— and KELSEY, J. H. (1962). *J. Physiol. (Lond.)*, **161**, 189; 205.
 BALLANTYNE, A. J., and MICHAELSON, I. C. (1962). "Textbook of the Fundus of the Eye", Livingstone, Edinburgh.

- BERNSTEIN, H. N., and GINSBERG, J. (1964). *Arch. Ophthalm. (Chicago)*, **71**, 238.
- , ZVAIFLER, N., RUBIN, M., and MANSOUR, A. (1963). *Invest. Ophthalm.*, **2**, 384.
- CALKINS, L. L. (1958). *A.M.A. Arch. Ophthalm.*, **60**, 981.
- CAMBIAGGI, A. (1957). *Ibid.*, **57**, 451.
- ELLSWORTH, R. J., and ZELLER, R. W. (1961). *Ibid.*, **66**, 269.
- GOURAS, P., and GUNKEL, R. D. (1963). *Ibid.*, **70**, 629.
- HENKIND, P., CARR, R. E., and SIEGEL, I. M. (1964). *Ibid.*, **71**, 157.
- and ROTHFIELD, N. F. (1963). *New Engl. J. Med.*, **269**, 433.
- HOBBS, H. E., and CALNAN, C. D. (1958). *Lancet*, **1**, 1207.
- , ——— (1959). *A.M.A. Arch. Derm.*, **80**, 557.
- , EADIE, S. P., and SOMERVILLE, F. (1961). *Brit. J. Ophthalm.*, **45**, 284.
- , SORSBY, A., and FREEDMAN, A. (1959). *Lancet*, **2**, 478.
- KERSLEY, G. D., and PALIN, A. G. (1959). *Ibid.*, **2**, 886.
- OKUN, E., GOURAS, P., BERNSTEIN, H., and VON SALLMANN, L. (1963). *Arch. Ophthalm. (Chicago)*, **69**, 59.
- PAU, H. (1959). *Ber. dtsh. ophthalm. Ges.*, **62**, 285.
- POTTS, A. (1963). "The Pharmacodynamics of Drugs". Talk given at the Armed Forces National Research Council, Committee on Vision, Washington, D.C., May 9-10, 1963.
- REBELLO, D. J. A. (1961). *A.M.A. Arch. Derm. Syph.*, **83**, 785.
- ROGERS, P. A. (1959). *Aust. J. Derm.*, **5**, 10.
- SCHMIDT, B., and MÜLLER-LIMMROTH, W. (1962). *Acta ophthalm. (Kbh.)*, suppl. 70, p. 245.
- SMITH, J. L. (1957). *Amer. J. Ophthalm.*, **43**, 575.
- (1962). *Arch. Ophthalm. (Chicago)*, **68**, 186.
- STERNBERG, T. H., and LADEN, E. (1959). *A.M.A. Arch. Derm. Syph.*, **79**, 116.
- WETTERHOLM, D. H., and WINTER, F. C. (1964). *Arch. Ophthalm. (Chicago)*, **71**, 82.
- ZELLER, R. W., and DEERING, D. (1958). *J. Amer. med. Ass.*, **168**, 2263.
- ZVAIFLER, N., BERNSTEIN, H. N., and RUBIN, M. (1962). *Arthr. and Rheum.*, **5**, 667.