

## THE "CAVERNOUS" SINUS\*

BY

M. A. BEDFORD

*Moorfields Eye Hospital, London*

THE cavernous sinus is a vascular channel of great importance not only in ophthalmology but in many other branches of medicine. Descriptions of its structure are scattered in books and journals on ophthalmology, otorhinolaryngology, paediatrics, and dentistry as well as in the standard anatomical works. However, the descriptions of the sinus and its contents show great variation and it is the purpose of this paper to clarify the matter.

Probably the earliest description of this sinus was by Ridley (1695), who placed the internal carotid artery against the lateral wall, "leaving no room at all for either blood or serum to be contained there". He noted with regard to the artery "a little interstice between itself and the pituitary gland", and how this venous space communicated with that of the opposite side. The term "circular sinus" was suggested in his book, a name still sometimes applied. The presence of the fibrous trabeculae was first noted by Winslow (1732), but his description of the other structures is not clear: "The internal carotid is bathed in the blood of the sinus together with the third, fourth, fifth and sixth pairs of nerves." It was Winslow who likened the interior of the sinus to that of the corpus cavernosum of the penis and applied the term "cavernous", which has been used ever since.

The classic description is that of a blood-filled channel completely surrounding the horizontal portion of the internal carotid artery and the sixth (abducent) nerve as they pass anteriorly on either side of the sella turcica (Fig. 1). In addition to these two structures, the lumen of the cavernous sinus is usually described as being crossed by numerous fibrous laminae, termed trabeculae, and always depicted as a dense, interlacing mass. This description of the artery, the sixth nerve, and the trabeculae is given in most books dealing with anatomy: Thane (1892), Whitnall (1921), Sobotta (1928), Huber (1930), Spalteholz (1933), Wood Jones (1949), Wolff (1954), Boileau Grant (1958), and in the many applied and clinical works: Mosher (1914), Turner and Reynolds (1926), Campbell (1933), Fabricant (1933), Pace (1941), Herzig (1945), Orton (1947), Elfman (1950), Shaw (1952), Hollinshead (1954), Last (1959), and Duke-Elder (1961). Indeed, the presence of the trabeculae has

---

\* Received for publication February 1, 1965.

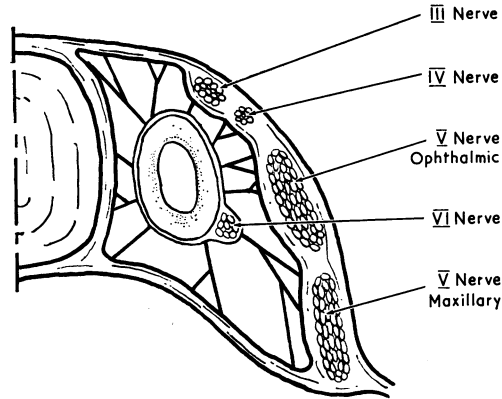


FIG. 1.—Transverse section of the “classical” cavernous sinus, showing the internal carotid artery and sixth nerve passing through a densely trabeculated venous channel.

been stressed by many authors, particularly those authors of papers of a clinical nature—Campbell (1933) stated: “the numerous interlacing bands . . . which considerably narrow and retard the current of blood”, and Pace (1941) noted “the bands are so numerous as almost to filter out the corpuscles”. A more moderate view is expressed by Duke-Elder (1952), who states that “the peculiar structure of the sinus goes far to explain its undoubted tendency to favour the lodgment of thrombi”. Hollinshead (1954) concurs with this idea of the trabeculae “contributing to the likely formation of a thrombus”. However, in one of the most recent textbooks, Davies and Davies (1962), after giving the usual description, note that the presence of the trabeculae has been doubted, citing Butler (1957).

Further differences of opinion are noted with regard to the precise position of the internal carotid artery and the abducent nerve. Thus Brash (1951) places these structures in the lateral wall of the sinus, and Weizenhoffer (1932) places the artery in the medial wall. Other authorities place the abducent nerve in the lateral wall, being separated from the artery by a gap (like the other cranial nerves, III, IV, and V), (Poirier and Charpy, 1901; Hovelacque, 1927; Weinberger, Adler, and Grant, 1940; Taptas, 1949; Thorek, 1951; and Bonnet, 1955). All, however, agree on the presence of the trabeculae.

Bonnet (1955) states that the cavernous sinus as such does not exist and that the space between the two layers of dura is filled up with the internal carotid artery surrounded by a plexus of veins and nerves. In other words, the trabeculae seen in section are merely the cut walls of numerous small veins. This concept is endorsed by Bétoulières, Boudet, Paleirac, Garbay, and Lonjon (1957), whose radiographic techniques after the injection of a radio-opaque dye showed several types of venous plexus around the internal carotid artery. Previously, MacNeal, Frisbee, and Blevins (1943) and Olivier and Papamiltiades (1951) had cited this view, with the additional qualification that the venous plexus only completely surrounded the internal carotid artery in a minority of cases.

Butler (1957), in the paper already quoted, could find no trabeculae in foetal sinuses and only a few in the adult sinus that he sectioned; there were no trabeculae

in the cavernous sinuses of rats that he examined. This emphasized some previous work by Eyster (1944), who reported that there were no trabeculae in the Rhesus monkey, and also that the main venous sinus was entirely medial to the internal carotid artery. Baló (1950), in histological studies, could find no true cavernous tissue in the walls of the human cavernous sinus.

In view of these varied concepts and differing opinions, it was decided to investigate the anatomy of the human cavernous sinus with special regard to the following features:

- (1) The presence or absence of laminae within the lumen of the cavernous sinus and, if present, whether they were trabeculae in the classic sense or were, in fact, the walls of numerous small veins.
- (2) The position of the internal carotid artery and the abducent nerve in relation to the dural walls.

#### Method

Thirty-four cavernous sinuses were examined macroscopically after the removal of the roof and the upper part of the lateral wall, the subjects' ages ranging from 23 to 90 years. In addition, 3 pairs of foetal sinuses (from foetuses aged 16, 20, and 26 weeks respectively) were examined with the additional aid of a dissection microscope.

#### Results

(1) *Trabeculation.*—There is no doubt that the laminae present in the sinuses are best described as trabeculae and not as the walls of adjacent veins. In no instance was there the impression of looking into a plexus of vessels, and the less dense the trabeculae the less was this likely. In only 6 of the adult sinuses examined (18 per cent.) did the density of the trabeculation resemble the text-book description. Most sinuses (64 per cent.) had a few trabeculae running inferiorly from the medial side of the internal carotid artery to the floor of the cavernous sinus. The remaining 18 per cent. had few, if any, trabeculae. Thus, the cavernous sinus was virtually an unbroken venous channel in 80 per cent. of the sinuses examined.

The foetal material showed no apparent trabeculation.

(2) *The Internal Carotid Artery and the Abducent Nerve.*—These two structures were in the sinuses in only 8 per cent. of all the adult specimens examined, whilst the great majority (77 per cent.) showed that the internal carotid artery and the sixth nerve were manifestly outside the lumen of the sinus. In fact, the medial side of the artery formed the lateral boundary of the sinus proper. The remaining 5 sinuses (15 per cent.) showed a slight gap between the artery and the nerve, with the latter only in the lateral wall being immediately medial to the ophthalmic branch of the trigeminal nerve.

The foetal sinuses were interesting in that the entrance of the internal carotid artery through the floor of the sinus was very much more anterior than that of the adult. It appeared at the junction of the anterior and middle thirds along the antero-posterior axis of the sinus and then passed obliquely upwards to the medial side of the anterior clinoid process. It was clearly in the sinus, as was the abducent nerve, which was looping loosely around its lateral aspect. In addition, the artery was relatively much narrower, being about one and a half times the width of the abducent nerve.

### Discussion

It would be reasonable to attribute the differences between the foetal and adult positions of the internal carotid artery to the following factors:

(1) At birth and afterwards the artery greatly increases its diameter for purely haemodynamic reasons.

(2) With the growth of the skull and eruption of teeth there is a relative backward movement of the carotid canal.

These processes produce a vessel which enters the sinus farther back in the adult, and because of its increased diameter, its lateral side adheres to the dural walls with the sixth nerve, making the definitive sinus entirely medial to the artery. The shallow curve of the abducent nerve in the foetus compared with the sharper curve of the adult would seem to support this view.

The absence of trabeculae in the foetal material could not be taken for certain owing to the relatively gross methods of dissection for such a small area. Histological sections would supply the only accurate answer, and it is interesting that Butler (1957) found no trabeculae in his studies.

There was no apparent relationship between the different positions of the internal carotid artery and the density of the trabeculae. All the trabeculae appeared to run from the internal carotid artery inferiorly and may well serve as supports for its fine collateral branches, as mentioned by Taptas (1949).

The X-ray studies of Bétoulières and others (1957), showing several types of venous plexus, were acknowledged to be difficult to interpret, but their findings could be correlated with the presence of only a few trabeculae when it is realized that the flow of blood carrying the radio-opaque dye is almost certainly laminar in type. Thus, once the stream has been split by even one trabeculum, the appearance would surely be that of several veins.

### Conclusion

The results of these dissections show that it is erroneous to consider this sinus as "cavernous" in structure, and it is certainly incorrect to consider it as obstructive in nature and so predisposing to thrombus formation. It could be argued that only the sinus with dense trabeculae would undergo thrombosis, but it is interesting to note that the sections reproduced by Turner and Reynolds (1926) in their studies on cavernous sinus thrombosis show few trabeculae (and, incidentally, the internal carotid artery in the lateral wall).

Of course, as in the rest of the body, there is some variation in structure, but this series of dissections shows that from the anatomical and didactic point of view the internal carotid artery and the sixth cranial nerve form the lateral boundary of a single narrow venous channel, across which pass a few trabeculae inferiorly (Fig. 2).

Indeed, it would appear that as the trabeculae are so insignificant in the majority of subjects, there is a case for deleting the term "cavernous" from the description of this sinus. The "orbito-temporal" sinus would emphasize its connexions, but perhaps Ridley's suggestion of the "circular sinus", now two hundred and seventy years old, is more acceptable for its chronological superiority.

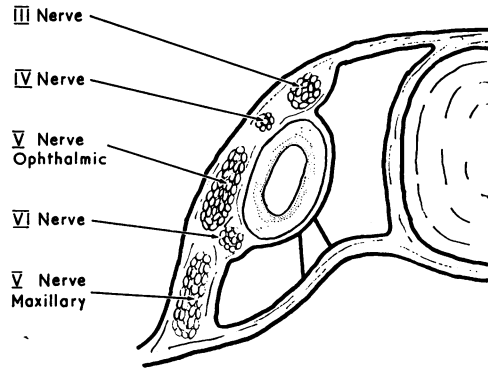


FIG. 2.—Transverse section of "cavernous" sinus showing venous sinus medial to internal carotid artery and with very few trabeculae.

### Summary

The relevant literature describing the cavernous sinus is briefly reviewed and the differences noted.

Details of a series of 40 dissections are presented.

It is shown that in four-fifths of the specimens examined trabeculae were virtually non-existent, and that the sixth cranial nerve lies in the lateral wall of the cavernous sinus.

My thanks are due to Professor A. J. E. Cave and Dr. O. J. Lewis, of St. Bartholomew's Hospital Medical College, for their help and encouragement in the preparation of this paper.

### REFERENCES

- BALÓ, J. (1950). *Anat. Rec.*, **106**, 319.
- BÉTOULIÈRES, P., BOUDET, C., PALEIRAC, R., GARBAY, B., and LONJON, P. (1957). *J. Radiol. Électrol.*, **38**, 726.
- BONNET, P. (1955). *Arch. Ophthal. (Paris)*, n.s. **15**, 357.
- BRASH, J. C. (1951). "Cunningham's Text-book of Anatomy", 9th ed., p. 1347. Oxford University Press, London.
- BUTLER, H. (1957). *J. Anat. (Lond.)*, **91**, 510.
- CAMPBELL, E. H. (1933). *Ann. Otol. (St Louis)*, **42**, 51.
- DAVIES, D. V., and DAVIES, F. (1962). "Gray's Anatomy", 33rd ed., p. 880. Longmans, London.
- DUKE-ELDER, S. (1952). "Text-book of Ophthalmology", vol. 5, p. 5445. Kimpton, London.
- (1961). "System of Ophthalmology", vol. 2, p. 477. Kimpton, London.
- ELFMAN, L. K. (1950). *Arch. Otolaryng.*, **51**, 185.
- EYSTER, A. B. (1944). *Anat. Rec.*, **90**, 37.
- FABRICANT, N. D. (1933). *Arch. Otolaryng.*, **17**, 635.
- GRANT, J. C. BOILEAU (1958). "A Method of Anatomy", 6th ed., p. 634. Williams and Wilkins, Baltimore.
- HERZIG, A. J. (1945). *Laryngoscope (St Louis)*, **55**, 318.
- HOLLINSHEAD, W. H. (1954). "Anatomy for Surgeons", vol. 1, p. 15. Cassell, London.
- HOVELACQUE, A. (1927). "Anatomie des nerfs craniens et rachidiens et du système grand sympathétique chez l'homme", p. 151. Doin, Paris.
- HUBER, G. C. (1930). "Piersol's Human Anatomy", 9th ed., p. 872. Lippincott, Philadelphia.
- LAST, R. J. (1959). "Anatomy, Regional and Applied", 2nd ed., p. 662. Churchill, London.
- MACNEAL, W. J., FRISBEE, F. C., and BLEVINS, A. (1943). *Arch. Ophthal.*, **29**, 231.
- MOSHER, H. P. (1914). *Laryngoscope (St Louis)*, **24**, 709.

- OLIVIER, F., and PAPAMILTIADES, M. (1951). *C. R. Ass. Anat.*, **38**, 769.
- ORTON, H. B. (1947). *Laryngoscope (St Louis)*, **57**, 294.
- PACE, E. (1941). *Arch. Otolaryng. (Chicago)*, **33**, 216.
- POIRIER, P., and CHARPY, A. (1901). "Traité d'anatomie humaine", 2nd ed., vol. 2, pt 3, p. 966. Masson, Paris.
- RIDLEY, H. (1695). "The Anatomy of the Brain", p. 39. Smith and Walford, London.
- SHAW, R. E. (1952). *Brit. J. Surg.*, **40**, 40.
- SOBOTTA, J. (1928). "Atlas of Human Anatomy", from 6th German ed. by J. Playfair McMurrich, vol. 3, p. 600. Stechert, New York.
- SPALTEHOLZ, W. (1933). "Hand Atlas of Human Anatomy", vol. 2, 7th ed., p. 459. Lippincott, Philadelphia.
- TAPTAS, J. N. (1949). *Sem. Hôp. (Paris)*, **25**, 1719.
- THANE, G. D. (1892). "Quain's Elements of Anatomy", 10th ed., vol. 2, pt 2, p. 523. Longmans, London.
- THOREK, P. (1951). "Anatomy in Surgery", p. 58. Lippincott, Philadelphia.
- TURNER, A. LOGAN, and REYNOLDS, F. E. (1926). *J. Laryng.*, **41**, 73.
- WEINBERGER, L. M., ADLER, F. H., and GRANT, F. C. (1940). *Arch. Ophthal. (Chicago)*, **24**, 1197.
- WEIZENHOFFER, A. (1932). *N. Y. St. J. Med.*, **32**, 139.
- WHITNALL, S. E. (1921). "The Anatomy of the Human Orbit", 1st ed., p. 316. Frowde and Hodder and Stoughton, London.
- WINSLOW, J. B. (1732). "Exposition anatomique de la structure du corps humain", vol. 2, p. 31. Prevost, London.
- WOLFF, E. (1954). "The Anatomy of the Eye and Orbit", 4th ed., p. 379. Lewis, London.
- WOOD JONES, F. (1949). "Buchanan's Manual of Anatomy", 8th ed., p. 1047. Ballière, Tindall and Cox, London.