

## UNILATERAL VITILIGO IRIDIS\*

BY

B. SHUKLA, S. P. SRIVASTAVA, AND S. C. JAIN

*Department of Ophthalmology, Gajra Raja Medical College, Gwalior, India*

THE delicate tissue of the iris is atrophied in a number of conditions, such as chronic iridocyclitis, chronic glaucoma, iridodialysis, adherent leucoma, xeroderma pigmentosum, essential progressive atrophy of the iris, and in old age. The iris is bleached out and appears grey or greyish-white. The delicate markings on the anterior surface disappear and the blood vessels are dilated. Pupillary margin is thinned out with diminished reaction, and the iris tissue becomes fragile. However, the picture differs considerably, depending on the cause, and in some cases white circular patches of uniform size appear; this condition is called vitiligo iridis.

Vitiligo iridis commonly results from variola infection (smallpox) and is due to circumscribed effacing of the iris pigment, resulting in rounded white spots on its anterior surface. Xeroderma pigmentosum may also give rise to a similar appearance (Fuchs, 1923). Loewenstein and Foster (1945) also observed this condition in patients affected by smallpox. Krückman described this condition in tuberculous iridocyclitis, and Roelofs found it after an attack of herpes zoster ophthalmicus (see Zeeman, 1949).

### Case Report

**Case 1.**—A boy aged 20 years presented with the complaint of gradual loss of vision in both eyes for the last six years. There was no history of any trauma or local inflammation. He had had smallpox at the age of 6 and remained healthy thereafter.

#### *Examination*

*Right eye.*—Vision 4/60. External examination revealed no abnormality. Ocular movements and tension were normal. Iris showed normal colour and pattern with brisk pupillary reactions.

*Left eye.*—Vision 5/60. Conjunctiva, cornea, and the anterior chamber were normal. Multiple greyish-white circular spots varying from 1 to 2 mm. were seen on the anterior surface of the iris. On higher magnification ( $\times 40$ ) with a slit lamp these spots appeared to be situated in a depression with punched-out margins. A few brown pigment particles were seen on the anterior lens capsule (see Figure).

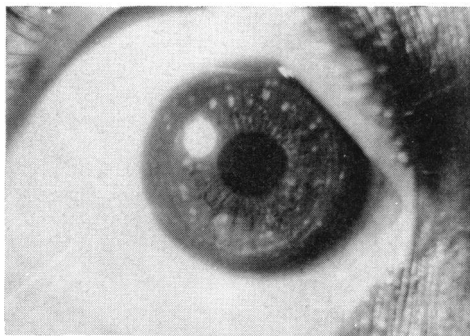


FIGURE.—Case 1, left eye. Iris shows circular white patches.

\* Received for publication May 10, 1965.

*Funduscopy.*—The fundi were myopic and showed tessellation and temporal crescents in both eyes.

*Retinoscopy.*—With  $-5.50$  D sph. and  $-5.0$  D sph. for the right eye and left eye respectively the vision improved to 6/6 in each eye.

**Case 2.**—The second patient was observed during an eye camp at Bhind and unfortunately could not be photographed. He was aged 50 years and was admitted with the complaint of gradual loss of vision in the right eye for the last ten years. He also gave a definite history of smallpox in childhood.

*Examination*

*Right eye.*—Vision was hand movements. Scarring in the upper palpebral conjunctiva was present and Herbert's pits were seen at the upper limbus. Mature cataract was present. Numerous circular greyish-white spots were seen scattered on the iris. Pupillary reactions were normal. Slit lamp examination could not be done. Concomitant divergent squint of  $15^\circ$  was present.

*Left eye.*—Vision 6/12. Scarring in the palpebral conjunctiva and Herbert's pits was prominent. Bitot's spots were seen near the outer limbus. Iris pattern and pupillary reactions were normal.

*Funduscopy.*—The right eye fundus could not be seen because of lenticular opacity; the left eye fundus revealed no abnormality.

### Conclusions

Two cases of vitiligo iridis are reported here, both of them having a definite history of smallpox. In both of them the condition was seen in one eye only, the other being normal. It is a rare condition, showing white or greyish-white circular spots of uniform size on the iris surface. Smallpox appears to be a common cause, and there appears to be a predilection for unilateral affection. The disease is symptomless.

### Summary

Two cases of unilateral vitiligo iridis are reported with smallpox as the probable aetiological factor.

### REFERENCES

- FUCHS, E. (1923). "Text-Book of Ophthalmology", 7th ed., pp. 668-669. Lippincott, Philadelphia.  
KRÜCKMANN. Cited by W. P. C. Zeeman (1949).  
LOEWENSTEIN, A., and FOSTER, J. (1945). *Brit. J. Ophthalm.*, **29**, 277.  
ROELOFS. Cited by W. P. C. Zeeman (1949).  
ZEEMAN, W. P. C. (1949). In "The Eye and its Diseases", ed. C. Berens, 2nd ed., p. 512. Saunders, Philadelphia.