

## COMMUNICATIONS

### RETINAL CYSTS AND RETINOSCHISIS\*

BY

C. G. KEITH

*Department of Pathology, Institute of Ophthalmology, University of London*

SINCE the term retinoschisis came into common ophthalmological parlance, it has often been used as though the condition were a definite entity, differing from retinal cysts by the process by which it arose. This has caused a considerable amount of confusion, and a review of the literature on the subject suggests that some clarification and definition of the terms used in describing cystic appearances of the retina is needed. Furthermore, consideration of the different types of retinal cysts that have been described reveals a certain amount of ambiguity in the writings of earlier authors on this subject and, in an attempt to reduce this, a new classification is suggested. This is based on a study of the literature and examination of 144 sections of eyes at the Institute of Ophthalmology, London.

A retinal cyst may be defined as a fluid-filled space in or derived from the retina, the diameter of which is greater than the thickness of the normal retina (Fig. 1). It is not necessarily a true cyst in the pathological sense, which must be lined by epithelium and have a discrete wall.

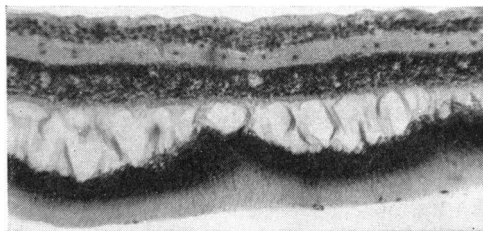
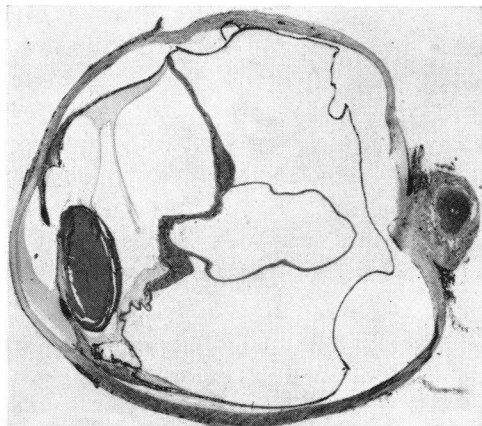


FIG. 2.—Cystic degeneration of the retina. Haematoxylin and eosin.  $\times 60$ .

FIG. 1.—Retinal cyst in a detached retina. Haematoxylin and eosin.  $\times 2.5$  (approx.).

Cystic change or cystoid degeneration of the retina (Fig. 2) is characterized by multiple small cavities, of which the diameter is less than the thickness of the normal retina. These can develop into retinal cysts as a result of retinoschisis.

\* Received for publication June 29, 1965.

Retinoschisis is really the name of a process, not a condition, but it is commonly used when referring to the cysts which arise by this process, particularly as senile retinoschisis (Fig. 3). It may be defined as a splitting which occurs in the layers of the retina bounded by the internal and external limiting membranes, which gives rise to fluid-filled spaces and is one of the mechanisms by which retinal cysts are formed. This process may occur between any of the layers of the retina derived from the inner part of the optic cup; it thus differs from a retinal detachment in which the sensory retina is separated from the pigment epithelium, restoring the primary optic vesicle.

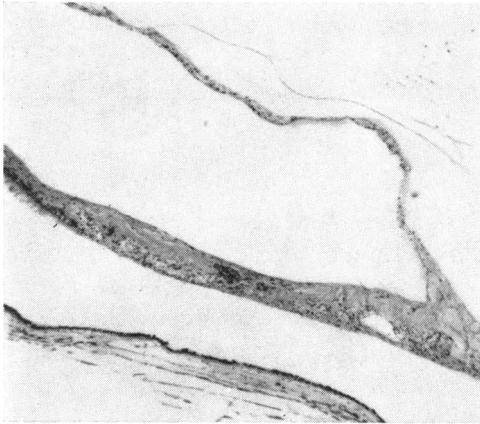

FIG. 3.—Retinoschisis. The retina is split into two layers. Haematoxylin and eosin.  $\times 45$ .

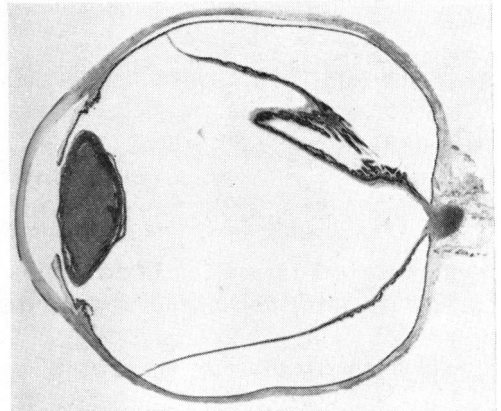


FIG. 4.—Pseudocyst formed by retinal folds in a detached retina. Haematoxylin and eosin.  $\times 2.5$  (approx.).

A pseudocyst of the retina (Fig. 4) is a fluid-filled space, the walls of which are formed partly or entirely by the whole thickness of the retina, and is due to reduplicated folds of the retina becoming adherent to each other, or by a layer of connective tissue enclosing a space between itself and the retina.

The term primary cyst is often used without any clear meaning, but, in the opinion of the author, it should be restricted to those cysts which arise from congenital epithelial rests of cells which later grow and become cystic.

The cystic changes in many of the eyes reported were seen on examination of a section of the eye, so that the cyst may, in fact, have been incomplete if seen in three dimensions.

One of the first descriptions of cystic changes in the retina was made by Iwanoff (1864). Nettleship (1872) described a retinal cyst following a choroido-retinal adhesion. Neame (1920) suggested a clinical classification and Fuchs (1921) a pathological one which remained in general use until Hruby (1956) published a more comprehensive review, particularly in regard to macular cysts. Other authors have presented schemata for considering the different types of retinal cysts (Veil and Guillaumat, 1938; Duke-Elder, 1940; François and Lambrechts, 1952), and certain details of these will be discussed later, but there does not seem to be a fully satisfactory way of grouping the different types of retinal cysts so that they may be considered under an aetiological, descriptive, or pathological classification, and most schemes combine all these categories. The following classification is suggested by the author as being simpler and more comprehensive than other schemes in use.

## RETINAL CYSTS

## (1) CONGENITAL

- (a) Associated with colobomata, microphthalmos, or dysplasia.
- (b) Congenital vascular veils in the vitreous, associated with retinal detachment (also called congenital retinoschisis).
- (c) Hyaloid remnants.
- (d) Primary cysts.

## (2) ACQUIRED

- (a) Formed by the processes of cystic degeneration and retinoschisis, caused or aggravated by the following factors:
  - (i) Age.
  - (ii) Retinal detachment.
  - (iii) Choroiditis.
  - (iv) Vascular lesions.
  - (v) Trauma.
- (b) Formed by other processes:
  - (i) Parasitic cysts.
  - (ii) Cysts occurring in the phakomatoses. } These may be primary cysts.
  - (iii) Cysts occurring in Coats's disease. }
  - (iv) Macular cysts. Some of these occur as a result of the processes in (a). They have not been studied in this survey, but Hruby (1956) considered them in detail.
  - (v) Cysts of unknown aetiology.

## (1) CONGENITAL

Cysts associated with congenital cystic eyes, microphthalmos, colobomata, and dysplasia are well described in the texts on developmental abnormalities (Mann, 1957a; Duke-Elder, 1964a).

Congenital vascular veils in the vitreous were first termed "retinoschisis" by Jager (1953). In this condition, thin transparent membranes are found in the vitreous, with retinal vessels running on them. The veils are usually in the periphery, but Goodside (1960) described one case in a 33-year-old man, in which the veil occurred over the macula. It has been suggested (Juler, 1947; Sorsby, Klein, Gann, and Siggins, 1951) that they are caused by the rupture of retinal cysts, but the difficulty of accepting this explanation is that there are large vessels running in the retina, external to the veils. Since large retinal vessels lie only in the superficial layers of the retina, they should only be found in the inner layers of the walls of the retinal cysts, which would presumably give rise to the veil, but should not be present in the remaining part of the retina forming the outer wall of the cyst. In two cases personally examined, a vessel branched directly into the vitreous from a retinal vessel, while other branches continued in the plane of the retina. They are unlikely to be due to remnants of the hyaloid system, as these are not connected with branches of the central retinal artery. Mann (1957b) suggested that they are caused by vitreous adhesions becoming vascularized, and did not think that they were due to schisis because there is no field defect unless retinal detachment occurs. Congenital vascular veils are said to be caused by a hereditary defect which is sex-linked and recessive (Sorsby and others, 1951; Sorsby, 1955; Balian and Falls, 1960). Sorsby considers congenital vascular veils in the vitreous to be associated with disinsertion of the retina in young people, falciform folds, and congenital retinal detachment, but falciform folds are thought by some authorities to be due to retrolental fibroplasia. It is possible that all these abnormalities are caused by vitreous adhesions, in one case pulling up a fold of retina, in another causing a total detachment or becoming vascularized, though the origin of the actual veil is still unexplained. There does not seem to be sufficient evidence to postulate retinoschisis in these cases, and the older name of congenital vascular veils in the vitreous is preferred.

Cysts caused by hyaloid remnants are usually anterior to the optic disc (Mann, 1957c) and are not really retinal cysts.

Primary cysts of the retina have already been defined. Duke-Elder (1938) thought that they were very rare and questioned the aetiology of a case reported by Heine (1904). François and Lambrechts (1952) described cysts occurring in the retina and divided them into primary and secondary; the latter are similar to other schemata, but these authors held that the primary cysts form in the thickness of an otherwise normal retina, and represent a new formation which is benign and primitive. According to these authors, primary cysts are of two types:

- (a) Cysts of the ora serrata which give rise to retinal detachments;
- (b) Other cysts of variable size which are not related to retinal detachment.

Cysts of the ora serrata which give rise to retinal detachments were first postulated by Weve (1936). Disinsertion of the retina at the ora serrata (Fig. 5) is the commonest cause of retinal detachment in young people, and Weve first drew attention to the presence of cysts in these disinsertions (Fig. 6). He thought that it was caused by a cyst which probably arose from a congenital nest of cells at the ora serrata. This condition is sometimes called "juvenile retinoschisis", and Duke-Elder (1964b) suggested that it might be due to the persistence of the primary optic vesicle; this, however, cannot, by definition, be called retinoschisis, but is a localized detachment. Vogt (1936) thought that the disinsertions were caused by peripheral cystic degeneration.

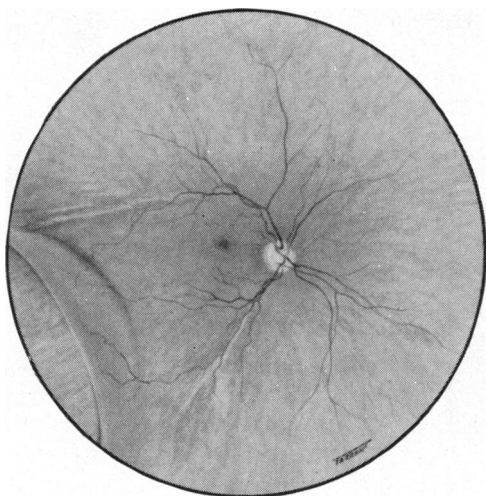


FIG. 5.—Retinal disinsertion.

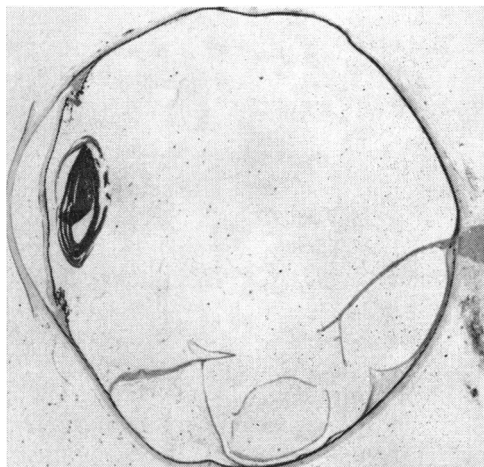


FIG. 6.—Retinal cysts associated with a long-standing retinal detachment. Haematoxylin and eosin.  $\times 2.5$  (approx.).

Retinal disinsertions were studied by Anderson (1932) and more recently by Leffertstra (1948, 1950). The latter reviewed 200 cases seen at Weve's clinic. The peak age of incidence was 20 years, and it was very rare after the age of 45. Trauma was the cause in about 42 out of 200 cases. In 83 per cent. of the non-traumatic cases the tear was in the lower temporal quadrant, the site of predilection of peripheral cystoid degeneration. Anderson thought that most of the cases of retinal disinsertion occurred in males, and a sex-linked inheritance has been postulated for this condition, but Leffertstra found the incidence to be 59 per cent. in males and 41 per cent. in females in non-traumatic cases, although 80 per cent. of the traumatic cases were in males. He found retinal cysts in 10 per cent. of cases seen within 3 months of the onset of symptoms, and in 58 per cent. of those seen after 5 years.

The difficulty of accepting the hypothesis that cysts are the precursors of disinsertions is the fact that peripheral cysts giving rise to detachments have not, to my knowledge, been described in children, and since the disinsertions are bilateral in 20 per cent. of cases, a cyst should have been seen before it ruptured in the fellow eye of some of the patients with a unilateral disinsertion. Three patients have been personally examined, who had retinal disinsertion and detachment in one eye, while in the other eye was found a very small disinsertion at the ora serrata, with no evidence of cyst formation or detachment. François and Lambrechts (1952) reported one case of a true cyst of the ora serrata which could have given rise to a retinal detachment. They reported this in support of Weve's hypothesis, but the patient was aged 54. They also cited a case quoted by Bonnet and Bussy (1935), who found a cyst in the infero-temporal quadrant of the retina, but this patient was aged 62. One of Weve's cases was reported to have bilateral retinal cysts which were treated with perforating diathermy, but the patient was 64. The most likely cause in all these cases is retinoschisis following peripheral cystoid degeneration, and this can in no way be invoked to explain retinal disinsertions in young people. Duke-Elder (1949) reported the case of a 44-year-old man with a cyst in one eye which later developed a retinal disinsertion. This may have been a primary cyst, but the patient was at the extreme end of the age group reported by Leffertstra (1948) and this is not very conclusive evidence to explain detachments in young people. It may be that a very small disinsertion was present and was not seen over the bulge of the cyst. The technique of scleral indentation and binocular indirect ophthalmoscopy (Schepens and Bahn, 1950) was not in common use, nor was examination of the ora serrata with Goldmann's 3-sided mirror, so that it is not impossible that a small disinsertion was overlooked.

It would be odd for retinoschisis in the young and the old to produce such differing clinical pictures. It seems unlikely that the cysts precede retinal disinsertions in the young, but the factors which produce peripheral cystoid degeneration in the elderly also affect the ora serrata of the young, and if this is congenitally weak, as suggested by Anderson, the pull of the vitreous may tear the retina before any choroido-retinal adhesions have developed. The retina will then become detached rather than split. Inferior disinsertions often show many demarcation lines where the retina and choroid fuse and prevent extension of the detachment, though usually only temporarily. These adhesions, followed by further detachment, will cause a differential pull on the retinal layers predisposing to splitting and secondary cyst formation. The onset of symptoms in these cases is notoriously vague, and the 10 per cent. of cases described by Leffertstra as having cysts within 3 months of the onset of the detachment could well have had the detachment longer, the cysts developing as they do in so many cases of long-standing retinal detachment.

The second group of primary cysts described by François and Lambrechts (1952) had the following characteristics: they are unilateral, tumour-like, globular in form, and situated at the posterior pole.

On puncture they give a clear yellow fluid which can reform. They may resorb completely or rupture and heal with a scar, or persist and give rise to a retinal detachment. François and Lambrechts quote extensively from Veil and Guillaumat (1938), who described different categories of retinal cysts and gave an account of a cyst occurring in a 30-year-old woman; this occurred in the infero-temporal quadrant, collapsed spontaneously, and was replaced by scarring. This cyst appeared to have vessels in the deep and superficial layers. François and Lambrechts briefly describe two other cases with cysts of the retina which healed after treatment with mercury. They also cite a case described by Bollack (1938) of a cyst in the infero-temporal quadrant in a 34-year-old woman, which did not change during 14 months' observation. François and Lambrechts add a further case of a

28-year-old man, who developed a cyst above the macula following a corneal injury. The optic disc had a colobomatous area and there were scars of choroido-retinitis near the disc. Haemorrhage developed later. It seems doubtful that this cyst should be termed primary when the eye was the site of other pathological lesions. These authors cite eighteen further cases of primary cysts reported in the literature, but on reading the original reports of eleven of them, not one was found to be primary, even by François and Lambrechts's own definition.

In the cases of Thompson (1890), de Schweinitz and Shumway (1901), Neame (1920), Parsons (1920), Cridland (1920), and Coulter (1920), the cysts were associated with retinal detachment; that of Deutschmann (1914) had no cyst on enucleation; that of Treacher Collins (1893) had a lymphatic naevus; Butler (1922) described a peripheral cyst with no other details; McCulloch (1930) described a cyst associated with a colobomatous disc, which was probably a hyaloid remnant; and Ridley (1935) was probably describing retinoschisis caused by peripheral degeneration.

It is suggested that the cases described by Veil and Guillaumat, Bollack, and François and Lambrechts really had an unknown aetiology and are most unlikely to have been primary cysts as previously defined.

In the pathological files of the Institute of Ophthalmology, London, no cases have been found which could be described as primary cysts as defined by François and Lambrechts (1952).

Mann (1957d) described an association between retinal cysts and cystic changes in the lung and kidney.

## (2) ACQUIRED

The majority of these are formed by the processes of cystoid degeneration and retinoschisis. Many different factors have been implicated in the causation of these changes, the commonest being age, in which cystoid degeneration occurs very frequently and which may in a small percentage of cases lead to retinoschisis. There does not seem to be any essential difference between the processes, whether they are initiated by degeneration due to age, by trauma, or by vascular impairment. A full account will be given of peripheral cystoid degeneration and retinoschisis due to age, and of the results of a survey of sections of eyes with detached retinae.

*Peripheral Cystoid Degeneration* (Fig. 7, opposite).—This is characterized by the formation of small cavities in the retina, usually starting near the ora serrata in the infero-temporal quadrant. It often affects the outer plexiform layer at first and then spreads to involve all the layers of the retina, but it may start in the ganglion cell layer. It is commoner in older people, but has been reported in babies. In some affected eyes the degeneration may be found to affect the whole circumference, extending backwards to the equator, though rarely for more than 7 mm. It often extends into the retina medially, and into the "teeth" of the ora serrata. Macroscopically it appears as a speckled area, and in flat sections of the retina the cysts can be shown to form interlacing tunnels rather than isolated cavities. Histologically (Fig. 8, opposite), sections show cavities of varying size in the region of the external plexiform layer.

The retina is thickened where the cystic change is present. There is poorly-staining fluid in the cysts, which Zimmerman and Spencer (1960) have shown to be a mucoid

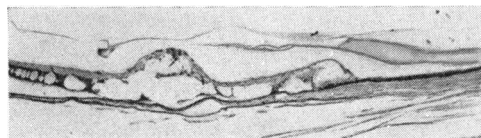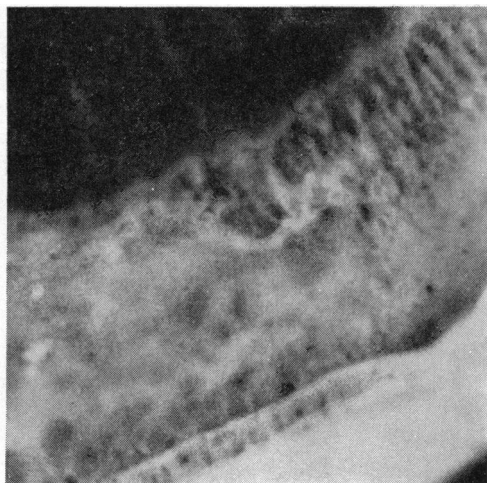


FIG. 8.—Section of Fig. 7, showing fusion of cysts, atrophy of the outer layers of the retina and choroid, and cysts of the ciliary epithelium. Haematoxylin and eosin.  $\times 45$ .

FIG. 7.—Macroscopic view of peripheral cystoid degeneration.  $\times 6$ .

substance sensitive to hyaluronidase. The walls between the cysts are composed of Müller's fibres and nuclei from the inner nuclear layer (Fig. 9). In some parts (Fig. 8) the walls appear very attenuated, and in others to have broken down, leaving remnants attached to the inner and outer layers of the retina. In some areas the retina appears more definitely split into two layers, and here retinoschisis is said to be present. The blood vessels in the area are often hyalinized and thickened. The vitreous can be seen to be firmly adherent to the inner layer of the retina by its attachment to the internal limiting membrane.

The choroid underlying the retinal degeneration appears sometimes to have fewer blood vessels than normal, and in some parts the choriocapillaris is absent. The choroid may be adherent to the outer retinal layers, and at these sites it may be difficult to detect Bruch's membrane.

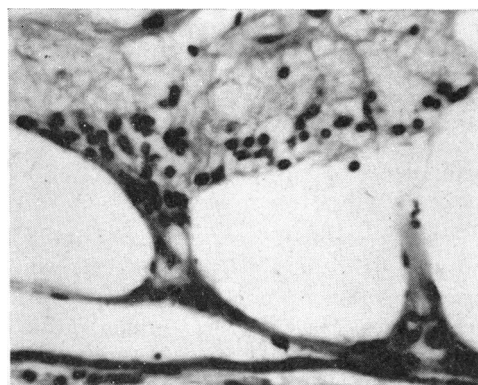


FIG. 9.—Enlargement of Fig. 8, showing attenuated septa between cavities. Haematoxylin and eosin.  $\times 280$ .

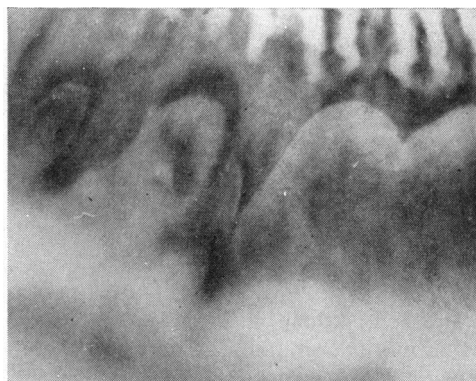

FIG. 10.—Cysts of ciliary epithelium.  $\times 6$ .

Focal atrophy of the retina and choroid (paving-stone degeneration) and cysts of the ciliary epithelium (Fig. 10) are often found in association with degeneration. The cysts of the ciliary epithelium occur between the pigmented and the non-pigmented layers of the pars plana. In some sections it is not easy to tell where the retinal cysts end and the ciliary cysts begin.

*Retinal Cysts due to Retinoschisis developing from Peripheral Cystoid Degeneration* (often termed "Senile Retinoschisis").—Macroscopically senile retinoschisis may appear as a cyst or as an area of exaggerated peripheral cystoid degeneration (Fig. 11) with a definite thickened posterior border. Microscopically, the retina is seen to be split into two layers (Fig. 3), the inner layer usually being thinner in spite of the fact that the peripheral cystoid degeneration, its precursor, starts in the outer plexiform layer. The inner walls of the cysts may be lined by the smooth glial cells, but in places the remnants of the septa are seen adhering to the lining walls of the cyst.

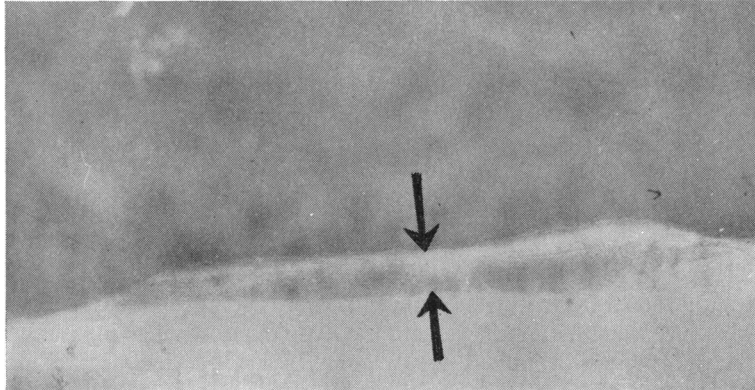


FIG. 11.—Anterior part of a flat retinal cyst which has been bisected to show the retina split into two layers.  $\times 10$ .

Blood vessels can be seen in the inner walls. The internal limiting membrane and the vitreous are condensed and adherent to the retina. In Figs 12 and 13 (opposite) a hole can be seen in the outer layer of the split retina. The margins of the hole are smooth, thickened, and gliosed, which would indicate that the hole has been present for some time. No retinal detachment is present. Changes in the choroid are as described for peripheral cystoid degeneration.

*Pathogenesis.*—The following factors have been suggested as causes of peripheral cystoid degeneration, disinsertions of the retina, and retinoschisis (Anderson, 1932):

- (a) Poor blood supply in the temporal periphery of the retina.
- (b) Pull of the zonular fibres and vitreous on the ora serrata and retina.
- (c) Lack of the nerve fibre layer to support the retina.
- (d) Congenital weakness of that part of the retina.

The capillary net at the retinal periphery is less dense than the central part. Wybar (1954) thought that the choroidal circulation was normally sufficient to maintain the whole thickness of the peripheral retina, but many of the cases with peripheral cystoid degeneration show extensive loss of the underlying choroidal capillaries (Fig. 8). The vascularization of the temporal periphery is often incomplete at birth, and this may be a factor in retinal disinsertion in the younger age group. The macula is the only other part of the retina which receives its blood supply mainly from the choroid, and it too develops cystic degenerative changes without any obvious cause.

The vitreous is very densely adherent to the zonule and peripheral retina and transmits the pull of the ciliary muscle during accommodation to the retina tending to pull it forwards, and this is probably the most important factor in the development of peripheral cystic degeneration, but for retinoschisis to occur there must usually be adhesion between the outer layers of the retina and the choroid. Although these adhesions are very common, the causes are not definitely known, but they may be produced by ischaemia or peripheral



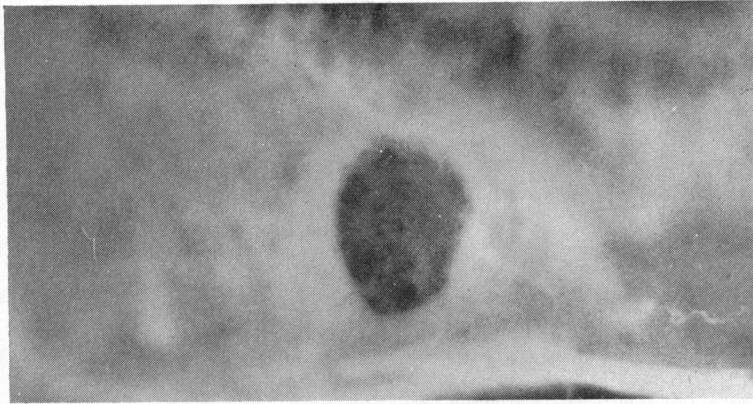


FIG. 12.—Macroscopic view of a hole in the outer layer of a split retina.  $\times 10$ .

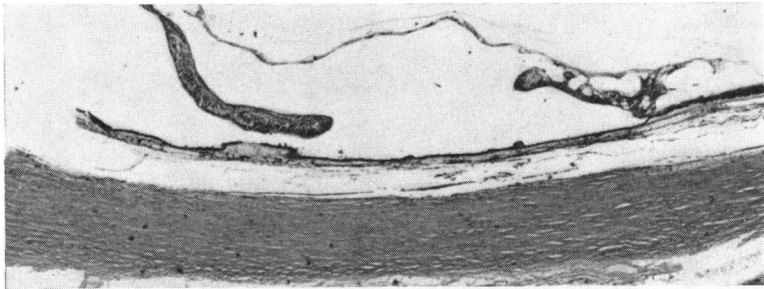


FIG. 13.—Section of Fig. 12, showing smooth margins of hole. Haematoxylin and eosin.  $\times 25$ .

uveitis (Brockhurst, Schepens, and Okamura, 1960) or by the pull of the vitreous. Once chorio-retinal adhesions are present the pull of the vitreous on the retina will tend to split it rather than detach it from the pigment cell layer. In this respect, retinoschisis may be said to preclude retinal detachment. The absence of the nerve fibre layer in the peripheral retina may cause it to be weaker than elsewhere and it has also been suggested that the retina is congenitally weak here. The appearance and disappearance of Lange's fold in children may be invoked for this hypothesis.

*Cystoid Degeneration and Cyst formation following Retinal Detachment.*—This is very common and its occurrence has often been stressed in the past. A survey has been made of sections of eyes diagnosed as primary retinal detachments at the Institute of Ophthalmology, London, in the years 1958–1963. Of the 160 eyes listed, 133 were examined and fourteen of these proved to be secondary retinal detachments. In addition eleven sections which had been diagnosed as cases of retinoschisis (*sic*) were examined. Of these, two were caused by diabetic retinopathy, two were due to central retinal vein occlusion, and one was a congenital malformation.

Of the 133 eyes with retinal detachment and the six with retinoschisis, forty had cystic change of some description. Of these, thirty had cystoid degeneration, ten showed retinoschisis, eight had pseudocyst formation, and one had spaces in the vitreous lined by retinal glial cells (Fig. 14, overleaf). In many of the sections the retina was extremely degenerate, and in others it was absent. It must be remembered that the eyes were usually enucleated only if they were painful or if they were thought to harbour malignant melanomata, so they

may not be considered as typical retinal detachments. Most of the detachments were of long standing, and bone formation in the choroid was a feature of many of the eyes.

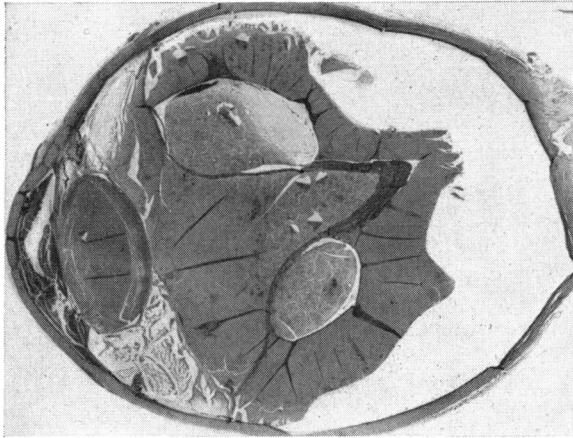


FIG. 14.—Cystic spaces lined by glial cells in a highly degenerate eye. Haematoxylin and eosin.  $\times 2.5$  (approx.).

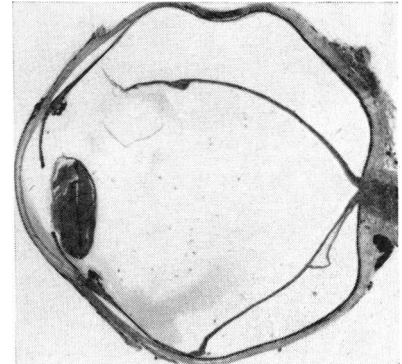


FIG. 15.—Splitting of retina near optic disc in a long-standing retinal detachment. Haematoxylin and eosin.  $\times 2$  (approx.).

Cystoid degeneration in the detached retina was the commonest type of cystic change. It appeared in some cases to be due to a contraction of the internal limiting membrane and the inner layers of the retina, drawing the outer layer into folds and causing cystic changes to appear. In other sections the cystic change may have been related to the anoxia of the retina which caused degeneration and liquefaction of cells. In some cases it appeared to be due to traction on the retina by fibrous bands or membranes in the vitreous, which caused cystic change in a way similar to that found in undetached retinae. Retinoschisis or splitting of the retina may occur at any obvious site of traction caused by a vitreous membrane, but it quite frequently occurs near the optic disc (Fig. 15).

*Cystoid Change following Choroiditis.*—A choroidal focus of infection which spreads to involve the outer layers of the retina only will predispose the retina to splitting or cyst formation by fixing the outer retinal layers and so causing tearing forces between these and the inner layers on movement of the eye (Fig. 16, opposite). The mechanism is like that discussed previously for senile retinoschisis.

*Vascular Causes of Cystoid Change.*—Poor choroidal blood supply probably plays a part in the development of peripheral cystoid degeneration, as already discussed. Cystoid changes and retinoschisis have been seen in central retinal vein occlusion, (Fig. 17, opposite), central retinal artery occlusion, and diabetic retinopathy. These changes may be caused by anoxia, oedema, or haemorrhage in all groups, while traction plays a part in the late stages of diabetic retinopathy.

*Trauma.*—This may involve any of the factors already mentioned, such as choroido-retinal adhesions and haemorrhages. Macular oedema and cystic change are especially liable to occur in concussion injuries to the eye, probably as a sequel to oedema at the posterior pole.

*Parasitic Cysts.*—Cysts are not uncommon in parasitic disease of the eye, and particularly in hydatid disease. These conditions are very rare in Great Britain, however, and the author has had no opportunity to study them.

*Phakomatoses.*—These diseases are relatively rare, but cyst formation has occasionally been described in the retina. Van der Hoeve (1932) described a cyst occurring at the optic

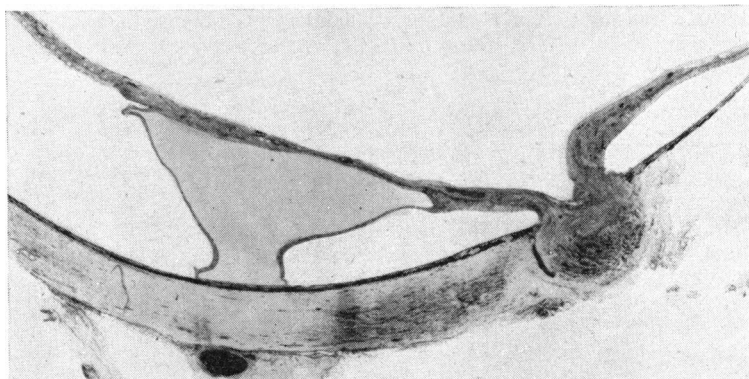


FIG. 16.—Splitting of retina at site of choroido-retinal adhesion. Haematoxylin and eosin.  $\times 7$ .

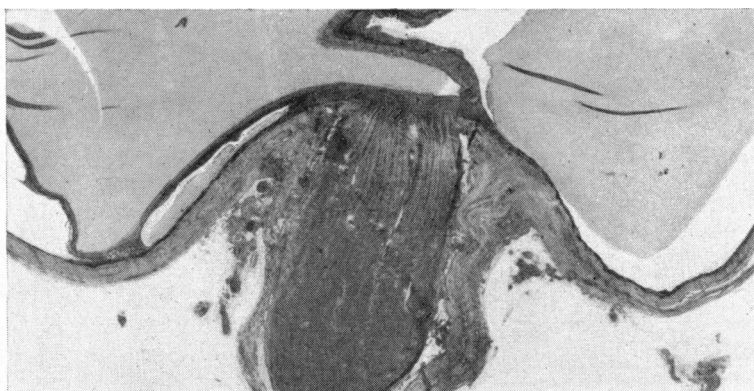


FIG. 17.—Splitting of retina caused by a haemorrhage following central retinal vein occlusion. Haematoxylin and eosin.  $\times 8$ .

disc in Bourneville's disease; this occasionally emptied itself and then filled up again. Cysts have also been described in the von Hippel-Lindau syndrome and in von Recklinghausen's disease (multiple neuro-fibromatosis). These may have a congenital basis and so may be described as true cysts.

*Coats's Disease.*—Coats (1908) described cyst formation in the retina in many of his patients who had this condition. The aetiology of the affection is still unknown, although in some cases it appears to be due to an angioblastoma (von Hippel-Lindau tumour), in others to Leber's multiple miliary aneurysms, and in others allergy has been suggested.

*Unknown.*—There still remain some cysts of the retina which have no recognizable or suggested cause, and which are not associated with any other disease.

### Summary

The literature on retinal cysts and retinoschisis is reviewed. 144 sections of eyes were examined and on this basis a new classification of retinal cysts is proposed. The rarity of primary cysts is stressed and doubt is expressed as to the causation of retinal disinsertions by pre-existing retinal cysts.

I wish to express my gratitude to Prof. N. Ashton for his advice and allowing me access to specimens in his Department. Mr. G. Knight, Mr. V. Elwood, Mrs. A. Ferguson and Mr. Jeffries rendered invaluable technical assistance.

## REFERENCES

- ANDERSON, J. RINGLAND (1932). *Brit. J. Ophthalm.*, **16**, 641.  
 BALIAN, J. V., and FALLS, H. F. (1960). *Arch. Ophthalm. (Chicago)*, **63**, 92.  
 BOLLACK, J. (1938). *Arch. Ophtal. (Paris)*, n. s. **2**, 983.  
 BONNET, P., and BUSSY, J. (1935). *Bull. Soc. Ophtal. Paris*, p. 341.  
 BROCKHURST, R. J., SCHEPENS, C. L., and OKAMURA, I. D. (1960). *Amer. J. Ophthalm.*, **49**, 1257.  
 BUTLER, T. H. (1922). *Trans. ophthalm. Soc. U.K.*, **42**, 304.  
 COATS, G. (1908). *Roy. Lond. ophthalm. Hosp. Rep.*, **17**, 440.  
 COLLINS, E. TREACHER (1893). *Ibid.*, **13**, 41.  
 COULTER, R. J. (1920). *Trans. ophthalm. Soc. U.K.*, **40**, 172.  
 CRIDLAND, B. (1920). *Ibid.*, **40**, 172.  
 DEUTSCHMANN, F. (1914). *Beitr. Augenheilk.*, **9**, 591.  
 DUKE-ELDER, S. (1938). "Text-book of Ophthalmology", vol. 2, p. 1338. Kimpton, London.  
 ——— (1940). *Ibid.*, vol. 3, p. 2806.  
 ——— (1949). *Brit. J. Ophthalm.*, **33**, 388.  
 ——— (1964a). "System of Ophthalmology", vol. 3, pt. 2, p. 451. Kimpton, London.  
 ——— (1964b). *Ibid.*, p. 642.  
 FRANÇOIS, J., and LAMBRECHTS, J. (1952). *Ann. Oculist. (Paris)*, **185**, 348.  
 FUCHS, A. (1921). v. *Graefes Arch. Ophthalm.*, **105**, 333.  
 GOODSIDE, V. (1960). *Arch. Ophthalm. (Chicago)*, **63**, 682.  
 HEINE, L. (1904). v. *Graefes Arch. Ophthalm.*, **58**, 38.  
 HRUBY, K. (1956). *Ibid.*, **158**, 87.  
 IWANOFF (1864). *Klin. Mbl. Augenheilk.*, **2**, 415 (Cited by Nettleship, 1872).  
 JAGER, G. M. (1953). *Trans. ophthalm. Soc. U.K.*, **73**, 617.  
 JULER, F. A. (1947). *Ibid.*, **67**, 83.  
 LEFFERTSTRA, L. J. (1948). "Over Orascheuren", pp. 91–133. Kemink en Zoon, Utrecht.  
 ——— (1950). *Ophthalmologica (Basel)*, **119**, 1.  
 MCCULLOCH, J. D. (1930). *Trans. ophthalm. Soc. U.K.*, **50**, 619.  
 MANN, I. (1957a). "Developmental Abnormalities of the Eye", 2nd ed., p. 66. B.M.A., London.  
 ——— (1957b). *Ibid.*, p. 223.  
 ——— (1957c). *Ibid.*, p. 127.  
 ——— (1957d). *Ibid.*, p. 190.  
 NEAME, M. (1920). *Trans. ophthalm. Soc. U.K.*, **40**, 161.  
 NETTLESHIP, E. (1872). *Ophthalm. Hosp. Rep.*, **7**, 343.  
 PARSONS, J. H. (1920). *Trans. ophthalm. Soc., U.K.*, **40**, 171.  
 RIDLEY, H. (1935). *Brit. J. Ophthalm.*, **19**, 101.  
 SCHEPENS, C. L., and BAHN, G. C. (1950). *Arch. Ophthalm. (Chicago)*, **44**, 677.  
 DE SCHWEINITZ, G. E., and SHUMWAY, E. A. (1901). *Amer. J. med. Sci.*, **122**, 736. (Cited by Neame, 1920).  
 SORSBY, A., KLEIN, M., GANN, J. H., and SIGGINS, G. (1951). *Brit. J. Ophthalm.*, **35**, 1.  
 ——— (1955). "Modern Trends in Ophthalmology", 3rd Series, p. 197. Butterworth, London.  
 THOMPSON, J. T. (1890). *Trans. ophthalm. Soc. U.K.*, **10**, 151.  
 VAN DER HOEVE, J. (1932). *Ibid.*, **52**, 380.  
 VEIL, P., and GUILLAUMAT, L. (1938). *Arch. Ophtal. (Paris)*, n.s. **2**, 977.  
 VOGT, A. (1936). *Klin. Mbl. Augenheilk.*, **96**, 10.  
 WEVE, H. J. M. (1936). *Arch. Augenheilk.*, **109**, 49.  
 WYBAR, K. C. (1954). *Brit. J. Ophthalm.*, **38**, 513.  
 ZIMMERMAN, L. E., and SPENCER, W. H. (1960). *Arch. Ophthalm. (Chicago)*, **63**, 10.