

## COMMUNICATIONS

### XEROPHTHALMIA AND PROTEIN MALNUTRITION IN BANTU CHILDREN\*†

BY

B. S. KUMING AND W. M. POLITZER

*From the Department of Ophthalmology, Baragwanath Hospital and University of the Witwatersrand, and the Department of Biochemistry, South African Institute for Medical Research, Johannesburg*

XEROPHTHALMIA and malnutrition are worldwide problems, and their relationships to each other are of special interest. It is the purpose of this paper to show that:

(1) Xerophthalmia occurs not uncommonly in the Republic of South Africa.

Previous reports of xerophthalmia in the Republic of South Africa are few. Kark (1943) and Klenerman (1950) stated that xerophthalmia infrequently accompanies protein malnutrition, and eye symptoms, when present, seemed to be due to vitamin B deficiency. Oomen, McLaren, and Escapini (1964a) did not mention the Republic of South Africa in their recent survey of xerophthalmia.

(2) Xerophthalmia is closely related to protein malnutrition.

McLaren (1963d) stated that the lone occurrence of either disease is the rule, and that they occur in association only where both are at their worst; Oomen, McLaren, and Escapini (1964b) stated that protein malnutrition always accompanies the more severe manifestations of vitamin A deficiency. Oomen (1961a) argued that xerophthalmia is a precursor of protein malnutrition, and considered that the eye signs are primarily related to hypovitaminosis A, although he did state that "there are strong reasons to regard every degree of xerophthalmia as a case of general malnutrition". In any event, it is acknowledged that malnutrition may often be associated with xerophthalmia.

(3) The syndrome of discrete colliquative keratopathy, as described by Blumenthal (1950), always occurs in association with protein malnutrition. It constitutes a variant of the general syndrome of xerophthalmia.

(4) Local infection may play a more important role in the pathogenesis of the lesions of xerophthalmia than previously emphasized.

#### Material and Methods

**Patients.**—During the 12 months May, 1962, to April, 1963, a total of 1,116 cases of malnutrition was admitted to the paediatric wards of the Baragwanath Hospital, Johannesburg. These constituted only the more severe forms of the disease, less serious cases being treated as out-patients. Each of these children was subjected to a careful ocular examination. All corneae were stained with fluorescein to detect the earliest signs of epithelial erosion; where possible, slit-lamp examination was also performed. The fundus was not routinely examined. In 108 patients 184 eyes were found to have ocular lesions due to

\* Received for publication June 28, 1966.

† Address for reprints: Department of Ophthalmology, University Medical School, Hospital Hill, Johannesburg, Republic of South Africa.

malnutrition, and these form the subject of this study. In three children who died, *post mortem* examination of the corneae was performed.

### Investigations

(a) Serum vitamin A and carotene estimations were performed on 25 of the 108 patients. The method was that described by Kimble (1939).

(b) Conjunctival swabs were also taken from 20 patients. Because of technical difficulties and the urgency of instituting treatment, not every child could be swabbed. These swabs were plated by routine techniques.

(c) Control serological and bacteriological studies were also performed on thirty patients with kwashiorkor alone, and thirty normal subjects.

### Results

(1) **General.**—There were 1,116 admissions of patients with protein malnutrition who showed a malnourished state associated with a low serum protein (Table I).

TABLE I  
ANALYSIS OF CASES ADMITTED TO HOSPITAL WITH KWASHIORKOR

Associated Conditions	No. of Cases	Per cent. of Total No. of Cases	Deaths
	1,116	100	277 (24.8 per cent. of total)
Diarrhoea	461	41.3	168 (36.5 per cent. of cases with diarrhoea)
Xerophthalmia	108	9.7	32 (29.6 per cent. of cases with xerophthalmia)

(2) **Associated Lesions.**—Pneumonia, gastroenteritis, anaemia, and hypothermia were often associated with malnutrition. It was considered that the nutritional deficiency was the primary factor in the disease process.

Children with measles, exposure keratitis due to coma, obvious conjunctivitis, and with phlyctenular kerato-conjunctivitis were excluded.

### (3) Eye Findings (*Xerophthalmia*)

(a) *Distribution.*—There were 108 cases of xerophthalmia, an incidence of 9.7 per cent. Of these 108 cases, 76 were bilateral and 32 unilateral, *i.e.* 184 eyes were found to have eye lesions due to malnutrition.

(b) *Sex.*—There were 43 females and 65 males (ratio of 2 : 3).

(c) *Age.*—The mean age was 1.4 years (range 1 month to 7 years) (Table II).

TABLE II  
AGE INCIDENCE

Age Group (yrs)	0-1	1-2	2-3	3-4	Over 4	Total
No. of Cases	37 (30 > 6/12, 7 < 6/12)	52	11	4	4	108

(d) *Eye Lesions.*—These were divided into seven morphological groups, based on their clinical appearance. As the lesions were fairly distinctive, it was considered

justifiable to use these groupings, although a certain amount of overlap did occur (Table III).

TABLE III  
DISTRIBUTION OF CLINICAL GROUPS

Clinical Group	Eyes		Clinical Distribution of Patients (based on the more severe eye lesion)	
	No.	Per cent.	No.	Per cent.
(i) Xerosis conjunctivae	6	3.3	3*	2.8
(ii) Xerosis corneae without ulceration	13	7.1	5	4.6
(iii) With ulceration				
(a) Mild	79	42.9	41	38
(b) Moderate	43	23.4	28	25.9
(c) Severe	21	11.4	15	13.9
(iv) Keratomalacia (localized or generalized)	15	8.1	11	10.2
(v) Healed xerophthalmia	13	7.1	8	7.4
Total	184	100	108	100

\* These three cases were associated with xerosis corneae, and therefore not included in the totals.

(i) *Xerosis Conjunctivae*.—Three cases had both eyes showing the typical features of xerosis conjunctivae. The conjunctiva was wrinkled, pigmented, and thickened. One case was associated with xerosis corneae with mild ulceration, one with xerosis corneae with moderate ulceration, and one with xerosis corneae with severe ulceration.

In all these patients, the conjunctiva recovered completely.

(ii) *Xerosis Corneae without Ulceration*.—Haziness of the cornea was the predominant feature of this group. An ulcer always appeared hazy, but the haziness was localized to the ulcerated area. In this group, the whole cornea had a rough, dry, hazy appearance.

(iia) *Xerosis Corneae with Mild Ulceration*.—Linear, small circular or oval erosions in the lower half of the cornea, either multiple or single. Sometimes a linear abrasion was seen to consist of a number of small discrete punctate erosions. The distance from the limbus varied from 1 to 4 mm., but was usually 2 mm. from the limbus. Clinically, this was a superficial lesion. No vascularization was seen.

(iib) *Xerosis Corneae with Moderate Ulceration*.—A larger ulcer with well-marked staining with fluorescein. This involved an area 3 to 4 mm. across and appeared to involve the deeper layers of the epithelium. Bowman's membrane might be involved. No vascularization was seen (Fig. 1).

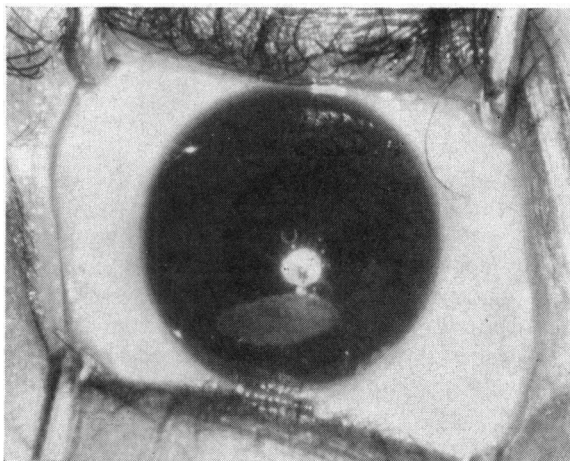


FIG. 1.—Xerosis corneae with moderate ulceration. Ulcer stained with fluorescein.

(iic) *Xerosis Corneae with Severe Ulceration*.—A severely ulcerated area occupied the whole horizontal diameter of the cornea in its lower half, and could extend to involve the whole cornea. There was no corneal softening. The ulcer was deep and sometimes involved Bowman's membrane and occasionally the stroma. It was considered to be associated with severe exfoliation of the epithelium; associated infection was probable (Figs 2 and 3).

FIG. 2.—Xerosis corneae with severe ulceration. Ulcer stained with fluorescein involves lower half of cornea.

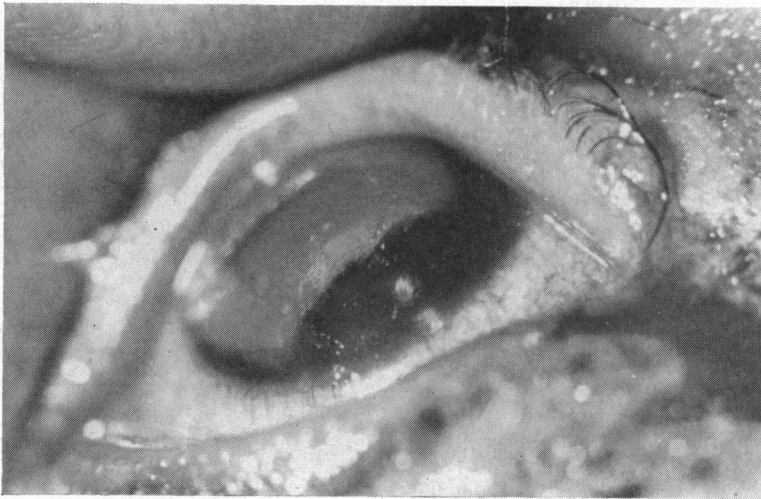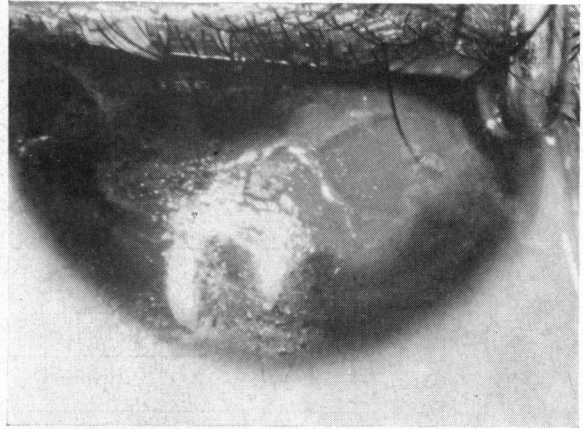


FIG. 3.—Xerosis corneae with severe ulceration. Ulcer stained with fluorescein occupies almost the whole of the corneal surface.

(iv) *Keratomalacia*.—The definition of McLaren (1963h) has been used in which keratomalacia is defined as a colliquative necrosis of the cornea. This may be of two types, local or general. Local keratomalacia presents as a localized area of softening (Fig. 4, opposite) and results in an iris prolapse, or descemetocoele.

General keratomalacia represents the classical picture of keratomalacia (Figs 5 and 6, opposite). Two hypopyon ulcers occurred in this group. Xerosis corneae and keratomalacia are, in our opinion, manifestations of the same disease process, differing only in their severity.

(v) *Healed Lesion*.—There was no activity in the cornea or conjunctiva, but evidence of a previous lesion in the form of a nebula or a leucoma was present. Those children were assumed to have had previous episodes of malnutrition and xerophthalmia.

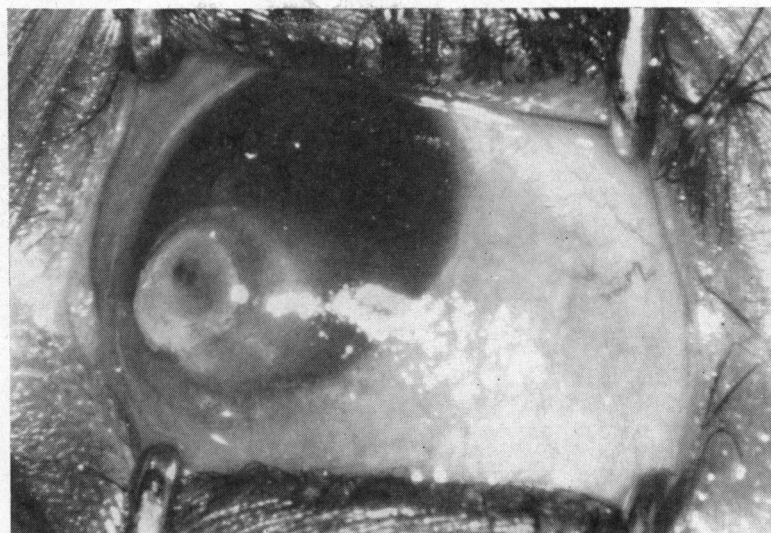

FIG. 4.—Localized keratomalacia. A small knuckle of iris is seen presenting in the middle of an area of keratomalacia localized to the infero-nasal quadrant.

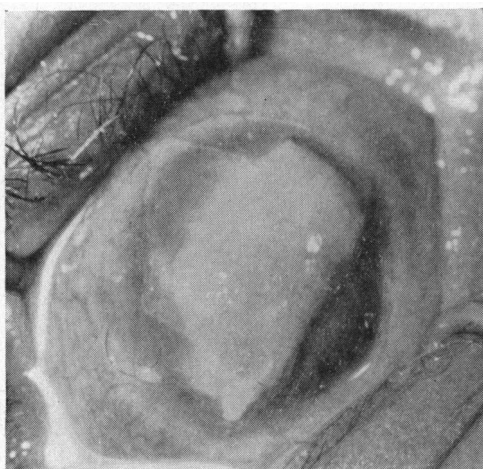

FIG. 5.—Generalized keratomalacia. The whole cornea is necrotic and opaque. A large iris prolapse is present inferiorly.

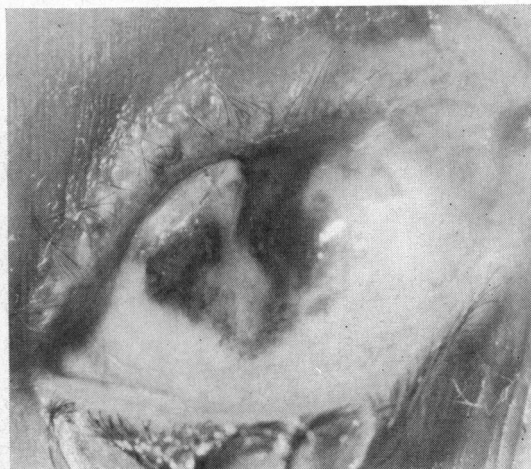


FIG. 6.—Generalized keratomalacia (fellow eye of case shown in Fig. 5). The cornea has sloughed away in parts, exposing the iris and lens.

(e) *Treatment of the Eye Conditions.*—In all cases, the general nutritional state was treated. All eyes of groups (iii) and (iv) received antibiotic and atropine ointment topically. 50,000 units vitamin A by intramuscular injection were given for 3 days to all cases, supplemented by a daily oral vitamin A dose of 2,500 I.U., except in the group with xerosis corneae with mild ulceration, where intramuscular vitamin A was withheld in half the cases.

Those children not receiving intramuscular injections of vitamin A were closely watched for possible deterioration. It was found that in this group the administration of intramuscular vitamin A did not affect the eventual outcome of the lesion. It was not considered ethically justifiable to withhold vitamin A for the purpose of comparison in the more severe cases.

(f) *Prognosis*(i) *Recovery related to severity of the ocular lesion (Table IV).*

TABLE IV  
RECOVERY RELATED TO SEVERITY OF OCULAR LESION

Group		No. of Eyes	Full Clinical Recovery*		Nebulae		Destruction	
			No.	Per cent.	No.	Per cent.	No.	Per cent.
Xerosis Corneae	Without Ulceration	13	10	76.9	1	7.7		
	With Mild Ulceration	79	47	59.5	19	24.1		
	With Moderate Ulceration	43	17	39.5	10	23.3		
	With Severe Ulceration	21	4	19	1	4.8		
Keratomalacia		15			3	20†	7	46.7‡
Healed Xerophthalmia		13						
Total		184						

\*—At time of discharge.

†—Adherent leucomata resulted.

‡—In these eyes, a useless, severely scarred cornea resulted, progressing to staphyloma formation (Fig. 7, opposite) or phthisis bulbi (Fig. 8, opposite). In two cases followed for over a year, a "nipple-teat" staphyloma resulted.

The difference between the total number of eyes and the total of the sub-groups Recovery, Nebulae, and Destruction is due to the death of a child whose eye was in a particular group.

(ii) *Death related to severity of the more severe ocular lesion (Table V).*

TABLE V  
MORTALITY RELATED TO SEVERITY OF MORE SEVERE OCULAR LESION

Group	Xerosis Corneae				Kerato- malacia	Healed Xerophthalmia	Total
	Without Ulceration	With Mild Ulceration	With Moderate Ulceration	With Severe Ulceration			
No. of Patients in Group	5	41	28	15	11	8	108
No. of Patients who Died	1	6	9	12	3	1	32

The prognosis for life is seen to be proportional to the severity of the eye lesion. The unexpected smaller percentage of the group with keratomalacia will be discussed later.

FIG. 7.—Staphyloma formation.

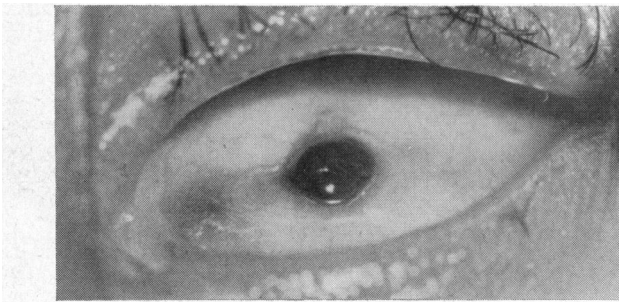
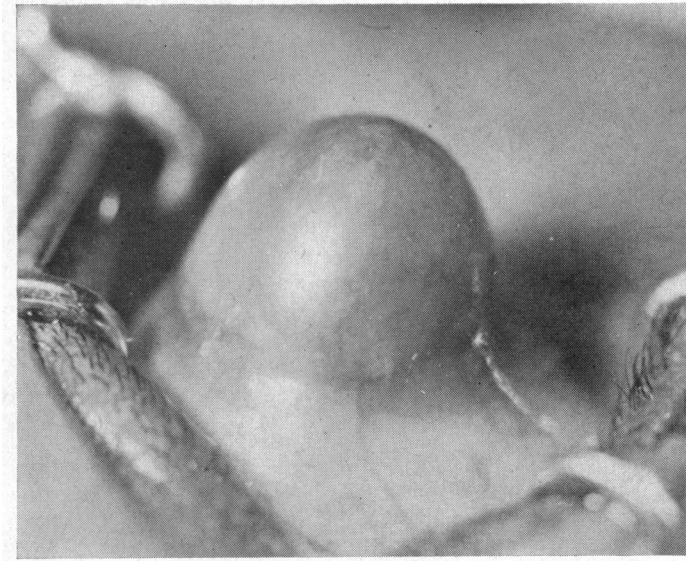
FIG. 8.—Phthisis bulbi. End-result in eye shown in Fig. 6.

#### (4) Bacteriological Survey

(a) *Kwashiorkor with Eye Lesions.*—Swabs for culture were taken from twenty patients. There were two cases of xerosis corneae without ulceration, twelve of xerosis corneae with mild ulceration, three of xerosis corneae with moderate ulceration, two of xerosis corneae with severe ulceration, and one of keratomalacia. Organisms were isolated in fifteen cases. Five cases showed no growth. One of these was from a case with xerosis corneae without ulceration and four from cases with mild ulceration. The organisms isolated showed a wide range, including *Pneumococcus*, *Staph. pyogenes*, *Staph. albus*, *Staph. aureus*, *B. proteus*, Koch-Weeks bacillus, haemolytic streptococci, and *Strept. pyogenes*.

(b) *Kwashiorkor without Eye Lesions.*—Twenty cases were swabbed. Four showed no growth, and the remainder presented a bacteriological spectrum identical to group (a).

(c) *Matched Control Series of Thirty Normal Bantu Children and Infants.*—Nine cases showed no growth, and the remainder showed a wide variety of organisms, including two cases with *Staph. pyogenes*.

**(5) Serological Studies****(a) Protein Malnutrition with Eye Lesions (25 cases)**

- (i) *Vitamin A Levels:* Range 7.4 to 145.4 I.U.  
Average 43 I.U.  $\pm$  33.0.  
Modal frequency 21 to 30 I.U.
- Xerosis corneae with mild ulceration: Average 52 I.U. (13 cases).  
Xerosis corneae with moderate ulceration: Average 40 I.U. (5 cases).  
Xerosis corneae with severe ulceration  
and keratomalacia: Average 15 I.U. (7 cases).
- (ii) *Carotene Levels:* Range 3.1 to 24.6  $\mu$ g.  
Average 12  $\mu$ g.  $\pm$  6.9.  
Modal frequency 10.1 to 15  $\mu$ g.
- Xerosis corneae with mild ulceration: Average 12  $\mu$ g.  
Xerosis corneae with moderate ulceration: Average 5  $\mu$ g.  
Xerosis corneae with severe ulceration  
and keratomalacia: Average 15  $\mu$ g.

**(b) Protein Malnutrition without Eye Lesions (30 cases)**

- (i) *Vitamin A Levels:* Range 6.1 to 160 I.U.  
Average 51.3 I.U.  $\pm$  28.5.  
Modal frequency 40 to 50 I.U.
- (ii) *Carotene Levels:* Range 3.2 to 56  $\mu$ g.  
Average 16  $\mu$ g.  $\pm$  11.1.  
Modal frequency 11 to 15  $\mu$ g.

**(c) Normal Bantu Children without Protein Malnutrition or Eye Lesions (30 cases)**

- (i) *Vitamin A Levels:* Range 5 to 278 I.U.  
Average 53.3 I.U.  $\pm$  51.
- (ii) *Carotene Levels:* Range 12 to 120  $\mu$ g.  
Average 34  $\mu$ g.  $\pm$  27.1.

There was no statistical significance between the various vitamin A levels. However, the vitamin A levels for the more serious manifestations of xerosis corneae with severe ulceration and keratomalacia were significant. The differences in the carotene levels were highly significant in two groups; comparing the control group with the kwashiorkor group,  $P = <0.001$ ; comparing the control group and the group of kwashiorkor with eye lesions,  $P = <0.001$ ; comparison of the group with malnutrition and the group with malnutrition and eye lesions revealed no significant difference. The only statistically significant difference between the various vitamin A levels was found in the group of cases of protein malnutrition with eye lesions, where the group with severe eye lesions was significantly different from the group with the less severe lesions ( $P = <0.01$ ).

**(6) Histology.**—*Post mortem* examination of the corneae was performed in three cases within a few hours of death. All three had xerosis corneae with severe ulceration (Figs 9, 10, opposite, and Fig. 11, overleaf).



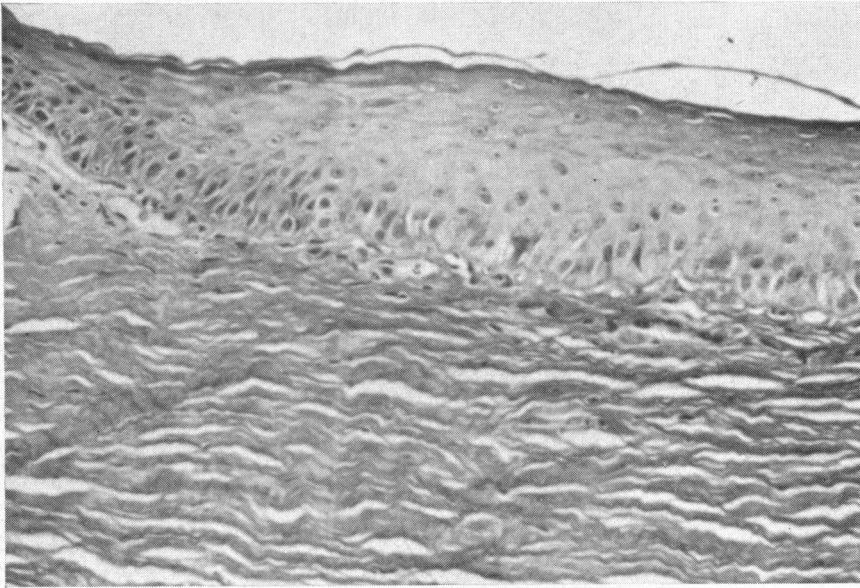


FIG. 9.—Section from the limbus, showing keratin formation and parakeratosis.  $\times 400$ .

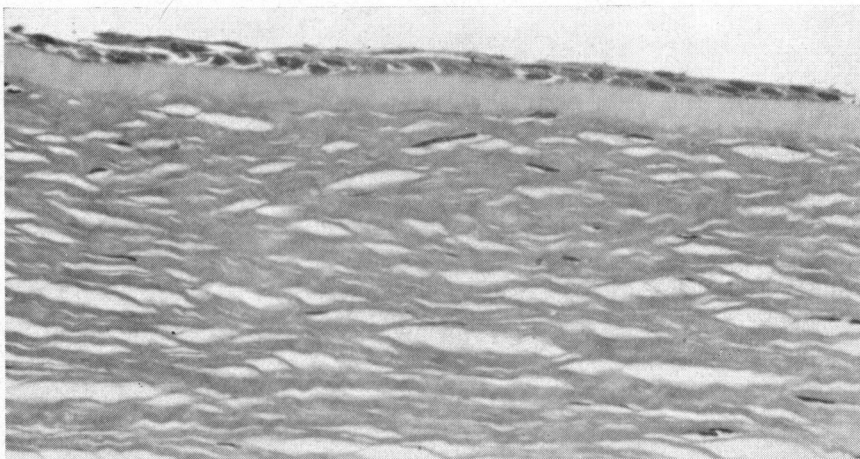


FIG. 10.—Section from same cornea as Fig. 9, showing loss of epithelium and flattening of basal cell layer. Bowman's membrane is intact.  $\times 320$ .

The epithelium was lost, but occasionally the basal layer was retained in parts. If epithelial cells did remain, these were flattened. Bowman's membrane might be interrupted. The fibres of the substantia propria were separated and pyknotic and karyolytic nuclear debris was sometimes seen in the spaces between the fibres. Among the debris could be recognized the nuclei of polymorphonuclear leucocytes. Stains for reticulum, collagen, elastin, and metachromasia revealed no specific changes in the corneal stroma. At the limbus, attempts at keratinization with parakeratosis were seen. A sub-epithelial inflammatory cell infiltration was occasionally present. Early vascularization was also observed occasionally at the limbus.

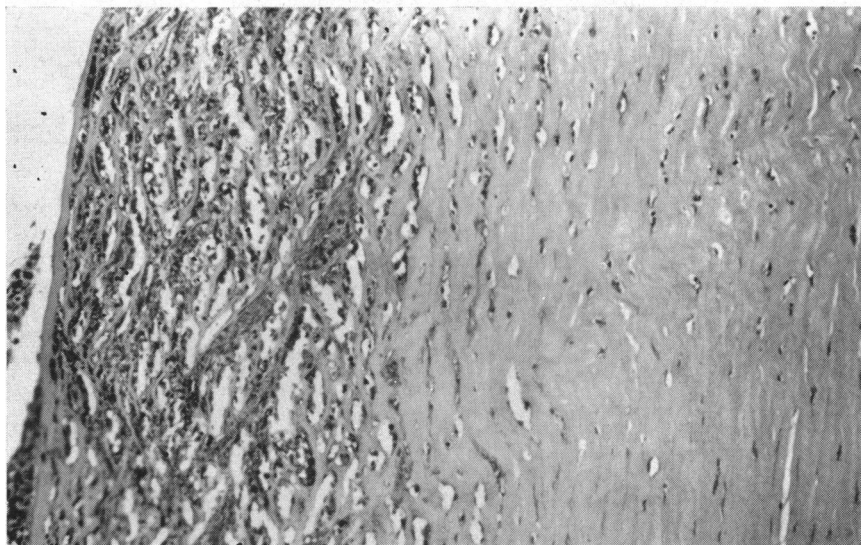


FIG. 11.—Specimen of cornea, showing loss of epithelium and thinning of Bowman's membrane on the right. The fibres of the stroma are separated and the spaces between contain karyorrhectic and karyolytic nuclear debris.  $\times 133$ .

### Discussion

These children all had one common disease, *viz.* protein malnutrition, and of the numerous cases of kwashiorkor, a considerable percentage had developed xerophthalmia. The association between protein malnutrition and eye lesions is fully accepted.

“Protein calory malnutrition is an invariable accompaniment of the more severe ocular manifestations of vitamin A deficiency” (Oomen and others, 1964b).

The temporal relationship has been considered to be

“Eye signs are first, afterwards general malnutritional signs” (Oomen, 1961a).

Our basic approach has been that protein malnutrition was the cause of xerophthalmia, and that xerophthalmia was, in this series, a sign of protein malnutrition. Although other authors have stated that xerophthalmia may occur in isolation, it is our experience that xerophthalmia in infants without protein malnutrition is extremely rare, and that the situation is similar in adults. Malnutrition without xerophthalmia on the other hand is common.

**General Incidence.**—In this study, 9·4 per cent. of children with protein malnutrition were found to have eye lesions. The incidence in other studies has varied widely. Scragg and Rubidge (1960) found an incidence of 0·9 per cent. with keratomalacia in their series of cases of kwashiorkor. Sandozai, Haquani, Rajeshvai, and Kaur (1963) found that 36 per cent. of their cases had eye signs, including Bitot's spots. Chandra, Venkatachalam, Belavadi, Reddy, and Gopalan (1960) found an incidence of 15·7 per cent.; in only 0·5 per cent. of their cases was xerophthalmia present alone.

**Sex.**—The preponderance of male children with xerophthalmia noted in other

series (McLaren, 1963f) is confirmed. Gopalan, Venkatachalam, and Bhawani (1960) found a similar incidence. Scragg and Rubidge (1960) found no sex difference in their cases of kwashiorkor, although there were 839 males and 726 females in their series. Trowell, Davies, and Dean (1954a) stated that there seemed to be a slight preponderance of boys with kwashiorkor. At Baragwanath, the sex incidence of protein malnutrition is equal. It may well be that the greater vulnerability of the male to vitamin A deficiency may account for the increased incidence of males with xerophthalmia (Moore, 1957).

**Age.**—The maximum incidence of eye lesions occurs in the second year of life. This corresponds to the maximal incidence of kwashiorkor. Although the youngest was one month and the oldest 7 years old, all showed signs of protein malnutrition. It was found that there was no relationship between the severity of the eye lesion and the age of the patient.

**Conjunctival Lesions.**—Only three patients had classical conjunctival lesions, *i.e.* xerosis conjunctivae, with a muddy-looking, wrinkled, leathery conjunctiva, which was brownish and dry in appearance. One was associated with xerosis corneae with mild ulceration, one with xerosis corneae with moderate ulceration, and one with xerosis corneae with severe ulceration. Both eyes were involved in all three cases and the lesions responded well to routine ward treatment and topical antibiotics. However, many patients exhibited what could be called a mild xerosis of the conjunctiva, with slight wrinkling, muddiness, hyperpigmentation, and loss of lustre. Oomen (1958a) noted that the conjunctiva shows slight alterations such as dryness, thinness, and wrinkling in cases of kwashiorkor. It is obvious that there may be a close relationship between these minor lesions and the more severe lesions of xerosis conjunctivae.

Pigmentation varied considerably and was often present in normal subjects and in patients with kwashiorkor only. Many patients with the eye lesions did not show pigmentation. Limbal spring catarrh is a common cause of hyperpigmentation in the non-European and this was not therefore taken to be a clinical sign of xerophthalmia.

Tear secretion was present in most cases and when absent (usually in children who were dehydrated) rapidly responded to ward diet and rehydration.

Most of the eyes appeared clinically quiet even in the presence of severe ulceration. No child had any evidence of Bitot's spots; this confirms current thought about Bitot's spots, *viz.* that they are not a sign of vitamin A deficiency *per se* (McLaren, 1963i). Bitot's spots have been observed fairly frequently in both children and adults in the out-patients department, but no other associated signs of vitamin A deficiency or protein malnutrition was found in these patients.

**Corneal Lesions.**—These were subdivided into the groups discussed above, because the lesions represented distinct morphological entities, and it was felt that such a sub-division had a bearing on prognosis; furthermore, this classification could be used in assessing the severity of the lesion. Intermediate lesions did of course occur. It is felt that the progression from xerosis conjunctivae to keratomalacia represents the pathogenesis of the lesion. The disease process may be arrested at any stage,

except keratomalacia which is irreversible. Oomen (1958b) considered keratomalacia to be different from xerosis corneae, but we have considered it to be part of the same pathological process, as does McLaren (1963h). It will be seen that the prognosis for recovery decreases as the severity of the eye lesion increases (Table IV).

**Treatment.**—It was noted that, in cases of xerosis corneae with superficial ulceration, whether intramuscular vitamin A was withheld or not, most of the lesions recovered fully. The occurrence of nebulae after discharge from hospital did not mean that these nebulae would persist, as nebulae may clear spontaneously, especially in infancy. However, the fact that nebulae did occur implies that Bowman's membrane had been breached and that stromal damage had occurred. It was considered that infection was far more dangerous than the lack of vitamin A, and thus topical antibiotics were always administered. The vitamin A returned to normal levels together with the protein level, by means of a routine ward diet. In other groups, intramuscular vitamin A was administered. Nevertheless, it will be seen that a considerable percentage developed corneal scarring. With two exceptions to be discussed shortly, the lesions, once treated, did not progress, *i.e.* once they had been assigned to a group, they remained in this group irrespective of the lesion.

Protein is necessary for the transport of vitamin A. The administration of large doses of vitamin A would not theoretically relieve any shortage of vitamin A as there would still be inadequate protein to transport it. It has been stated (Rodger, Saiduzzafar, Graver, and Fazal, 1964; McLaren, 1961) that cases of keratomalacia have been cured or arrested by the administration of vitamin A. This cannot be completely accepted because, by definition, keratomalacia implies an acute colliquative necrosis, *i.e.* cell death. Similar types of acute necrosis may be found, for example, in the liver, but here recovery occurs only by reduplication of remaining viable cells. It is impossible for keratomalacia to recover, as corneal necrosis always results in severe scarring, and it has been our experience that the corneal damage of keratomalacia is permanent, despite the most vigorous treatment.

**Prognosis of the Eye Lesions.**—The prognosis, both for full recovery of the eye and for life, worsened as the lesions progressed. Thus, the severity of the eye lesions is of prognostic value in assessing the severity of the disease. Generally, the more severe the malnutrition, the worse the eye lesion. An exception to this rule was the better prognosis for life in the group with keratomalacia, the most severe eye lesion. A possible explanation is that in these patients the protein malnutrition was not perhaps as severe as in those with severe corneal ulceration, though the vitamin A deficiency was equally severe; thus the deleterious effects of vitamin A and carotene deficiency were aggravated, *i.e.* the protein : vitamin A ratio was more disturbed. This would be the clinical equivalent of the experiments of McLaren (1959), in which the more severe lesions occurred in rats with higher protein intake. Unfortunately, protein levels were not compared in the cases of xerosis corneae with severe ulceration and keratomalacia, but it is hoped in the future to study protein and vitamin A levels in all the groups.

**Role of Infection.**—Although vitamin A may play a basic part, infection is also an important factor in the pathogenesis of eye lesions. Yudkin and Lambert (1923)

considered that the earliest lesions of vitamin A deficiency consisted of focal inflammatory lesions in the conjunctiva. McLaren (1963a) stated that, in the experimental animal, a break in the epithelium may permit the entry of infection—and this may cause keratomalacia. Beaver (1961), in experiments performed in the germ-free rat, found that their corneae had a thin superficial layer of keratinized cells, but there was neither inflammation nor vascularization.

A survey of thirty normal Bantu children has shown that the majority have a resident flora of potential pathogens. The malnourished infant has a diminished cellular and humoral defence mechanism against infection. Thus, it is postulated that the basic lesion of xerosis of the epithelial membrane of the cornea and conjunctiva is the result of generalized malnutrition involving principally protein and vitamin A. The diminished defence reaction of the body, in association with an avascular structure, such as the cornea, predisposes to infection, which if uncontrolled may erode the cornea and cause a localized perforation, or may spread diffusely.

Of the cases swabbed, all except four with superficial ulceration and one with moderate ulceration gave positive results. While this series is too small for definite conclusions to be drawn, it does serve to emphasize the role of infection. Therapeutically, antibiotic administration is considered to be of great importance. Even in severe lesions, the eye may appear quiet, possibly because of a poor humoral defence mechanism.

#### Case Histories of Special Interest

**Case 89, a baby aged 18 months**, was admitted on February 8, 1963, with severe malnutrition and herpetic stomatitis.

Examination revealed a normal right eye and xerosis corneae with superficial ulceration in the left. On February 16, clearing of the lesion was observed. On February 21, the left eye presented the appearance of keratomalacia. A central ulcer was present and around this was an area of necrotic greyish cornea, surrounded by a small limbal region of normal-looking cornea. The ulcer eventually perforated and the resultant staphyloma was observed for over a year and eventually became a classical nipple-teat staphyloma. A superimposed herpetic keratitis could account for the sudden extension of the disease and the development of keratomalacia. The completely normal appearance of the right eye at all stages and the presence of herpetic stomatitis may favour this explanation.

**Case 90, a baby aged 9 months**, was seen on March 12, 1963, and on admission was considered to be normal, but an urgent request was received to see the child again on March 26, 1963.

The right cornea was seen to be disorganized and necrotic. It was greyish-yellow in colour. A small knuckle of iris had presented through a perforation, and a hypopyon was present. *Staph. albus* was cultured. On April 1, 1963, the child died from (?) staphylococcal septicaemia. No *post mortem* examination was made. The possibility exists that a focus of infection set up by the septicaemia caused this severe lesion, which was aggravated by severe malnutrition.

#### Relationship of Xerophthalmia to Discrete Colliquative Keratopathy

Blumenthal (1950, 1954) described a syndrome of malnutritional keratoconjunctivitis, which McLaren (1960) subsequently named "discrete colliquative keratopathy" (DCK) because of the characteristic appearance of a clean iris prolapse.

In our opinion there are no grounds for the delineation of a separate syndrome of

DCK. The so-called clean iris prolapse has been observed in a number of cases as have examples of double prolapse. These cases may be considered to be examples of a localized keratomalacia (Fig. 4).

A number of points in Blumenthal's description may be disputed:

- (i) He suggests vitamin B as being the cause of the lesions, yet from his description of a child who is podgy and also a mewling, miserable child, with skin and hair losing their normal lustre, a classical description of protein malnutrition emerges. The reason why so many of his patients may have appeared normal is that they were first observed after treatment in the out-patients department and not on admission to the paediatric wards, *i.e.* they may well have recovered from their malnutrition when Blumenthal first saw them. Certainly, the statement that none of his patients had the stigmata of kwashiorkor (Blumenthal, 1961) is not compatible with his earlier descriptions.
- (ii) The description of a nipple-teat staphyloma is not at all specific to this syndrome. We have observed it in our cases of keratomalacia followed up in the out-patients department.
- (iii) Again, in his second paper (Blumenthal, 1954), he stated that the patients were protein-deficient, but refused to accept that the protein deficiency might be the basic pathology, and that any lack of vitamin B was incidental thereto.
- (iv) The thesis that a stromal lesion is the causative lesion is based on one histological section, in which the iris prolapse is seen to be covered by a layer of epithelium. However, healing of an iris prolapse occurs by means of epithelialization of its surface (Duke-Elder, 1965). To state that the lesion is stromal is unjustifiable, as there is no indication that the original lesion did not involve the epithelium, especially as Bowman's membrane was absent in the section.

A study of the Table of the "two totally different conditions", xerophthalmia and DCK, quoted by McLaren (1963g), will show that there is basically no difference between them. The iris prolapse observed in DCK was often seen in this series of xerophthalmia associated with protein malnutrition. In keratomalacia lack of inflammatory response to the condition is often noted and there is little conjunctival injection; xerosis conjunctivae was absent in most of our cases, especially where the corneal lesions were more severe and more rapid in onset. Bitot's spots are not causally associated with xerophthalmia. The end-result is merely dependent on the rate of healing, the control of secondary infection, and the treatment of the associated disease. Thus, a leucoma or staphyloma may result.

#### Effect of Protein Malnutrition on the Eye

The disease is more likely to be due to a multiple deficiency syndrome than to a single nutritional deficiency (Yap-Kie-Tiong, 1957; Bagchi, Halder, and Chowdhury, 1959; Oomen, 1961b).

A low vitamin A level may be a manifestation of protein deficiency alone (Bagchi and others, 1959; Scrimshaw, 1958), although McLaren (1958a) stated that there was no real evidence that protein deficiency alone caused the eye lesions. In the treatment of children with kwashiorkor and low vitamin A levels, a high protein diet without vitamin A supplement results in significantly raised vitamin A levels (Gopalan and others, 1960).

The ocular symptoms are part of a general disease (Bloch, 1924), which has been attributed to vitamin A deficiency (McLaren, 1963e; Oomen, 1961c), but has the exact features of protein malnutrition; it is thus more likely that the xerophthalmia is one of the signs of malnutrition.

In a sub-economic society a child is more likely to become deficient of protein and to retain an adequate intake of carotenoids because of the cheaper available food-stuffs containing carotenoids, than to become deficient of vitamin A alone. In the human, vitamin A depletion without protein malnutrition rarely causes corneal lesions. Most reports point to a combined nutritional deficiency of protein and vitamin A.

Experimentally, protein deficiency may also produce keratinization (McLaren, 1963c) and delay corneal wound healing (McLaren, 1960). This suggests that protein deficiency is important in the production of the lesion, either by creating a relative deficiency of vitamin A, or in its own right in association with vitamin A deficiency.

### Serum Levels of Vitamin A and Carotene

The mean of 55.3 I.U. vitamin A with a large variation in the average Bantu child is similar to levels found elsewhere in patients of similar economic status (Oomen, 1958c; Gopalan and others, 1960); but is far below that of the normal average for Europeans (Kagan, 1962; Leitner, Moore, and Sharman, 1961; Szymanski and Longwell, 1951; du Plessis, 1966—personal communication). However, no ocular disability results from this level.

Caster and Mickelsen (1955) and Rodger and others (1964) emphasized that a large variation existed and that vitamin A was characteristic of the individual rather than a reflection of vitamin A intake. This should be kept in mind when assessing vitamin A levels, which may be low without the presence of xerophthalmia with or without associated protein malnutrition.

A similar variation in vitamin A levels is found in patients with kwashiorkor without eye lesions, but there is no significant difference between the vitamin A levels in the normal group and the group with kwashiorkor. The average of 51.3 I.U. with a large range is similar to that quoted by Gopalan and others (1960).

In the group of patients with eye lesions, the average value of 43 I.U. is not significantly different from the control group. However, when the various sub-groups are compared, it is noted that the vitamin A level drops precipitously in cases with severe eye lesions. Yap-Kie-Tiong (1956) quoted similar levels in patients with keratomalacia; although he did not comment on their protein state, the serum protein levels quoted show that he was dealing with severely malnourished children. Oomen (1961a) also found low vitamin A levels; he did not discuss these in relation to protein malnutrition, but the serum protein levels quoted indicate a severe state of protein malnutrition.

The average carotene level of normal Bantu children was much lower than the European average (Sharman, 1963). There is a significant difference between the carotene levels of normal Bantu children and those with kwashiorkor and kwashiorkor with eye lesions ( $P = <0.001$ ). The carotene levels would thus appear to be a better indicator of the nutritional state than vitamin A. The level of 15  $\mu$ gms. in the most severely affected groups, which is higher than in the less severely affected groups, is difficult to understand, but might represent decreased ability to convert carotene to vitamin A.

Carotene intake may be adequate but conversion to vitamin A may be impaired because of the protein deficiency (McLaren, 1958b). The Bantu child absorbs most of his vitamin A in the form of carotene. Thus the low carotene levels may be due to a low dietary intake, but it appears that the carotene that is absorbed is converted to some extent to vitamin A except where protein deficiency is severe. In the experimental rat, Berger, Rechcigl, Loosli, and Williams (1962) showed that the amount and quality of protein in the diet affect conversion of carotene to vitamin A.

Clinically, it is obvious that the majority of children with xerophthalmia do have protein malnutrition, *i.e.* they have a low protein intake and develop eye lesions.

There is considerable evidence that a low protein diet can cause a low serum and liver vitamin A level (Moore, 1960a; Friend, Heard, Platt, Stewart, and Turner, 1961; Vakil, Roels, and Trout, 1964). Because of the protein deficiency, depletion of vitamin A need not be complete before signs of deficiency develop (Moore, 1960b). This could explain why affected patients may have a vitamin A level which is lower than normal but not very low.

### Histology

The changes are similar to those described in human xerophthalmia and found experimentally in the vitamin A-deficient rat (McLaren, 1963b). Typically, a hyperplastic keratinized epithelium is described (McLaren, 1962). In the three corneae examined, loss of epithelium was constant, corresponding to the clinical lesion. Figs 9 and 10 (from the same case) show keratinization at the limbus and loss of epithelium from the area of the corneal ulcer.

It was postulated that infection had caused the breakdown of the previously keratinized corneal epithelium, resulting in an ulcer. Should this progress, breakdown of the corneal stroma and an inflammatory cell infiltrate will result (Fig. 11).

The clinical evidence that a hyperplastic keratinized epithelium is specific to vitamin A deficiency is not convincing. Sweet and K'ang (1935) emphasized that their patients *always* had multiple deficiencies; most of their patients had protein malnutrition. They could not decide which changes were due to vitamin A deficiency and which to other factors. They only assumed them to be due to vitamin A deficiency because the lesions of xerophthalmia were present. The patients of Blackfan and Wolbach (1933), who were suffering from hypovitaminosis A and had clinically normal conjunctivae and corneae, showed no histological changes. The histological lesions considered by Blackfan and Wolbach to be specific to hypovitaminosis A were liver atrophy, atrophy of fat and muscle, anaemia, lymphoid hypoplasia, cessation of growth of bone, and atrophy of epithelia, but these have more recently been considered to be specific to kwashiorkor (Trowell, Davies, and Dean, 1954b). In fact, most of the cases described by Blackfan and Wolbach (1933) were cases of protein malnutrition. Trowell and others (1954b) did not mention that keratinization of the epithelium occurred in kwashiorkor; experimentally, protein depletion may cause keratinization (McLaren, 1963c). Wolbach and Howe (1925) have shown that keratinization is a repair process of the basal cells, stimulated by atrophy of the epithelium.

It is possible that keratinization of the conjunctiva and cornea occurs more readily



in an epithelium rendered atrophic by protein malnutrition. Clinically, this presents as xerosis corneae without ulceration. The keratinized epithelium, because of exposure, avascularity, and possibly other factors, is more susceptible to infection, and should infection occur it progresses from mild to severe corneal ulceration, ultimately leading to keratomalacia.

### Summary

- (1) 1,116 children with malnutrition were surveyed.
- (2) Xerophthalmia was found to occur fairly frequently in the Republic of South Africa.
- (3) There was an intimate association between protein malnutrition and xerophthalmia. Both protein malnutrition and hypovitaminosis A must co-exist for the development of the eye lesions. The hypovitaminosis A may be the direct result of the protein deficiency, or may be a primary dietary deficiency.
- (4) The lesions in many of the patients were the same as those in a syndrome described as "malnutritional keratoconjunctivitis" or "discrete colliquative keratopathy". It is considered that this syndrome is part of the malnutrition-xerophthalmia syndrome.
- (5) Infection was considered to be important in the pathogenesis of the more severe lesions.
- (6) Serum carotene levels were a better indicator of the vitamin A status than isolated serum vitamin A levels.
- (7) Xerophthalmia is a multifactorial deficiency syndrome, closely associated with infection. Treatment must be based on this approach if success is to be obtained. Once keratomalacia has occurred, however, the process is irreversible.

We wish to thank The Superintendent, Baragwanath Hospital, for permission to publish this paper, Dr. S. Wayburne, Head of the Department of Paediatrics, Baragwanath Hospital, for his encouragement, and his staff for referring cases. We also wish to thank the Director of the South African Institute for Medical Research for facilities provided, Dr. R. Cassel, of the South African Institute for Medical Research, Baragwanath Hospital, for the bacteriological studies, and Mr. M. Ulrich, of the Department of Photography, the South African Institute for Medical Research, for the photographs. We are grateful to Dr. J. F. C. Kaufmann, neuropathologist, of the South African Institute for Medical Research, for reporting on the histological sections. Without the help of Professor M. H. Luntz, the preparation of this paper would not have been possible.

### REFERENCES

- BAGCHI, K., HALDER, K., and CHOWDHURY, S. R. (1959). *J. Indian med. Ass.*, **33**, 401.
- BEAVER, D. L. (1961). *Amer. J. Path.*, **38**, 335.
- BERGER, S., RECHCIGL, M., JR., LOOSLI, J. K., and WILLIAMS, H. H. (1962). *J. Nutr.*, **77**, 174.
- BLACKFAN, K. D., and WOLBACH, S. B. (1933). *J. Pediat.*, **3**, 679.
- BLOCH, C. E. (1924). *Amer. J. Dis. Child.*, **27**, 139.
- BLUMENTHAL, C. J. (1950). *S. Afr. med. J.*, **24**, 191.
- (1954). *Ibid.*, **28**, 967.
- (1961). *Brit. med. J.*, **1**, 822.
- CASTER, W. O., and MICKELSEN, O. (1955). *Amer. J. clin. Nutr.*, **3**, 409.
- CHANDRA, H., VENKATACHALAM, P. S., BELAVADI, B., REDDY, V., and GOPALAN, C. (1960). *Indian J. Child Hlth*, **9**, 589.
- DUKE-ELDER, S. (1965). "System of Ophthalmology", vol. 8, part 2, p. 635. Kimpton, London.
- DU PLESSIS, J. P. (1966). Personal communication.
- FRIEND, C. J., HEARD, C. R. C., PLATT, B. S., STEWART, R. J. C., and TURNER, M. R. (1961). *Brit. J. Nutr.*, **15**, 231.
- GOPALAN, C., VENKATACHALAM, P. S., and BHAVANI, B. (1960). *Amer. J. clin. Nutr.*, **8**, 833.

- KAGAN, B. M. (1962). In "Clinical Nutrition", 2nd ed., by N. Jolliffe, p. 475. Harper, New York.
- KARK, S. L. (1943). *S. Afr. J. med. Sci.*, **8**, 106.
- KLENERMAN, P. (1950). *S. Afr. med. J.*, **24**, 891.
- KIMBLE, M. S. (1939). *J. Lab. clin. med.*, **24**, 1055.
- LEITNER, Z. A., MOORE, T., and SHARMAN, I. M. (1960). *Brit. J. Nutr.*, **14**, 157.
- McLAREN, D. S. (1958a). *Bull. Wld Hlth Org.*, **19**, 303.
- (1958b). *Fed. Proc.*, **17**, Suppl. 2, p. 136.
- (1959). *Brit. J. Ophthal.*, **43**, 234.
- (1960). *Wld Rev. Nutr. Diet.*, **2**, 25.
- (1961). *Brit. med. J.*, **1**, 424.
- (1962). *Amer. J. clin. Nutr.*, **11**, 603.
- (1963a). "Malnutrition and the Eye", p. 33. Academic Press, New York.
- (1963b). *Idem*, p. 41.
- (1963c). *Idem*, p. 98.
- (1963d). *Idem*, p. 208.
- (1963e). *Idem*, p. 209.
- (1963f). *Idem*, p. 212.
- (1963g). *Idem*, p. 300.
- (1963h). *Idem*, p. 334.
- (1963i). *Brit. med. J.*, **2**, 926.
- Moore, T. (1957). "Vitamin A", p. 425. Elsevier, Amsterdam.
- (1960a). *Vitam. and Horm.*, **18**, 431.
- (1960b). *Vitam. and Horm.*, **18**, 432.
- OOMEN, H. A. P. C. (1958a). *Fed. Proc.*, **17**, Suppl. 2, p. 115.
- (1958b). *Ibid.*, p. 116.
- (1958c). *Ibid.*, p. 119.
- (1961a). *Int. Rev. trop. Med.*, **1**, 174.
- (1961b). *Ibid.*, p. 170.
- (1961c). *Ibid.*, p. 167.
- , McLAREN, D. S., and ESCAPINI, H. (1964a). "A Global Survey on Xerophthalmia". De Erven F. Bohn, N. V., Haarlem.
- , ———, ——— (1964b). *Idem*, p. 7.
- RODGER, F. C., SAIDUZZAFAR, H., GROVER, A. D., and FAZAL, A. (1964). *Acta ophthal. (Kbh.)*, **42**, 1.
- SANDOZAI, M. K., HAQUANI, A. H., RAJESHVAR, V., and KAUR, J. (1963). *Brit. med. J.*, **2**, 93.
- SCRAGG, J., and RUBIDGE, C. (1960). *Ibid.*, **2**, 1759.
- SCRIMSHAW, N. S. (1958). *Fed. Proc.*, **17**, Suppl. 2, p. 107.
- SHARMAN, I. M. (1963). *Proc. Nutr. Soc.*, **22**, xviii.
- SWEET, L. K., and K'ANG, H. J. (1935). *Amer. J. Dis. Child.*, **50**, 699.
- SYZMANSKI, B. B., and LONGWELL, B. B. (1951). *J. Nutr.*, **43**, 431.
- TROWELL, H. C., DAVIES, J. N. P., and DEAN, R. F. A. (1954a). "Kwashiorakor", p. 49. Arnold, London.
- , ———, ——— (1954b). *Idem*, p. 122.
- VAKIL, U. K., ROELS, O. A., and TROUT, M. (1964). *Brit. J. Nutr.*, **18**, 217.
- WOLBACH, S. B., and HOWE, P. R. (1925). *J. exp. Med.*, **42**, 753.
- YAP-KIE-TIONG (1956). *Brit. J. Ophthal.*, **40**, 502.
- (1957). *Brit. J. Nutr.*, **11**, 158.
- YUDKIN, A. M., and LAMBERT, R. A. (1923). *J. exp. med.*, **38**, 17.