

OCULAR MANIFESTATIONS OF VITAMIN A DEFICIENCY*†

BY

G. VENKATASWAMY

Department of Ophthalmology, Madurai Medical College, Madurai, India

NUTRITIONAL deficiencies are a frequent cause of serious eye disease in India. Oomen (1961) reported a mortality of nearly 30 per cent. in young children with keratomalacia and an even higher proportion in those with protein malnutrition; about 25 per cent. of the survivors became totally blind, and about 60 per cent. were left with reduced vision in one or both eyes. Deficiency diseases revealed by dietary surveys have included xerophthalmia, Bitot's spots, angular stomatitis, and phrynoderma. Gilroy (1951) observed xerophthalmia in 250 out of 4,191 children from 44 estates in Assam. Sundararajan (1963) found signs of vitamin A deficiency in 35 to 45 per cent. of schoolchildren in Calcutta. Chandra, Venkatachalam, Belavadi, Reddy, and Gopalan (1960) reported that lack of protein and vitamin A was the most frequent cause of nutritional deficiency disorders in India; out of 14,563 children examined in a 5-year period, 2,245 showed malnutrition, 551 vitamin A deficiency, and 157 keratomalacia. Rao, Swaminathan, Swarup, and Patwardhan (1959) observed two to five cases of vitamin A deficiency for every case of kwashiorkor. A world-wide survey of xerophthalmia carried out in nearly fifty countries (including countries in Asia) by WHO in 1962–1963 revealed that this was often the most important cause of blindness in young children. Scrimshaw (1959), McLaren (1963), and UNICEF (1963) concluded that vitamin A deficiency was one of the main nutritional problems in tropical and subtropical areas.

Table I (opposite) shows the cases of eye disease due to malnutrition in patients attending the Ophthalmic Department of Madurai Medical College, Madurai in a 3-year period.

The incidence of vitamin A deficiency was studied in the ophthalmic department of the Government Erskine Hospital, Madurai, during a 3-week period in December, 1960. Table II (opposite) gives the results by age. Of 108 cases, 61 were aged between 1 and 4 years. The fact that children below 5 years of age were most often affected confirms the conclusions of Chandra and others (1960).

Dietary History

Supplementary feeding for children, which was started at about the age of 6 months, consisted of rice and its preparations. Many of these patients never had milk and dairy

* Received for publication April 19, 1966.

† Address for reprints: as above.

TABLE I
INCIDENCE OF EYE DISEASES
DUE TO MALNUTRITION, 1961-1963

Year	Total Cases	Number suffering from Malnutritional Eye Diseases
1961	39,963	1,801
1962	41,040	2,904
1963	44,407	2,938

TABLE II
INCIDENCE OF VITAMIN A DEFICIENCY
BY AGE IN DECEMBER, 1960

Age (yrs)	No. of Cases
Below 1	3
-2	16
-3	28
-4	17
-5	7
-6	7
-7	4
-8	1
-9	3
-10	-
11-14	9
15 and over	13
Total	108

produce, fresh greens, vegetables, or fruit, and were given meat, eggs, and fish only rarely. Similar observations have been made by Mitra (1953), Rao (1954), and Pandit (1964).

Examination

Skin.—Table III gives the results of a skin examination in 92 of the cases, all of whom were affected in one way or another. The mothers of the thirteen cases of angular stomatitis were examined and ten had angular stomatitis also.

General.—Table IV shows that anaemia was seen in ten cases, tuberculosis of the lungs in four, hepatomegaly in eleven, enlargement of the spleen in four, and cirrhosis of the liver in four.

TABLE III
RESULTS OF SKIN EXAMINATION IN 92 CASES

Skin Pathology	Number of Cases Affected
Hypopigmentation of hair	44
Toxico-dermia	32
Keratosis follicularis	27
Angular stomatitis	13*
Total Signs of Skin Involvement	116

* Ten mothers of these patients were also affected

TABLE IV
GENERAL CONDITION

Pathological Condition		Number of Cases Affected
State of Nutrition	Poor	24
	Fair	84
Glossitis		4
Anaemia		10
Tuberculosis of lungs		4
Hepatomegaly		11
Splenic enlargement		4
Cirrhosis of the liver		4
Total Lesions Observed		149

Results

Kwashiorkor

Eleven of the 108 patients showed typical features of kwashiorkor; of these seven had keratomalacia, and two of the seven had pulmonary tuberculosis. The other four patients with kwashiorkor had only conjunctival changes like Bitot's spots and wrinkling.

Ophthalmological Signs and Symptoms (Table V)

The most common ophthalmological complaints were night blindness (71), whitish spots in the eye (20), and photophobia (13). The most common general complaints were infestation by worms (75), diarrhoea (53), fever (21), and cough (12).

Night Blindness.—These children would sit quietly in the corner of the house from dusk until the next morning. Many showed signs of early xerosis of the conjunctiva or Bitot's spots. In some, the conjunctiva and cornea were clear but there was angular stomatitis. In the rural areas where night blindness is a familiar problem, they believe the cause to be lack of meat, so the traditional cure is a diet of meat and bone, and amaranthus leaves. Cattle also suffer from night blindness, and may go astray after dusk, but their night vision improves with the appearance of green grass after the monsoon.

TABLE V
OPHTHALMOLOGICAL AND SYSTEMIC DISORDERS

Symptom	No. of Cases
Night blindness	71
Whitish spots in eyes	20
Photophobia	13
Lacrimation	6
Inability to open the lids	5
Haziness of vision	4
Irritation in eyes	3
Matting of eyelashes	3
Diarrhoea	53
Dysentery	7
Fever	21
Cough	12
Oedema of limbs	8
Colic (in abdomen)	1
Round worms and thread worms	75

TABLE VI
CONJUNCTIVAL CHANGES

Changes	No. of Cases Affected
Pigmentation	77
Wrinkling	70
Xerosis	22
Bitot's spots	52
Symblepharon	1

Conjunctival Changes (Table VI)

Pigmentation (77 cases).—Minute dots are seen in the bulbar conjunctiva in the inter-palpebral area (Fig. 1, p. 857). In chronic cases the whole of the bulbar conjunctiva was pigmented, and appeared as though it had been smoked. The

pigmentation started in the lower fornix as a black line and spread towards the cornea and lid margin (Fig. 2, p. 857).

In severe cases, the pigmentation occurred all over the mucous membranes and also on the skin. The light-coloured skin appeared much darker, and the palms and soles showed black pigmentation as in Addison's disease.

Bitot's Spots (52 cases).—These were usually visible to the naked eye but in some cases were very small and could be seen only with a loupe or slit lamp. In some cases they occurred together with pigmentation (Fig. 3, p. 857).

There was a frothy lather on the surface which could easily be wiped off, only to re-appear the next day. Under this froth, the conjunctiva was thick and rough. In chronic cases, mainly in adults, the Bitot's spots appeared like fleshy deeply-pigmented growths and extended over the cornea from 1–2 mm. (Fig. 4, p. 857).

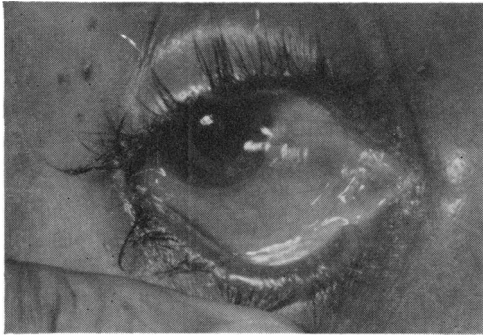


FIG. 1.—Conjunctival pigmentation.

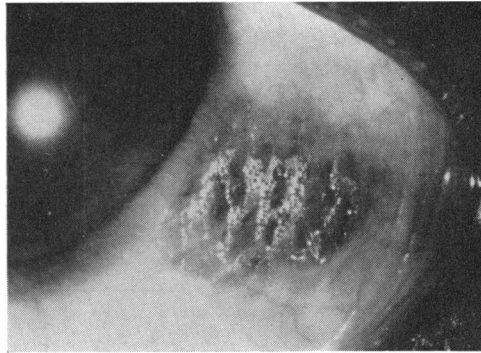


FIG. 2.—Pigmentation of lower fornix.

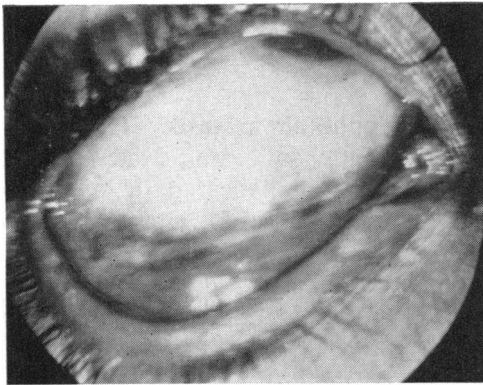


FIG. 3.—Bitot's spots with pigmentation.

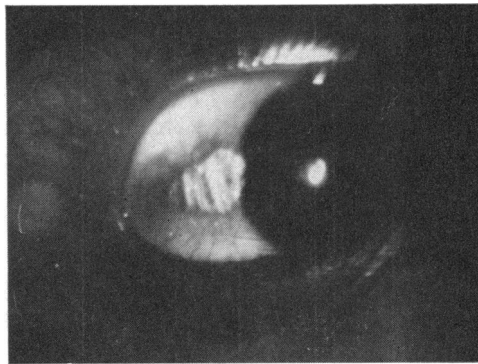


FIG. 4.—Bitot's spots encroaching on cornea.

Some patients with Bitot's spots did not have night blindness but showed other signs of deficiency like follicular keratosis. When their poor diet was improved the Bitot's spots usually disappeared, but in some long-established cases no treatment was of any avail.

Xerosis (22 cases).—This varied in degree and was sometimes associated with corneal xerosis or keratomalacia.

Wrinkling (70 cases).—This can be seen if the patient is asked to look to one side, when the bulbar conjunctiva goes into folds.

Fundus Changes

All cases of night blindness were carefully examined for fundus changes. The macular area showed pallor and stippling and in extreme cases there was atrophy of the optic nerve head.

TABLE VII
CORNEAL CHANGES

Changes		No. of Cases Affected
Xerosis		21
Keratomalacia	Without ulceration	
	(a) Moderate	7
	(b) Severe	8
	With ulceration	
(a) Both eyes	3	
(b) Right eye	1	
(c) Left eye	4	
Ulcer with perforation		1
Prolapse of Iris		1
Leucoma		4

Corneal Changes (Table VII)

These included xerosis (21), keratomalacia (15), and keratomalacia with ulceration and other ulcers (14). In many cases these conditions were associated with conjunctival changes. It is uncertain whether these symptoms represent different conditions or different degrees of severity of the same condition.

Treatment

Diet.—These cases were treated as in-patients in the ophthalmic ward. They were given 10 to 30 oz. milk, one or two eggs, plenty of butter-milk, and 2 oz. cooked amaranth leaves. The older patients were also given 4 oz. meat daily. It was calculated that they were given a daily average of 4,000–6,000 I.U. vitamin A and 40 to 70 g. protein.

In about 8 to 10 days the night blindness improved and in 15 days it was completely cured; the xerosis and Bitot's spots cleared gradually, and the general condition also improved.

Vitamin A Injections.—These cases were treated as out-patients. They were given intramuscular injections of vitamin A (Palmitate 10,000 I.U.) on alternate days, and the night vision improved after five to ten injections. There was no improvement in the general condition, however, and the conjunctival pigmentation and Bitot's spots did not clear during the experimental period.

Riboflavin.—These patients had mild angular stomatitis, and a few gave a history of night blindness. They were treated as out-patients, being given 10 mg. riboflavin parenterally. At the end of 10 days they showed marked improvement and the night blindness was cured.

Discussion

Inter-relationship of Vitamins and Proteins

This study shows the importance of adequate good quality protein in treating night-blindness, which is also improved by the use of riboflavin.

Sathe and Dhurandhar (1955) reported cases with conjunctival xerosis and marked angular stomatitis which were given intramuscular 10,000 I.U. vitamin A daily for 10 days. The conjunctival xerosis improved and the angular stomatitis cleared completely. These cases and the group in this study in which night-blindness was cured by riboflavin show the inter-relationship between vitamin A and riboflavin.

Davson (1950) has stated that the retina contains a very high concentration of riboflavin and that its deficiency in man is associated with a form of night blindness.

Kimble and Gordon (1939) and Pollak (1945) have stressed the value of riboflavin in improving dark adaptation. Morton (1944) reviewed the evidence that riboflavin and not vitamin A was the chromophoric group of visual purple.

All the patients in this study had total night blindness from dusk to dawn, and could not see even in full moon-light. Two of the older patients had their right eye bandaged and their scotopic vision was tested in each eye after 24 and 48 hours. The bandaged eye was not better than the other, which suggests that they lacked the pigment responsible for night vision. They were then given daily injections of vitamin A and the right eye was bandaged and tested as before. After 3 days the bandaged eye had better night vision than the other, which shows that minimal visual purple was becoming available in the retina. However, they were still unable to see in full moon-light, which indicates that the pigment responsible for scotopic vision was still present in extremely small amounts.

Summary

108 cases of vitamin A deficiency were examined for ocular symptoms, and a therapeutic trial was carried out with the following results:

(1) Fundus changes such as stippling, lack of redness in the macular area, and atrophy of the optic nerve were observed.

(2) Some other factor besides vitamin A deficiency seemed to be responsible for keratomalacia.

(3) Night blindness was improved by administering protein as well as vitamin A.

(4) Riboflavin cured night blindness.

(5) Vitamin A and riboflavin were found to have a synergistic action.

The author wishes to express his thanks to the professors of dermatology and paediatrics, Madurai Medical College, Madurai, for their help in examining these patients.

REFERENCES

- CHANDRA, H., VENKATACHALAM, P. S., BELAVADI, B., REDDY, V., and GOPALAN, C. (1960). *Indian J. Child Hlth*, **9**, 589.
- DAVSON, H. (1950). "Physiology of the Eye", p. 16. Churchill, London.
- GILROY, A. B. (1951). *Indian J. med. Res.*, **39**, 361.
- KIMBLE, M. S., and GORDON, E. S. (1939). *J. biol. Chem.*, **128**, I ii.
- MCLAREN, D. S. (1963). *Lancet*, **2**, 86.
- MITRA, K. (1953). Indian Council of Medical Research, Special Report Series No. 25, pp. 4-10.
- MORTON, R. A. (1944). *Nature (Lond.)*, **153**, 69.
- OOMEN, H. A. P. C. (1961). *Int. Rev. trop. Med.*, **1**, 131.
- PANDIT, C. G. (1964). "Diet Atlas of India", Indian Council of Medical Research, Special Report Series No. 48, pp. 36-43.
- POLLAK, H. (1945). *Brit. J. Ophthalm.*, **29**, 288.
- RAO, K. S., SWAMINATHAN, M. C., SWARUP, S., and PATWARDHAN, V. N. (1959). *Bull. Wld Hlth Org.*, **20**, 603.
- RAO, M. V. R. (1954). "Report of the Nutrition Survey of the Dang's District", pp. 12-13. Government Central Press.
- SATHE, S. M., and DHURANDHAR, C. B. (1955). *J. All-India ophthal. Soc.*, **3**, 1.
- SCRIMSHAW, N. S. (1959). *J. Amer. dietet. Ass.*, **35**, 441.
- SUNDARARAJAN, A. R. (1963). *Swasth Hind*, **7**, 334.
- UNICEF (1963). "The Hungry Children. Problems of Child Nutrition in the Developing Countries", pp. 1-5. New York.